

Rita REZZANI<sup>1,2,3</sup>, Francesca SULAS<sup>1</sup>, Corrado Federico PUNZI<sup>1</sup>, Daniela PINTO<sup>3,4</sup>, Fabio RINALDI<sup>3,4</sup>, Claudio LONATI<sup>1,2</sup>, Alessandra STACCHIOTTI<sup>5,6</sup>, Francesca ARNABOLDI<sup>5</sup>, Gaia FAVERO<sup>1,3</sup>

<sup>1</sup> Anatomy and Physiopathology Division, Department of Clinical and Experimental Sciences, University of Brescia, 25123 Brescia, Italy.

<sup>2</sup> Italian Society for the Study of Orofacial Pain (Società Italiana Studio Dolore Orofaciale - SISDO), 25123 Brescia, Italy.

<sup>3</sup> Interdepartmental University Center of Research Adaption and Regeneration of Tissues and Organs - ARTO, University of Brescia, 25123 Brescia, Italy.

<sup>4</sup> Human Microbiome Advanced Project Institute, 20129 Milan, Italy.

<sup>5</sup> Department of Biomedical Sciences for Health, University of Milan, Via Mangiagalli 31, 20133 Milan, Italy.

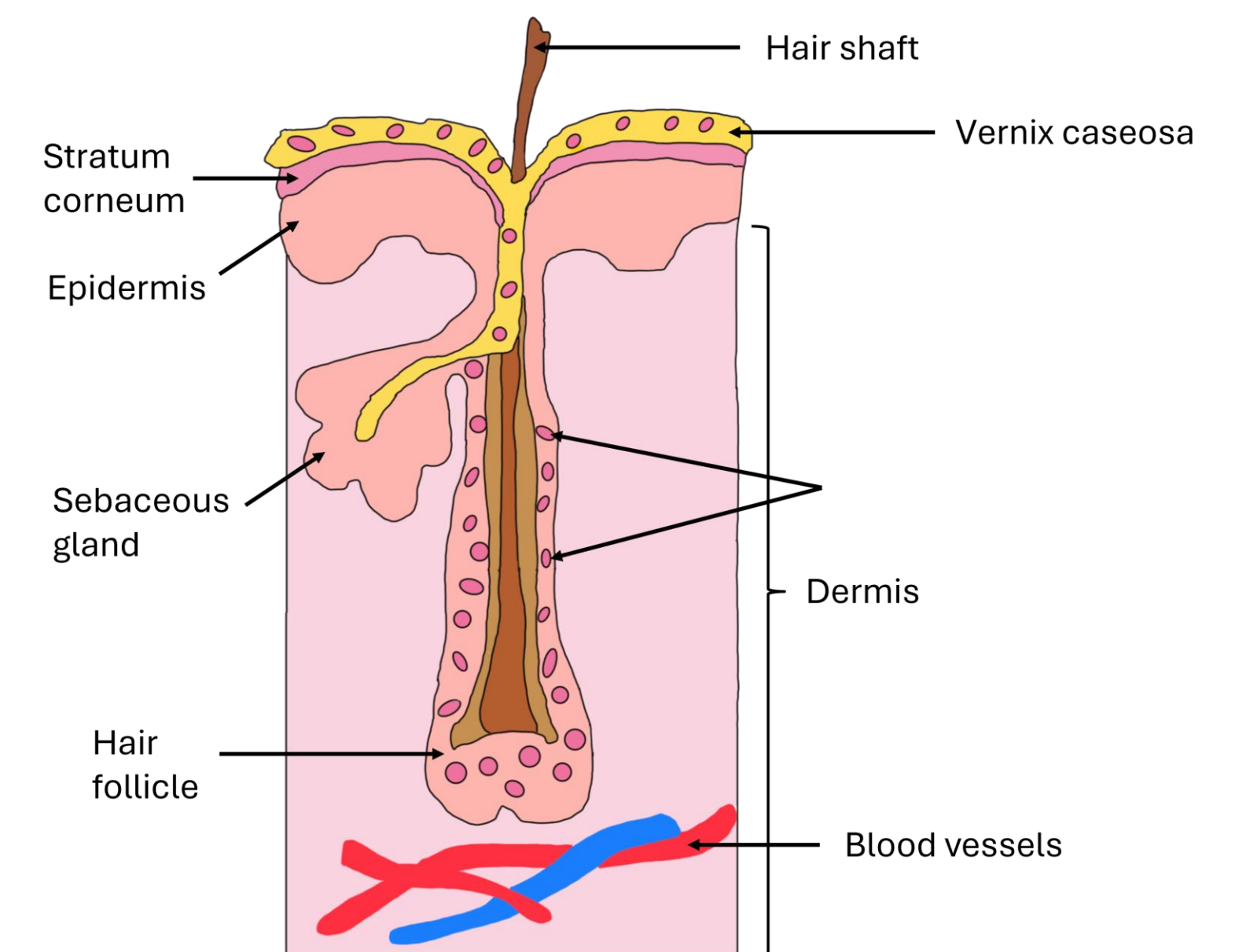
<sup>6</sup> U.O. Laboratorio di Morfologia Umana Applicata, IRCCS Policlinico San Donato, San Donato Milanese, 20097 Milan, Italy.

## BACKGROUND

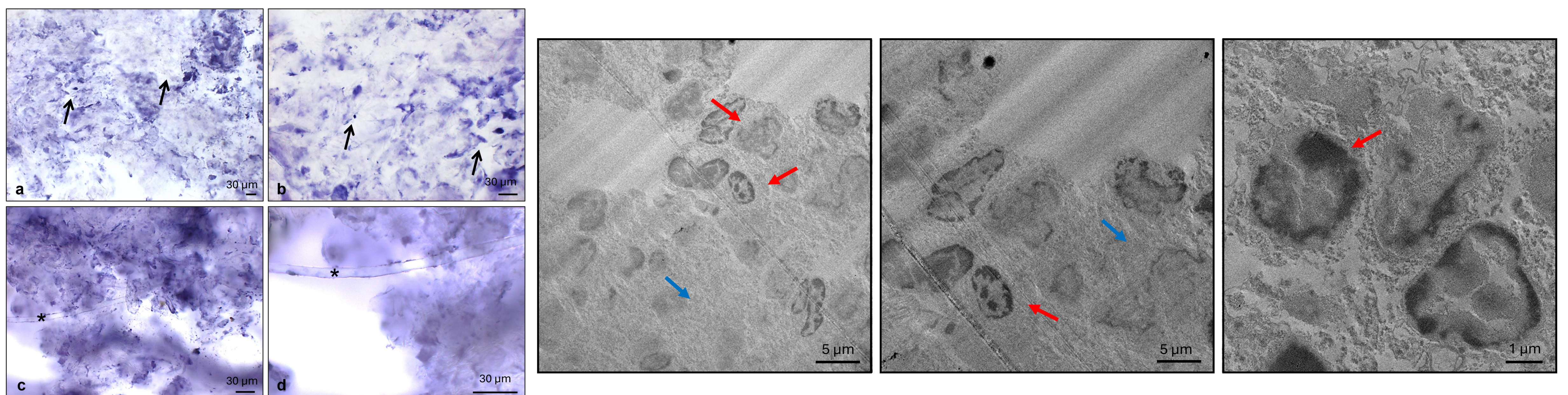
In full-term newborns, the epidermal stratum corneum is still adapting to extrauterine life and appears to be involved in the absorption of skincare products and topical medications. Vernix caseosa (VC) is a physiological white barrier that gradually covers the skin in a cephalocaudal manner during the final trimester of pregnancy. Maternal and placental hormones control VC formation. VC is uniquely human and consists of waxes, sterol esters, squalene, cholesterol, triglycerides, and free sterols, as well as cellular elements. To our knowledge, the cellular elements present in VC have not been fully elucidated. Visscher et al. (2014) suggested that the cells in VC may originate from the hair follicles, which has a recognized local hypothalamic–pituitary–adrenal axis.

## PURPOSE AND METHODS

This study aimed to morphologically characterize the VC, with a primary focus on its formation and the role of the hair infundibulum in this process. VC was gently scraped from the skin of 10 newborn infants and appropriately processed for morphological and ultrastructural analyses.



## RESULTS



Hematoxylin staining of representative smears of VC. Photomicrographs (a) and (b) mainly show the lipid matrix among the cellular components. This material surrounds polygonal-shaped empty spaces (black arrows), which are probably former sites of corneocytes. Photomicrographs (c) and (d) show a newborn's lanugo hair (black asterisk).

The ultrastructural analysis conducted using transmission electron microscopy (TEM) reveals a few cells with ghost nuclei (blue arrows), as well as other cells with kidney-shaped nuclei and thickened chromatin (red arrows). According to Visscher et al. (2014), the cells with ghost nuclei could be corneocytes, while the others may originate from hair follicles.

## CONCLUSIONS

Morphological evaluations revealed the presence of highly hydrated corneocytes embedded in lipids that were larger than those of children's stratum corneum, suggesting they may be swollen with imbibed amniotic fluid. Ultrastructural analysis revealed flattened structures indicative of differentiated corneocytes, devoid of nuclei and intercellular lipids. Furthermore, the ultrastructural analyses indicated that VC may originate from the hair infundibulum.

Although VC is usually removed from the skin surface at birth, it is not a "waste product" of human development.

The present study supports the World Health Organization's recommendations to avoid wiping VC off newborn infants' skin at birth and to delay the first bath for at least six hours.

## ACKNOWLEDGMENTS

The authors would like to express their sincere thanks to Franchini Acciai S.p.A. (Mairano, BS, Italy) for the valuable support in various research projects of the Anatomy and Physiopathology Division (University of Brescia, Italy). They would also like to thank the Unitech No Limits Facility (University of Milan, Italy) for the technical support, as well as for the use of the Talos L 120 transmission electron microscope (FEI).

## REFERENCE

Visscher et al., *Newborn Infant Nurs. Rev.* 2014, 14(4), 142–146.  
Visscher et al., *Adv Wound Care (New Rochelle)*. 2014, 1;3(4):291–303.