

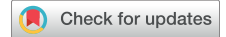Available online at www.sciencedirect.com

ScienceDirect

journal homepage: www.elsevier.com/locate/survophthal

Short reviews

Artificial iris implantation in congenital aniridia: A systematic review



**Davide Romano, MD^a, Dominique Bremond-Gignac, MD^{b,c},
Miriam Barbany, MD^d, Amna Rahman, MS^e, Laura Muring, MD^f,
Francesco Semeraro, MD^a, Claus Cursiefen, MD, PhD^g, Neil Lagali, PhD^h,
Vito Romano, MD^{a,*}**

^aOphthalmology Clinic, Department of Medical and Surgical Specialties, Radiological Sciences, and Public Health, Ophthalmology Clinic, University of Brescia, Brescia, Italy

^bOphthalmology Department, Hôpital Universitaire Necker-Enfants Malades, APHP, Paris, France

^cINSERM, UMRS1138, Team 17, Université Sorbonne Paris Cité, Centre de Recherche des Cordeliers, Paris, France

^dInstitut de Microcirurgia Ocular, Barcelona, Spain

^eSchool of Medicine, University of Liverpool, Liverpool L69 3GE, UK

^fEye Clinic and Genetics and Personalized Medicine Clinic, Tartu University Hospital, Tartu, Estonia

^gDepartment of Ophthalmology, University of Cologne, Faculty of Medicine and University Hospital Cologne, Cologne, Germany

^hDepartment of Biomedical and Clinical Sciences, Linköping University, Linköping, Sweden

ARTICLE INFO

Article history:

Received 30 May 2022

Revised 1 November 2022

Accepted 7 November 2022

Available online 12 November 2022

Keywords:

Aniridia implant

aniridia surgery

aniridia cataract

aniridia timing

iris prosthesis

Morcher. aniridia

ABSTRACT

Congenital aniridia is a rare, panocular disorder with a main phenotypic characteristic of a partial or complete absence of the iris existing alongside other ocular morbidities such as cataract, keratopathy, optic nerve and foveal hypoplasia, and nystagmus. The iris abnormality, however, often leads to symptoms such as photophobia, glare, and decreased visual acuity, as well as cosmetic dissatisfaction. Current management options for the iris deficit include colored iris contact lenses, corneal tattooing, and tinted contact lenses. Symptoms arising from small iris defects can be resolved with surgical management using micro-tying suture techniques such as McCannel or Siepser. Currently, larger iris defects can be treated with artificial iris implants. New prosthetic options range from colored intraocular lenses to flexible custom-made silicone iris implants. With a range of therapeutic options available and given the challenges of multiple comorbidities in aniridia, we evaluate the literature re-

* Corresponding author: Vito Romano, MD, Eye Clinic, Department of Medical and Surgical Specialties, Radiological Sciences, and Public Health, University of Brescia, Piazzale Spedali Civili, 1, Brescia 25125, Italy.

E-mail address: vito.romano@gmail.com (V. Romano).

lating to the use of artificial iris implants in congenital aniridia, with a focus on the different surgical implantation techniques, the clinical outcomes achieved, complications occurred, and risk of bias of the studies included.

© 2022 The Authors. Published by Elsevier Inc.

This is an open access article under the CC BY-NC-ND license

(<http://creativecommons.org/licenses/by-nc-nd/4.0/>)

1. Introduction

Congenital aniridia is a rare ocular disorder, with a global incidence rate of 1:64,000–1:96,000, characterized by the absence of the iris, which can be partial or total, and progressive bilateral vision loss.^{18,40}

Genetically, congenital aniridia is most often caused by a heterozygous mutation in the *PAX6* gene on chromosome 11 (11p13).²¹ One-third of cases arise from sporadic mutations, while the remaining two-thirds are inherited with an autosomal dominant pattern. *PAX6* contributes to the development of the eye and its surrounding extraocular structures resulting in other defective conditions such as, glaucoma in early childhood or adolescence; cataract; aniridia-associated keratopathy; zonular laxity; capsule fragility; corneal changes; and foveal hypoplasia; as well as nystagmus; amblyopia; and ptosis.¹⁸ Because of the involvement of these multiple eye structures, congenital aniridia is considered a pan-ocular disorder.

Other less common mutations include those in the genes *FOXC1*, *PITX2*, *CYP1B1*, *FOXD3*, and *TRIM44* – a mutation in each of these genes can give rise to different phenotypes of partial or total aniridia.⁴⁰ Contiguous deletion of both *PAX6* and *WT1* genes, which are located next to the aniridia genes, results in Wilms tumor as part of WAGR syndrome (Wilms tumor, aniridia, genitourinary anomalies, and intellectual deficit).⁴⁰ Rarely, aniridia can also be linked to Gillespie syndrome causing cerebellar ataxia and oligophrenia.⁴⁰

The absence of iris tissue not only has cosmetic implications, but also has a direct impact on visual acuity. Indeed, it leads to reduced visual acuity, decreased contrast sensitivity, poor depth of focus, photophobia, and glare.¹⁸ Therefore, clinical management is directed towards restoring the iris function, aiming to improve the visual acuity. This can be achieved by modifying the ocular surface or the intraocular environment. The former approach includes eyelid surgery, tinted contact lenses and tattooing of the cornea, none of which have consistently shown satisfactory results.^{14,18} The intraocular approach consists of pupilloplasty or an artificial iris, the choice being mainly based on the extent and etiology of the iris defect. In cases of small (≤ 2 clock hours sectoral) iris defects, in which the remaining iris tissue is adequate in quantity and quality, it is possible to restore the iris function by suturing the residual iris with McCannell or Siesper techniques or with the intracameral microtying iris suture technique.^{33,43,51} By contrast, in the case of wider iris defects, iris prostheses are commonly used.⁴⁵ Here we summarize all the iris devices described in the literature, their implantation techniques, and their clinical outcomes.

2. Methods

2.1. Literature search

An advanced search on PubMed, Scopus, Cochrane, and Web of Science was performed independently by 2 reviewers. The search included the following terms (Iris) AND (aniridia OR WAGR syndrome OR Wilms tumor OR nephroblastoma OR Gillespie syndrome OR cerebellar ataxia) AND (implant OR prosthesis OR artificial OR device), with no set limitations on searching fields, date or language. Each search term is either a synonym for ‘implant’ or a disease associated with aniridia, allowing for a broad search, and minimizing potential selection bias. All retrieved literature was screened, and the following exclusion criteria were applied non-English language, nonhuman studies, cohort of aniridia patients not receiving iris implantation, non-peer reviewed publications, traumatic aniridia (Table 1).

2.2. Study selection and data extraction

Following removal of duplicates, the articles were title screened to narrow down relevant literature for this review. This screening serves to remove studies that are obviously irrelevant, however, care was taken to prevent removal of useful studies. The second round of screening was based on abstracts, further distinguishing between appropriate and inappropriate literature.

Full texts of remaining studies were then screened for eligibility following the “Patient/problem, Intervention, Comparison, and Outcome” format.⁴¹ Data extraction was conducted by noting the common outcomes, for example best-corrected visual acuity (BCVA), complications and taking note of other outcomes.

Table 1 – Inclusion and exclusion criteria

Inclusion criteria	Exclusion criteria
English language	Non-English language
Human studies	Non-human studies
Aniridia patients receiving iris implantation	Aniridia patients not receiving iris implantation
Surgical techniques discussed	Surgical techniques not discussed
Dated up to 2021	Systematic reviews, books, conferences or other articles wherein no cases were recorded
Case reports	Non-peer reviewed
	Traumatic Aniridia

The literature screen was performed independently by 2 reviewers (D. R. and A. R.) based on the inclusion and exclusion criteria. Disagreements on the eligible literature were resolved by a third reviewer (V. R.).

2.3. Quality appraisal of included studies and assessment of risk of bias

To assess the methodological quality of the studies included and the risk of bias, 2 tools were used, in view of the lack of a unique quality tool for both cohort studies and case series/reports.

The Newcastle-Ottawa Scale (NOS) was used for cohort studies and the Joanna Briggs Institute (JBI) critical appraisal checklist for case series and case reports. The choice of these tools was based on the literature, which suggest that NOS is the most commonly used tool for cohort studies, and JBI is the only tool which can be used for case series and case reports.²³

To assess the risks of bias, the Risk of Bias in Nonrandomised Studies of Interventions (ROBINS-I) assessment tool was used. This tool includes 7 specific bias domains, pre-intervention, and postintervention.⁴⁶ The domains are (1) confounding; (2) selection of participants; (3) classification of intervention; (4) deviation from interventions; (5) missing outcome data; (6) measurement of outcomes; and (7) selection of reported result; overall. Risk of bias was rated as 0—no information; 1—low risk; 2—moderate risk; 3—serious risk; and 4—critical risk.

Two authors (D. R. and A. R.) independently assessed the methodological quality and risk of bias of the included articles. Disagreements were resolved by a third reviewer (V. R.).

3. Results

3.1. Study selection, quality appraisal, and assessment of risks of bias

The search yielded 937 articles, of which 293 duplicates were later removed. The remaining 644 articles were title and abstract screened, which further excluded 551 articles. A full-text screen was then conducted, removing 76 studies and leaving 17 remaining studies 10 retrospective case series and 7 retrospective cohort studies. Of these, congenital aniridia cases were reported in 3 retrospective case series and 2 retrospective cohort studies. Furthermore, one case series had a patient with bilateral congenital aniridia and was included in the review.^{11,29,31,37,38} The PRISMA flowchart in Fig. 1 details the selection process.

Regarding the quality appraisal, the NOS score of the 2 cohort retrospective studies was 5 out of 9 for each study, with overall quality of “Poor,” in view of lack of non-exposed comparison group (score of 0 in comparability domain)⁵² (Table 2), while for the JBI checklists, Menenzo and coworkers had 5 “yes” out of 10, Figueiredo and coworkers, 7 of 10, and Mostafa and coworkers, 4 of 8 (Table 3 and 4).^{11,29,31,37,38}

For the JBI checklists, there are however, no cut-off scores to determine whether a study is low, moderate, or high quality.³²

Results of risk of bias using ROBINS-I tool were as follows; In domain 1, 1 study out of 5 (1/5) was rated as moderate, 1/5 as critical, and 3/5 as serious; in domain 2, 1/5 was rated as low and 4/5 as moderate; in domain 3, 4/5 were rated as low and 1/5 as moderate; in domain 4, 5/5 were rated as low; in domain 5, 5/5 were rated as moderate; in domain 6, 5/5 were rated as moderate; in domain 7, 4/5 were rated as serious and 1/5 as moderate. Only Figueiredo and coworkers¹¹ had an overall moderate risk of bias, while Reinhard and coworkers Menenzo and coworkers, and Qiu and coworkers^{29,36,38} had a serious risk, and Mostafa and coworkers, a critical risk³¹. Only Figueiredo and coworkers¹¹ provided sound evidence for non-randomized studies, but this cannot be considered comparable to well-performed randomized trials. Table 5 details the score in each “dominion of bias” in the tool, while Fig. 2 reports a color-code graph for each domain.

3.2. Literature review

The literature described 3 prosthetic iris devices (PIDs) iris-lens diaphragm (ILD), capsular tension ring-based prosthetic iris device (CTR – based PID) and customized Artificial Iris (AI) (Table 6 and Table 7).

Considering the manufacturers of the PIDs reviewed, all the ILD and CTR-based PID were manufactured by Morcher (Morcher GmbH, Stuttgart, Germany) (Figs. 3–6), while the AI were manufactured by BrightOcular implants (Stellar Devices, New York, USA) (Fig. 7) in cases of the Mostafa and coworkers³¹, while Figueiredo and coworkers¹¹ used the CustomFlex Artificial Iris (HumanOptics AG, Erlangen, Germany) (Fig. 8). Considering the up-to-date market availability, Morcher withdrew aniridia implants at the end of 2020 for marketing reasons; BrightOcular did not receive FDA approval or the CE mark, while the CustomFlex Artificial Iris was sold as custom-made device since 2002 until it received CE mark in 2011 and FDA approval in 2018.

To mention other PIDs reported in literature but not included in this systematic review, due to our exclusion criteria, there are the foldable acrylic ILD with CE mark, no FDA approved, produced by Reper (Reper-NN Ltd., Nizhny Novgorod, Russia)³⁵ and distributed by Ophtec (Ophtec BV, Groningen, Netherlands) in Europe until March, 2022 (currently no longer available in Europe) and ILD, no longer marketed, produced by Ophtec, as the model 311, the Iris Prosthetic System, and the Artisan Iris Reconstruction IOL⁴⁵.

The literature suggests an iris implementation in combination with cataract surgery is likely to improve aniridic patients’ visual acuity and symptoms (glare and/or photophobia), considering that, overall, 90 out of 144 eyes (62.5%) had increased BCVA, and 78 out of 83 patients (94%) reported a reduction in symptoms after implantation. Across all studies, cataract surgery was performed at the time of PID implantation in 140 out of 144 eyes (97%) while 4 out of 144 eyes (3%) were already pseudophakic. Among the 140 eyes who underwent cataract surgery, the presence of cataract was noted in 138 eyes (98.6%) while 2 eyes (1.4%) presented subluxation of the lens. None of the patients were left aphakic (Table 8).

To better estimate the rate of improvement, a mean of all preoperative BCVA should be reported; however, this was reported in only 3 studies (Menezco and coworkers, Mostafa

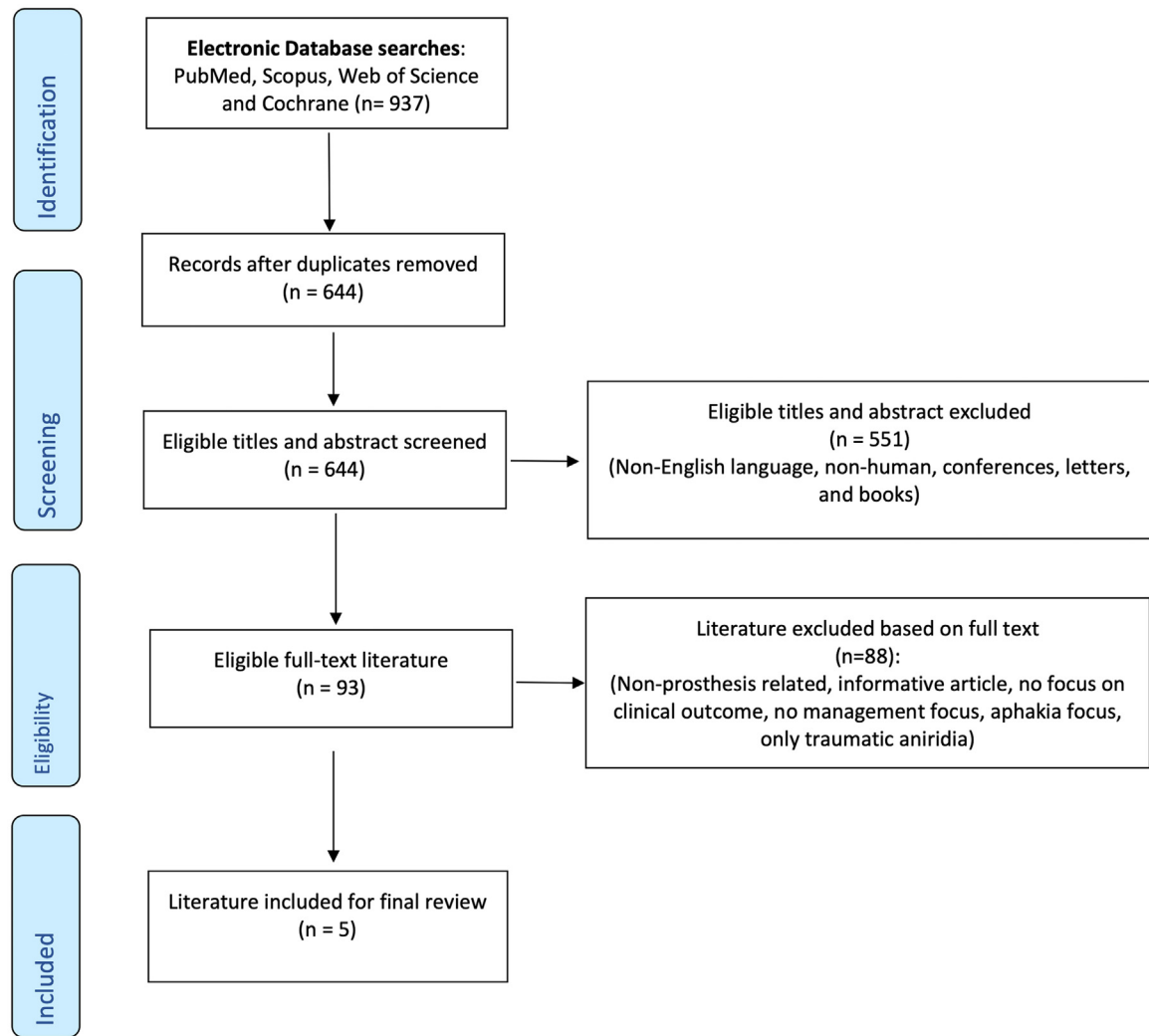


Fig. 1 – PRISMA flowchart for the eligible literature.

Table 2 – Results of NOS quality assessment for cohort studies

	Representativeness of the exposed cohort	Selection of the non-exposed cohort	Ascertainment of exposure	Outcome of interest was not presented at start of study	Comparability of cohorts on the basis of the desing analysis	Assessment of outcomes	Was follow-up long enough for outcome to occur	Adequacy of follow-up cohorts	Total quality score
Reinhard 2000	1	N/A	1	1	N/A	1	0	1	5
Qiu 2016	1	N/A	1	1	N/A	1	0	1	5

N/A: not applicable, in view of lack of non-exposed cohort.

and coworkers, and Qiu and coworkers).^{29,31,37} Furthermore, in Menezzo et al and Mostafa et al, only 2 eyes were evaluated for BCVA, while in the study by Qiu and coworkers, 23 eyes were evaluated. In these 3 studies, the corresponding pre-operative BCVA in logMAR units was respectively 0.70,²⁹ 1.26,³¹ and 1.54,³⁷ while the postimplantation BCVA was 0.50²⁹, 0.5³¹, and 0.983, respectively³⁷. Notably, Qiu and coworker re-

ported that 16 out of 23 eyes had a BCVA better than 1.0 log-MAR after PID implant and cataract surgery.

In a study by Reinhard and coworkers³⁸ (19 eyes), a list of each patients pre- and postoperative BCVA was given, with values ranging from “light perception” “finger counting” “meter vision” to decimal values. Excluding from the evaluation the “meter vision,” which does not have a corresponding value

Table 3 – Results of JBI quality assessment for case series (Menenzo 2005 and Figueiredo 2020)

	1. Were there clear criteria for inclusion in the case series?	2. Was the condition measured in a standard, reliable way for all participants included in the case series?	3. Were valid methods used for identification of the condition for all participants included in the case series?	4. Did the case series have consecutive inclusion of participants?	5. Did the case series have complete inclusion of participants?	6. Was there clear reporting of the demographics of the participants in the study?	7. Was there clear reporting of clinical information of the participants?	8. Were the outcomes or follow-up results of cases clearly reported?	9. Was there clear reporting of the presenting sites'/clinics' demographic information?	10. Was statistical analysis appropriate?
Menenzo 2005	Yes	Yes	Yes	Yes	Yes	No	No	No	No	Not Applicable
Figueiredo 2020	Yes	Yes	Yes	Yes	Yes	No	Yes	No	No	Yes

Table 4 – Results of JBI quality assessment for case report (Mostafa 2018)

	1. Were patient's demographic characteristics clearly described?	2. Was the patient's history clearly described and presented as a timeline?	3. Was the current clinical condition of the patient on presentation clearly described?	4. Were diagnostic tests or methods and the results clearly described?	5. Was the intervention(s) or treatment procedure(s) clearly described?	6. Was the post-intervention clinical condition clearly described?	7. Were adverse events (harms) or unanticipated events identified and described?	8. Does the case report provide takeaway lessons?
Mostafa 2018	Yes	No	No	Yes	Yes	No	Unclear	Yes

Table 5 – Risk of bias in non-randomised studies according to the Risk of Bias in Nonrandomized Studies of Interventions (ROBINS-I) tool.

Auhtor, year (Ref.)	D1	D2	D3	D4	D5	D6	D7	Overall
Reinhard 2000	3	2	1	1	2	2	3	3
Menenzo 2005	3	2	1	1	2	2	3	3
Mostafa 2018	4	1	2	1	2	2	3	4
Qiu 2016	3	2	1	1	2	2	3	3
Figueiredo 2020	2	2	1	1	2	2	2	2

Risk of bias assessment: 0 - No information; 1 - Low; 2 - Moderate; 3 - Serious; 4 - Critical.
D1: bias due to confounding.
D2: bias in selection of participants into the study.
D3: bias in classification of intervention.
D4: bias due to deviation from intended interventions.
D5: bias due to missing data.
D6: bias in measurement of outcomes.
D7: bias in selection of the reported result.

in logMAR, we estimated that the mean BCVA improved from 1.2 logMAR to 0.76 (15 eyes) after cataract surgery and PID implantation.

In the largest study by Figueiredo and coworkers¹¹ improvement in BCVA following cataract surgery and PID implantation was reported as improvement ≥ 2 Snellen lines, which was achieved in 56 out of 96 operated eyes (58.3%).

Overall, excluding the case series of 2 eyes of the same patient who underwent surgery at the age of 13

years³¹, the age at the time of PID implant was around 30 years.

Deterioration of BCVA after PID implantation was observed in 13 out of 144 eyes (9.8%), while in 39 out of 144 eyes (27.1%) the BCVA remained unchanged.

Although visual acuity improvement is reported in the majority of cases after iris implantation and cataract surgery, it should be noted that the degree of improvement was generally limited to 2–3 logMAR lines of vision in most cases, with

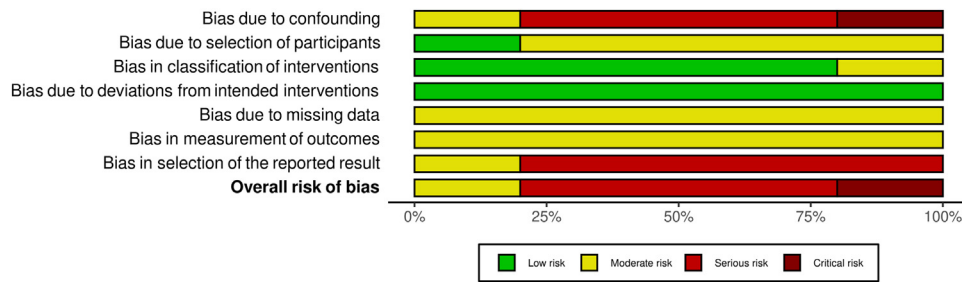


Fig. 2 – Graphical representation of the results of the Table 5 Risk of bias in nonrandomized studies according to the Risk of Bias in Nonrandomized Studies of Interventions (ROBINS-I). In order, from top “Bias due to confounding” to down “Bias in selection of reported results,” are the Domain from 1 to 7 of the Table 5. Low risk of bias green (score 1 on the Table 7); Moderate risk of bias yellow; (score 2 on the Table 5) High risk of bias red (score 3 on the Table 5), Critical risk of Bias dark red (score 4 on the Table 5).

Table 6 – Advantages and disadvantages of each type of iris prosthesis used in reviewed literature

Prosthesis Type	Advantages	Disadvantages
Iris-lens Diaphragm (ILD) (e.g. Morcher 67F, 67G, 67L)	Treats aniridia and aphakia simultaneously	Requires a large corneal incision Placement into anterior segment is difficult
Endocapsular Capsular Tension Ring-based iris prosthesis (CTR-based PID) (e.g. Morcher 50D)	Requires only a small corneal incision Decreased risk of intra-operative and post-operative complications	Brittle and susceptible to fracture Intact capsular bag required for implantation Accurate alignment is difficult
Customised Artificial Iris (e.g. BrightOcular)	Requires only a small corneal incision due to its silicone material and lack of central optics Customisation increases cosmetic satisfaction	Separate intraocular lens required if needed

Table 7 – Indications for which type of prosthetic iris device to choose

Phakic status	Aphakic	Capsular support: Yes > Iris-lens diaphragm in the sulcus without trans-scleral suture fixation Capsular support: No > Iris-lens diaphragm in the sulcus with trans-scleral suture fixation
	Phakic	Cataract extraction with simultaneous implant of ILD or CTR-based PID
	Pseudophakic	Endocapsular CTR-based PID IOL exchange with secondary ILD in the sulcus or in the capsular bag Secondary implant in the sulcus of Artificial Iris
Capsular bag	Intact	CTR-based PID in the bag ILD in the bag
	Damaged	ILD with trans-scleral suture fixation

a best possible acuity of around 0.5 logMAR in a small subset of individuals. This is likely due to other factors such as the status of the cornea, lens, and fovea being the vision-limiting factors in this population.

Considering the type of PID, iris-lens diaphragm prosthesis (ILD) was implanted in 45 eyes (31.2%), artificial iris (AI) in 98 eyes (68.1%), and capsular tension ring-based prosthetic iris device (CTR-based PID) in 1 eye (0.7%).

Focusing on the type of PID and the outcome on BCVA, improvement was reported in 32 out of 45 eyes who had ILD (71.2%) and 58 out of 98 (59.2%) who had AI. In the only case of CTR-based PID the pre-and post- BCVA was not possible to assess. Deterioration of BCVA after implantation was instead reported in 4 out of 45 eyes (8.8 %) with the ILD and 9 out of

98 eyes (9.2%) with the AI (Table 9). Differences in reduction of symptoms were also noted depending on PID, as symptoms reduced in 96% of cases receiving the AI (49/51 patients) versus 90% of cases with the ILD (29/32 patients).

Considering the surgical technique of implantation (trans-scleral suture approach, sulcus implantation or bag implantation), it was not possible to correlate it with BCVA outcomes, as most studies did not report the data at this level of detail. The trans-scleral suture approach, however, was used in 24 out of 144 eyes (16.67%).

All reviewed studies included cases with postoperative complications glaucoma progression in patients with pre-existing glaucoma (58.9%; 23/39 eyes), secondary glaucoma (27.6%; 29/105 eyes) progression of aniridia-associated ker-

Table 8 – Summary of literature for final review

First Author, Date & Country	Study design & Follow-up Period (min – max or ± SD)	Eyes (Patients)	Mean age at surgery (min – max or ± SD)	Type of Prosthesis & Procedure	Site of PID implantation	N° eyes with cataract surgery at time of PID implant	N° eyes which had PID trans-scleral sutured	Summary of results: BCVA (n°eyes) Glare/Photophobia (n°patients)	If BCVA improved, which was the rate of improvement?
Reinhard, 2000, Germany	Retrospective cohort study with a mean follow-up of 46 mo (18-84 mo)	19 (14)	30 y/o (10-59)	ILD (Morcher 67 variable)	Ciliary sulcus	19 (100%)	0 (0%)	BCVA improved: 14 (73.7%) BCVA unchanged: 1(5.3%) BCVA reduced: 4 (21%) Glare/photophobia reduction: 11 (78.6%) Glare/photophobia unchanged: 3 (21.4%)	1.2 logMAR (baseline) 0.76 logMAR (follow-up) (15 of 19 eyes)*
Menezo, 2005, Spain	Retrospective case series with a mean follow-up of 22.5 mo (16 – 44 mo)	4 (3)	22 y/o (16 – 44)	ILD (Morcher 67 G, 3 eyes) and CTR-based PID (Morcher 50D, 1 eye)	Capsular bag	4 (100%)	0 (0%)	BCVA improved: 2 (50%) BCVA not assessed: 2 (50%) Glare/photophobia reduction: 3 (100%)	0.70 logMAR (baseline) 0.50 logMAR (follow-up)
Qiu, 2016, China	Retrospective cohort study with a mean follow-up of 26 mo (±7.76 mo)	23 (15)	27 y/o (± 15.5)	ILD (Morcher 67G)	Ciliary Sulcus	23 (100%)	18 (78%)	BCVA improved: 16 (69.6%) BCVA unchanged: 7 (30.4%) Glare/photophobia reduction: 23 (100%)	1.54 logMAR (baseline) 0.98 logMAR (follow-up) 16/23 eyes had a BCVA better than 1.0 logMAR after PID implant.
Mostafa, 2018, Egypt	Retrospective case report with a follow-up of 12 mo (12 mo)	2 (1)	13 y/o (13)	Artificial Iris (BrightOcular)	Ciliary sulcus	2 (100%)	0 (0%)	BCVA improved: 2 (100%) Glare/photophobia reduction: 1 (100%)	1.26 logMAR (baseline) 0.5 logMAR (follow-up)
Figueiredo, 2020, USA	Retrospective case series with a mean follow-up of 44.36 mo (±26 mo; 6 – 120 mo)	96 (50)	34 y/o (±15)	Artificial Iris (Custom made)	Capsular Bag (90 eyes) Ciliary sulcus (6 eyes)	92 (95.8%)	6 (6.25%)	BCVA improved: 56 (58.3%) BCVA unchanged: 31(32.3%) BCVA reduced: 9 (9.4%) Glare/photophobia reduction: 48 (96%)	No mean BCVA at baseline reported 56/96 eyes had BCVA improvement ≥ 2 Snellen lines after PID implant.

BCVA: Visual Acuity.

CTR: Capsular Tension Ring.

ILD: Iris-lens Diaphragm.

IOL: Intraocular lens. IOP: intraocular pressure (mmHg).

PID: Prosthetic Iris Device

SD: Standard Deviation

Y/O: years old

*In the Reinhard study a pre-PID implant mean BCVA was not reported; instead, individual patient pre-and post-op BCVA was reported, ranging from not measurable values such as “light perception” and “finger counting” to decimal values. We converted values to logMAR, except for “meter vision”.

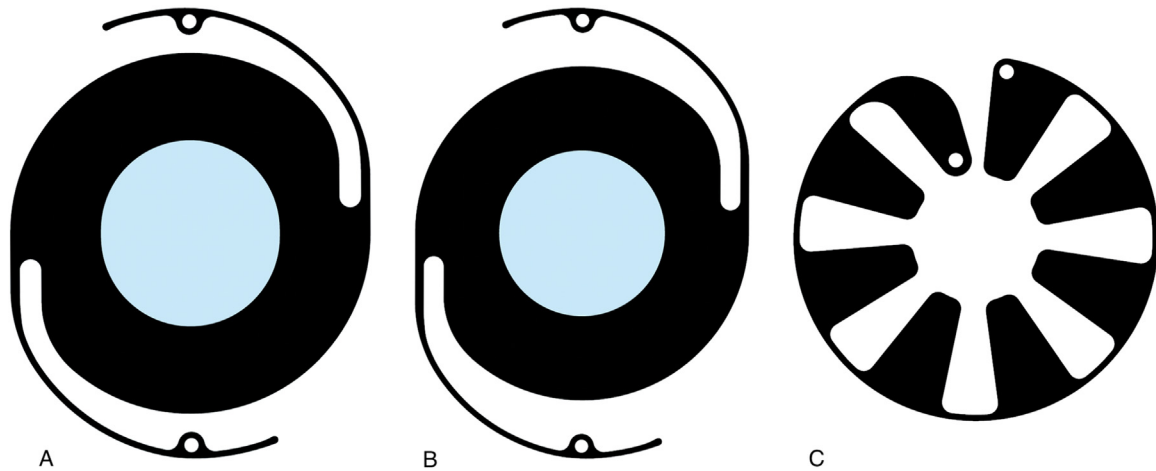


Fig. 3 – Morcher ILD 67F (A) ILD 67G (B) CRT-based PID 50E (C).

Table 9 – Overall and specific PID type improvement of BCVA

Type of PID	N° eyes implanted	BCVA Improved	BCVA unchanged	BCVA reduced	BCVA not assessed
ILD	45 (31.2%)	32 (71.2 %)	8 (17.8%)	4 (8.8%)	1 (2.2%)
AI	98 (68.1%)	58 (59.2%)	31 (61.6%)	9 (9.2%)	0 (0%)
CTR-based PID	1 (0.7%)	/	/	/	1 (100%)

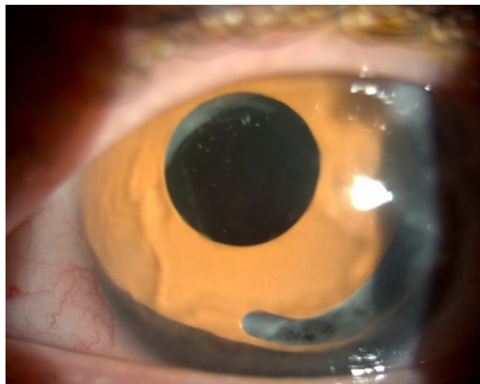


Fig. 4 – Decentered Morcher ILD Implant.

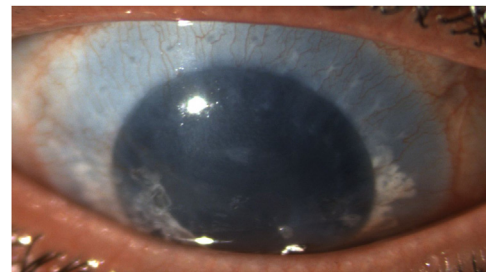


Fig. 5 – Morcher ILD implant.

atopathy (AAK) (27%; 27/100 eyes), prosthesis decentration (10.6%; 14/132 eyes), and endothelial cell loss (9%, 13/144 eyes).

Considering complications possibly related to the PID implant (secondary glaucoma, prosthesis decentration, and endothelial cell loss), slight differences were noted according to the type of PID used. Secondary glaucoma occurred in 28.7% (19/66 eyes) of cases of AI implantation and in 25.6% (10/39 eyes) of cases with the ILD, while prosthesis decentration was noted in 9.2% (9/98 eyes) with the AI and 14.7% (5/34 eyes) with the ILD. Notably, endothelial cell loss was assessed and reported only with the ILD (28.8%, 13/45 eyes) but not with the AI.

Onset of the reported complications was not specifically described, generally occurring sometime during the follow

up, which was highly variable across studies, from 6 to 120 months^{11,29,36,38} to exactly 12 months.³¹

Glaucoma was the most common complication requiring additional surgery (53.8%; 28/52 eyes). Evaluating differences in additional surgeries for glaucoma progression and secondary glaucoma was not possible, however, as most of the papers lacked a subgroup analysis. None of the cases of endothelial cell loss, however, underwent corneal transplantation during follow-up.

4. Discussion

A large proportion of the current literature concerning congenital aniridia focuses on the genetic and phenotypic aspects of the disorder, while studies regarding clinical management of aniridia are less common.²⁰ None of the iris

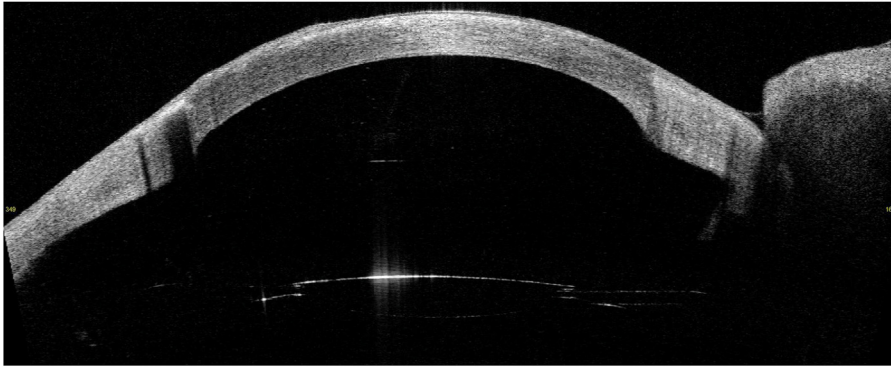


Fig. 6 – Anterior segment OCT of the eye in Fig. 5.

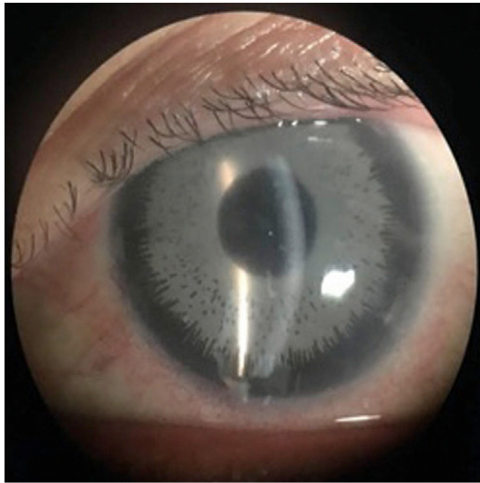


Fig. 7 – BrightOcular Artificial Iris implant.




Fig. 8 – HumanOptics Artificial Iris implant.

implants described in the reviewed literature can mimic the dynamic properties of a human iris; therefore, a fixed pupil size is determined as a compromise for vision in both high and low light intensities.³⁴ All the studies identified were retrospective, with relatively small sample size, and without control group. Even if the low incidence of aniridia makes clinical studies with adequate sample size difficult, strong scientific

evidence is lacking, and thus conclusions drawn from the literature may be considered less reliable. The major drawback of small studies is they are vulnerable to overestimating the magnitude of an association, which is a limitation of this review. All reviewed papers were single-surgeon studies, and due to the rarity of aniridia patients, there was no strict inclusion criteria, resulting in possible selection bias.

The follow-up times in this review varied greatly, the shortest being the Mostafa and coworkers, with only 2 eyes of 1 patient and a follow-up time of 12 months, and the longest being the Figueiredo and coworkers, with a maximum 120-month follow-up.^{11,31} The Mostafa case had few complications and a large increase in BCVA, but this was just a single case, and was possibly due to its relatively short follow-up time, as many postoperative complications occur much later.³¹ Furthermore, Mostafa and coworkers' case was the only report of BrightOcular artificial iris implants.³¹ This type of iris implant is well-known in literature to be associated in healthy eyes with serious ocular complications, as uveitis, glaucoma, corneal decompensation, with possible blinding consequences.^{13,16,24,25,27,42,48} Several reports describe subsequent explantation of the device in nonaniridia subjects.^{13,25,27,42}

Consequently, the results and outcome reported by Mostafa as a single case should be considered with caution as this deviates from the majority of cases reported in the literature.

While 80% of the included studies had mean follow-up times greater than 24 months, within each study (apart from Mostafa and coworkers), the range of follow-up time had a large variance thus reducing the ability to clearly assess the results. A similar variability in the age of patients at the time of PID implantation was also noted. Caution should therefore be recommended until studies with longer, standardized follow-up times, and stratification of patient age at the time of surgery are conducted, allowing for stronger analyses of factors affecting patient outcomes and complications.⁴⁷ Indeed, in the study by Figueiredo and coworkers¹¹, which had the longest follow-up, the latest BCVA was considered and not the best BCVA post PID implant. This may suggest that the improvement on BCVA is not stable over time.

Choice of PID is made based on the patient, considering the condition of the eye and the iris defect. However, the extent of the iris defect was reported only in one paper.³¹

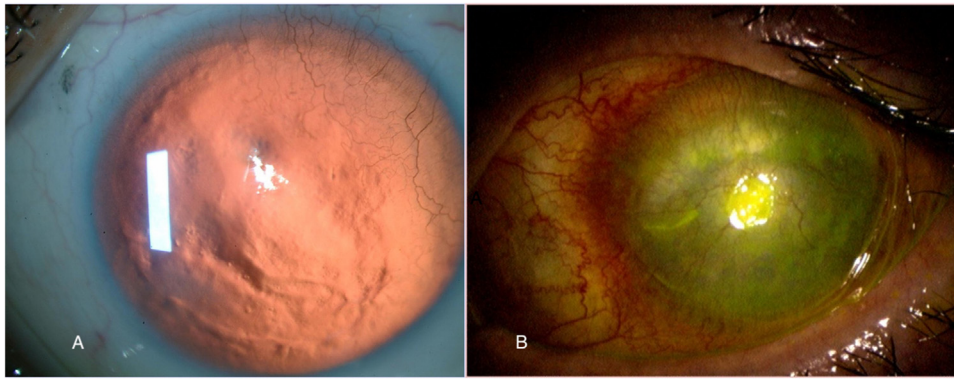


Fig. 9 – Aniridia-associated keratopathy. Grade 2 (A) and Grade 4 (B).

The literature suggests an iris implantation is likely to improve visual acuity and symptoms (glare and/or photophobia), even if the identified studies have high risk of bias. The domains which were at higher risks were those referring to “bias due to confounding” and “bias in selection of reported result.” We are aware that confounding factors may be intrinsic in cases of patients with congenital aniridia, in view of their complex and heterogenous clinical presentation,¹⁸ but they should be clearly assessed to prove the safety and efficacy of a treatment. We consider that, to better evaluate the outcomes and complications, a full examination of the patients’ characteristics must be performed, listing all the possible ocular co-morbidities present or absent at the baseline, to avoid any doubt. Moreover, the evaluation of these comorbidities should be standardized. Indeed, especially in case of aniridia-associated keratopathy, we noticed a wide range of definitions and assessment in the literature, where it would be beneficial to use for example, the novel proposed five-point scale.¹⁷ This new scale accounts for the specific feature of limbal stem cell deficiency (LSCD) observed in patients with congenital aniridia.¹⁷

Grade 0, limbal border are intact, with no conjunctival tissue or vessels crossing the limbus. Grade 1, vessels and conjunctival tissue cross the limbal border within approximately 1 mm from the limbus. The invasion can be localized to one region of the limbus, with other areas of the limbus remaining intact. Grade 2 conjunctival tissue with vessels invades the peripheral and mid-peripheral cornea, without interest the central 2–3 mm of cornea. Grade 3 conjunctival tissue also invades the central cornea (spared at grade 2), subsequently affecting the central visual axis. Typically, a translucent corneal pannus covers the entire corneal surface. Grade 4 the pannus become opaque, vascularized, and thick. In Grades 0–2 central corneal transparency is not impacted, while Grades 3 and 4 affect the central vision (Fig. 9).

The second high-risk domain was “selection of reported result,” in view of the before mentioned high variance of follow-up time, patients age, and lack of subgroup analysis.

Parameters for each study varied, but the functional outcomes of implants were mostly monitored through visual acuity, as either BCVA (or CDVA), using the Snellen chart, the LogMAR chart, or documented poor vision in terms of “hand motion” or “light perception.” Although standardised, differences

of units and human errors in VA measuring techniques mean that it can be difficult to make direct comparisons across papers.¹⁰

Subjective symptoms (glare and photophobia) were not strictly monitored and were always described by patients; a more reliable method could be a questionnaire involving a scoring system whereby patients rate difficulty in performing vision-related daily activities, as proposed by Moghimi and coworkers, who used a modified version of the “Visual Function-14 (VF-14)” questionnaire, while more recently Ayres and coworkers opted for the “25-item National Eye Institute Visual Function Questionnaire (NEI VFQ-25).”^{3,30}

This can help quantify subjective symptoms, which can be used as a valuable indicator of the effects of PID implants. Likewise, cosmetic outcomes were assessed only in 2 papers and were based on the opinions of patients^{31,37}. As for the reduction of the symptoms, also in case of cosmetic outcomes could be useful using a scale, as done by Ayres and coworkers, who proposed the Global Aesthetic Improvement scale to assess the cosmetic results.³ Mostafa and coworkers³¹ was the only study (with a single case) which described the use of “slit-lamp photography and ultrasonic biomicroscopy to evaluate the artificial iris positioning and contact with uveal structures” to properly assess the aesthetic outcome of the implant, thereby providing a more accurate understanding of the cosmetic position of the artificial iris implant. Moreover, attention should be paid to the pupil centration after PID, as the literature suggest that it is an important parameter correlated to personal aesthetic satisfaction.⁵⁴

The Morcher series iris-lens diaphragm (ILD) prostheses are the most frequently described in the literature in cases of congenital aniridia (specifically, the models 67F and 67G). Morcher devices are polymethylmethacrylate (PMMA) black-colored implants, with various types of occluding segments for total or partial aniridia correction.¹² The 67G and 67F have the same central optic of 5 mm in diameter, while the differences are in the aptics diameter, of 13.5 mm in the 67F and 12.5 mm in the model 67G.

The ILD can be implanted in the ciliary sulcus if adequate capsular support is present, otherwise their aptics are often sutured trans-sclerally.^{37,38} A possible endocapsular implantation, using the Morcher model 67G, is reported by Menenezo et al, previous performing a larger capsulorhexis.²⁹

Additionally, the implantation requires a wide incision, ≥ 10 mm, which can be corneal or scleral.^{5,6,29,30,36–38,45} A corneal approach may be chosen aiming to reduce the risk of intra and postoperative hemorrhage,³⁸ whereas a scleral approach may preserve the cornea, already at risk of delayed reepithelization in view of LSCD associated to congenital aniridia.¹⁹ The lack of comparative studies among these techniques, however, make it difficult to recommend a particular approach, and, until now, no differences have been reported in terms of the incidence of complications.

Multiple authors place importance on the position of the prosthesis for favorable long-term outcomes, and ILDs have been described as difficult to place centrally, owing to a lack of a central pupil to provide reference for an optic axis.^{5,45}

The incidence of BCVA deterioration after ILD implantation was roughly equal to that after AI implantation; however, the slightly higher rate of postoperative complications with ILD can be detrimental to patient outcomes. ILDs work by substituting the optical function of the lens and diaphragm function of the lens simultaneously, therefore, making it a preferable choice of implant for patients presenting with both aniridia and aphakia, rather than patients who present instead with aniridia and cataract.^{12,18} The ILD prostheses, however, were associated with a higher rate of endothelial cell loss compared with AI.

Use of the AI has increased in recent years. The AI, due to its foldable silicone material, can be implanted through a small corneal incision, roughly 3.2 mm (for the fiber model which can be placed in the sulcus and then trans-sclerally sutured, in case of lens coloboma, and lack of capsular support), or 2.5 mm for suture-less technique (fiber-free model, which can be placed in the capsular bag above the IOL).⁴⁵ Its minimally invasive technique is a plausible contributor to its relatively lower rate of complications that were noted in this review.

In case of in-the-bag placement, which guarantee less contact with uveal structure and better centration, a capsular tension ring (CTR) is advisable.^{2,11} This in view to reduce the risk of capsular bag contracture and device buckling.²

About which CTR size to choose, the literature suggests correlations between the capsular bag size and axial length (AL) and corneal power.^{8,28,49} Of these, the most feasible in patients with congenital aniridia may be the AL, with a compressed CTR size of 12.3 mm, in case of AL <24 mm, 13 mm for AL between the 24–28 mm, and 14.5 mm in case of AL > 28 mm.²⁸

AI can be inserted by folding them or using an IOL injector. In the latter case, Amaral and Snyder² suggest folding the AI into a conoid, trifolded orientation, allowing an easier loading into the injector barrel and delivery of the AI in bag with standard (4.8–6.00 mm) capsulorhexis size, obviating the risk related to larger capsulorhexis to facilitate the placement in the bag of AI.

To facilitate the placement of AI in the bag, dyeing the anterior capsule, if not previously performed for the phacoemulsification, may be advisable.²

AI could be also the choice in case of subluxation of an ILD. Indeed, the literature suggest that replacement of ILD with AI with sutured IOL has comparable outcome with better aesthetic results.²⁶

The majority of cases report an IOL-AI implant to correct congenital cataract and aniridia simultaneously. This is a more ethical, efficient and safe method to treat both problems in a single surgery to reduce the risk of complications such as keratopathy after repeated surgeries—as it would be unethical to only correct one condition; however, it prevents the assessment of the effect of the AI alone on the BCVA. As a result, BCVA results are confounded by the simultaneous cataract surgery, performed in 100% of ILD and CTR-based PID and 95.9% of AI cases. Because cataract surgery alone can be expected to improve BCVA in almost all cases and given the modest vision gains of a few logMAR lines in the majority of cases, the additional benefit of PID implantation in improving BCVA would be limited. More reports of rarer cases of PID implantation without cataract surgery are clearly needed. In terms of cosmetic appearance, the AI prosthesis reported the best results, likely due to its customizable nature with a variety of iris colors available.

The use of endocapsular capsular tension ring-based prostheses appears less frequently in the literature, this may be due to their requirement of an intact capsular bag, and the fact that many aniridia patients lack one. Menezo and coworkers discuss the gentle surgical technique required with this prosthesis (a Morcher 50D, which has a diameter of 10 mm) due to their brittle nature and susceptibility to fracture, but also state they are easier to implant, requiring only a small incision of 3.5mm.²⁹

Only one capsular tension-ring based prosthesis was used in the study, however, meaning its results may not be representative, but it does further highlight that, if a prosthesis is easier to implant, the results tend to be favorable. Other authors instead describe their experience with the Morcher 50D prosthesis as time-consuming, requiring precision and dexterity for its accurate alignment.²²

Regarding postoperative complications following artificial iris implantation, in the case of congenital aniridia it is difficult to determine the possible causal relationship between onset of complications and PID implantation. Consequently, is neither possible to confirm nor refute whether artificial iris implantation may be related to complications, given the lack of a control group. Furthermore, studies did not report exactly when the complication arose, but indicated only that the complication was noted during follow-up.

Secondary glaucoma was the most prevalent complication found between various prosthesis types, with a similar prevalence among most studies, around 27%. Its mechanism appears not to be fully understood.^{11,38}

In case of ILD, Reinhard and coworkers hypothesized that post iris implantation glaucoma may be from compression by the prosthesis' haptics onto the trabecular meshwork.³⁸ This theory has been partially questioned by Qiu and coworkers³⁷, because in 2 out of 6 cases of secondary glaucoma reported in their study, the ILD haptics were well positioned in the ciliary sulcus. Therefore, the authors suggested that secondary glaucoma may be not only due to haptic displacement, but possibly also due to blood-aqueous barrier breakdown, chronic irritation by ILD, and inflammation; suggesting also that the implantation of ILD in eyes with existing glaucoma should be performed with caution.

Considering instead AI, the following advice may be helpful to minimize the potential risk of developing glaucoma. First, AI should be always placed in the bag, if possible, to prevent the contact with uveal tissue, reducing inflammation, which, as reported, may be a triggering factor for glaucoma onset or deterioration.^{2,37,39} Second, the diameter of the AI should be chosen measuring the vertical white-to-white (WTW) vertical distance, and under sizing it by 0.5–1.00 mm.³⁹ Finally, the fiber-free AI is preferable over those with embedded fiber; after the trephination and cutting, the sharp-polymer fiber ends of the artificial iris are exposed and can lead to chronic irritation of surrounding tissue, potentially increasing the risk for developing glaucoma.³⁹

In cases of either secondary glaucoma or glaucoma progression which are refractory to the topical treatment, the preferable surgical approach should be the use of glaucoma drainage devices, especially the Baerveldt implant over Ahmed valve, which provides higher success rates compared to other procedures.¹⁵

Corneal endothelial decompensation is another common complication and only reported with ILD, possibly because for the greater diameter of the prosthesis and the requirement of a larger corneal incision for implantation. A possible causal relationship of secondary glaucoma with endothelial cell loss may exist, as both have also been reported as common complications of PID implants in cases of traumatic aniridia.^{36,44}

The complication of aniridia fibrosis syndrome is serious but was only noted in the Figueiredo study,¹¹ who had the largest cohort of patients. This allowed for more reliable statistical analysis to assess whether congenital aniridia was a risk factor for the 3 eyes that developed aniridia fibrosis syndrome, which was not statistically significant, emphasizing that outliers or rare occurrences can be misconstrued within smaller patient groups.

The problem of lack of detailed description of baseline pre-existing ocular comorbidity and postoperative complications is important. Otherwise, the need for multidisciplinary evaluation and management by different ocular subspecialties may be underestimated, particularly in glaucoma and in ocular surface stem cell transplantation in patients with congenital aniridia that tend to present with very complex cases.¹⁸

This systematic review conducted a broad search using various search engines, minimizing the inclusion bias to a feasible extent. This review also assesses included studies using the validated The NOS and the JBI critical appraisal checklists and scoring each study to optimize research quality. The use of the Patient/problem, Intervention, Comparison, and Outcome format gave a structure to selecting included studies, allowing for relevant data to be included, while ROBINS I assessment tool evaluated the possible biases of the reviewed literature.

5. Conclusions

We highlight the variability of iris implantation outcomes in congenital aniridia. Our aim was to identify which prosthesis exhibited the most favorable outcomes; however, this proved difficult, and conclusions drawn from results may not be truly representative, being possibly overly positive. Each

type of prosthesis and technique presented with several adverse complications, and despite being able to associate some with certain prostheses, most complications appeared across all devices seemingly at random. The most prevalent complication was postoperative glaucoma secondary to iris device implantation. The mechanisms behind this and other complications, however, are not fully understood. Further research in mechanisms leading to the observed complications would be of great benefit. Once an understanding is established, surgeons can work to prevent them to avoid multiple interventions and improve patient outcomes.

Ideally, the use of randomized-control groups alongside patients are needed; however, ethical issues of restricting a potentially beneficial treatment to some patients would need to be considered, and it may be difficult to find homogeneous study groups as many ocular comorbidities exist in aniridia. Although congenital aniridia is a rare disease, ideally large prospective randomized control trials (RCTs) would be needed to achieve an appropriate level of scientific evidence concerning the use, outcomes, and complications of artificial iris devices. We are aware that RCTs may be difficult in case of congenital aniridia in view of lack of homogeneous subjects; however, well-designed nonrandomized studies (NRSs) may provide good clinical practice evidence.⁴⁶ One issue is that the current literature, despite being composed of NRSs, suffers from high risk of bias, as shown with the ROBINS-tool. Another important issue is the lack of outcome measures specific for aniridia, where the patient may benefit from interventions despite a lack of objective improvement in visual acuity. Furthermore, research is needed on the optimal time to implant the prosthetic iris device.

The use of an iris prosthesis appears to be beneficial in terms of subjective symptom improvement among patients, although more quantitative and objective measures are needed. The results suggest the AI is associated with slightly more favorable outcomes; however, the success of a PID implantation appears to rely on individual patient anatomy, existing technology, and surgical skill.

The potential benefits and risks of artificial iris implantation in congenital aniridia should also be carefully weighed. The risk of developing secondary glaucoma or worsening of the existing glaucoma is significant and may lead to multiple unplanned interventions and need for long-term medications. The risk of triggering or aggravating the keratopathy may be even more serious, possibly needing additional interventions, as limbal stem cell transplant (LSCT) including keratolimbal allograft (KLAL) transplantation, living-related conjunctival-limbal allograft (lr-CLAL) transplantation, corneal transplantation, and Boston keratoprosthesis (KPro).^{1,4,7,9,15,50,53}

These procedures require a careful management (systemic immunosuppression for LSCT, and, in case of KPro possibly severe complications, as retroprosthetic membrane, glaucoma, corneal melt, and endophthalmitis), and they have a failure rate around the 40%, reaching, according to Jacobson and coworkers, 100% for LSCT at 5-years.^{9,15,50,53} Of note, autologous limbal stem cell transplantation is not advisable, in view of bilaterality of the AAK.¹⁸

These risks would need to be considered against the potential benefits of possible improved vision and symptom relief. Although vision was reported to improve in the majority of

cases, the vision generally is low in aniridia and the best attainable vision is limited by the condition of the cornea, lens and fovea, along with nystagmus. Still, 37% of cases had no change or reduction in vision after iris implantation, while those with vision improvement may have benefitted more from the concomitant cataract operation than the iris implant itself. While improvement in BCVA was modest, the improvement in functional vision was less clear and would require more detailed investigation of patient satisfaction and ability to perform vision-related tasks. This is an important point, as published studies tend to evaluate the efficacy of an PID mainly focusing on the BCVA, whereas in patients with congenital aniridia the improvement of symptoms and improvement of health-related quality of life affected by vision should be the main focus. It is thus imperative that surgeons and patients both understand the risk/benefit scenario before the decision to implant an artificial iris implantation is made, keeping in mind the limited scientific literature on this topic and the limitations and risks of bias within the individual studies.

6. Method of literature search

This study was a systematic review. The literature search was conducted on PubMed, Scopus, Cochrane, and Web of Science was performed independently by 2 reviewers. The search included the following terms (Iris) AND (aniridia OR WAGR syndrome OR Wilms tumor OR nephroblastoma OR Gillespie syndrome OR cerebellar ataxia) AND (implant OR prosthesis OR artificial OR device), with no set limitations on searching fields, date or language. Each search term is either a synonym for 'implant' or a disease associated with aniridia, allowing for a broad search, and minimizing potential selection bias. All retrieved literature was screened, and the following exclusion criteria were applied non-English language, nonhuman studies, cohort of aniridia patients not receiving iris implantation, nonpeer reviewed publications, traumatic aniridia. (Table 1).

Fig. 7 Reprinted from American Journal Ophthalmology Case Reports, Vol 12. Authors Zale Mednick, Devin Betsch, Tanguy Boutin, Adi Einan-Lifshitz, Nir Sorkin, Allan Slomovic. "Bilateral BrightOcular iris implants necessitating explantation and subsequent endothelial keratoplasty" 42,018, with permission from Elsevier.

7. Footnotes

Prosthetic iris devices (PIDs); iris-lens diaphragm (ILD); capsular tension ring-based prosthetic iris device (CTR – based PID); customized Artificial Iris (AI); The Newcastle-Ottawa Scale (NOS); Joanna Briggs Institute (JBI); Risk of Bias in Nonrandomized Studies of Interventions (ROBINS-I)

8. Disclosures

The authors have no conflicts of interest to disclose. This research did not receive any specific grant from funding agencies in the public, commercial, or not-for-profit sectors.

Acknowledgment

The authors also wish to acknowledge the support of the European Union COST Action CA-18116 ANIRIDIA-NET.

REFERENCES

- Álvarez de Toledo Elizalde J, López García S, Benítez del Castillo JM, et al. Aniridia and the ocular surface Medical and surgical problems and solutions. *Arch Soc Esp Oftalmol*. 2021;96:15–37. doi:10.1016/j.oftale.2021.04.003.
- Amaral HL, Snyder ME. In-the-bag injection and overfold technique for custom flexible prosthetic iris prostheses. *J Cataract Refract Surg*. 2022;48:634–6. doi:10.1097/j.jcrs.0000000000000928.
- Ayres BD, Fant BS, Landis ZC, et al. Results of the United States Food and Drug Administration Clinical Trial of the CustomFlex Artificial Iris. *Ophthalmology*. 2022;129:614–25. doi:10.1016/j.ophtha.2022.01.029.
- Behaegel J, Tassignon MJ, Lagali N, Consejo A, Koppen C, Ní Dhubhghaill S. Outcomes of human leukocyte antigen-matched allogeneic cultivated limbal epithelial transplantation in aniridia-associated keratopathy—a single-center retrospective analysis. *Cornea*. 2022;41:69–77. doi:10.1097/ICO.0000000000002729.
- Beltrame G, Salvetat ML, Chizzolini M, et al. Implantation of a black diaphragm intraocular lens in ten cases of post-traumatic aniridia. *Eur J Ophthalmol*. 2018;13:62–8. doi:10.1177/112067210301300109.
- Brown MJ, Hardten DR, Knish K. Use of the artificial iris implant in patients with aniridia. *J Am Optom Assoc*. 2005;76. doi:10.1016/S1529-1839(05)70280-3.
- Cheung AY, Eslani M, Kurji KH, et al. Long-term outcomes of living-related conjunctival limbal allograft compared with keratolimbal allograft in patients with limbal stem cell deficiency. *Cornea*. 2020;39:980–5. doi:10.1097/ICO.0000000000002329.
- Dong FY, Joo CK. Predictability for proper capsular tension ring size and intraocular lens size. *Korean J Ophthalmol*. 2001;15:22. doi:10.3341/kjo.2001.15.1.22.
- Dyer A, de Faria A, Julio G, Álvarez de Toledo J, Barraquer RI, de la Paz MF. Long-term anatomical and functional survival of Boston Type 1 Keratoprosthesis in congenital aniridia. *Front Med (Lausanne)*. 2021;8. doi:10.3389/fmed.2021.749063.
- Elliott DB. The good (logMAR), the bad (Snellen) and the ugly (BCVA, number of letters read) of visual acuity measurement. *Ophthalmic Physiol Opt*. 2016;36:355–8. doi:10.1111/opo.12310.
- Figueiredo GB, Snyder ME. Long-term follow-up of a custom-made prosthetic iris device in patients with congenital aniridia. *J Cataract Refract Surg*. 2020;46. doi:10.1097/j.jcrs.0000000000000175.
- Forlini C, Forlini M, Rejdak R, et al. Simultaneous correction of post-traumatic aphakia and aniridia with the use of artificial iris and IOL implantation. *Graefes Arch Clin Exp Ophthalmol*. 2013;251:667–75. doi:10.1007/S00417-012-2254-7.
- Ghaffari R, Aldave AJ, Al-Hashimi S, Miller KM. Complications of cosmetic artificial iris implantation and post explantation outcomes. *Am J Ophthalmol*. 2021;226:156–64. doi:10.1016/j.ajo.2021.01.005.
- Hos D, Heindl LM, Bucher F, Cursiefen C. Novel lamellar, flap-based tattooing techniques for corneal opacities in scarred and vascularized blind eyes. *Cornea*. 2015;34:82–6. doi:10.1097/ICO.0000000000000259.
- Jacobson A, Mian SI, Bohnsack BL. Clinical outcomes and visual prognostic factors in congenital aniridia. *BMC Ophthalmol*. 2022;22:235. doi:10.1186/s12886-022-02460-5.

16. Koaik MK, Mansour AM, Saad A, Farah SG. BrightOcular® cosmetic iris implant a spectrum from tolerability to severe morbidity. *Case Rep Ophthalmol.* 2018;9:395–400. doi:10.1159/000492745.
17. Lagali N, Wowra B, Fries FN, et al. Early phenotypic features of aniridia-associated keratopathy and association with PAX6 coding mutations. *Ocul Surf.* 2020;18:130–40. doi:10.1016/j.jtos.2019.11.002.
18. Landsend ECS, Lagali N, Utheim TP. Congenital aniridia – a comprehensive review of clinical features and therapeutic approaches. *Surv Ophthalmol.* 2021 Published online. doi:10.1016/j.survophthal.2021.02.011.
19. Latta L, Figueiredo FC, Ashery-Padan R, et al. Pathophysiology of aniridia-associated keratopathy developmental aspects and unanswered questions. *Ocul Surf.* 2021;22:245–66. doi:10.1016/j.jtos.2021.09.001.
20. Lee HJ, Colby KA. A review of the clinical and genetic aspects of aniridia. *Semin Ophthalmol.* 2013;28. doi:10.3109/08820538.2013.825293.
21. Lim HT, Kim DH, Kim H. PAX6 aniridia syndrome clinics, genetics, and therapeutics. *Curr Opin Ophthalmol.* 2017;28:436–47. doi:10.1097/ICU.0000000000000405.
22. Lin SR, Miller KM. Lessons learned from implantation of Morcher 50D and 96S artificial iris diaphragms. *Case Rep Ophthalmol.* 2017;8:527–34. doi:10.1159/000484128.
23. Ma LL, Wang YY, Yang ZH, Huang D, Weng H, Zeng XT. Methodological quality (risk of bias) assessment tools for primary and secondary medical studies what are they and which is better? *Mil Med Res.* 2020;7:7. doi:10.1186/s40779-020-00238-8.
24. Mansour AM, Ahmed IIK, Eadie B, et al. Iritis, glaucoma and corneal decompensation associated with BrightOcular cosmetic iris implant. *Br J Ophthalmol.* 2016;100:1098–101. doi:10.1136/bjophthalmol-2015-307295.
25. Mathew D, Belkin A, Schlenker M. Explantation of BrightOcular cosmetic iris implant and goniosynechialysis a case report. *Indian J Ophthalmol.* 2019;67:1357. doi:10.4103/ijo.IJO_2000_18.
26. Mayer C, Scharf D, Khoramnia R. Austausch von Aniridie-IOL gegen individuelle Iris-IOL-implantate. *Der Ophthalmologe.* 2022;119:181–9. doi:10.1007/s00347-021-01447-9.
27. Mednick Z, Betsch D, Boutin T, Einan-Lifshitz A, Sorkin N, Slomovic A. Bilateral BrightOcular iris implants necessitating explantation and subsequent endothelial keratoplasty. *Am J Ophthalmol Case Rep.* 2018;12:1–4. doi:10.1016/j.ajoc.2018.07.001.
28. Menapace R, Findl O, Georgopoulos M, Rainer G, Vass C, Schmetterer K. The capsular tension ring Designs, applications, and techniques. *J Cataract Refract Surg.* 2000;26:898–912. doi:10.1016/S0886-3350(00)00446-6.
29. Menezes JL, Martínez-Costa R, Cisneros AM, Desco MC. Implantation of iris devices in congenital and traumatic aniridias surgery solutions and complications. *Eur J Ophthalmol.* 2005;15:451–7. doi:10.5301/EJO.2008.1727.
30. Moghimi S, Riazi Esfahani M, Maghsoudipour M. Visual function after implantation of aniridia intraocular lens for traumatic aniridia in vitrectomized eye. *Eur J Ophthalmol.* 2007;17:660–5. doi:10.1177/112067210701700428.
31. Mostafa YS, Osman AA, Hassanein DH, Zeid AM, Sherif AM. Iris reconstruction using artificial iris prosthesis for management of aniridia. *Eur J Ophthalmol.* 2018;28. doi:10.5301/ejo.5000991.
32. Munn Z, Barker TH, Moola S, et al. Methodological quality of case series studies an introduction to the JBI critical appraisal tool. *JBI Evid Synth.* 2020;18:2127–33. doi:10.11124/JBISIR-D-19-00099.
33. Ogawa GS, O’Gawa GM. Single wound, in situ tying technique for iris repair. *Ophthalmic Surg Lasers.* 1998;29(11):943–8.
34. Overview | Artificial iris insertion for acquired aniridia. Guidance | NICE. 2021. Published 2020. Accessed August 3 <https://www.nice.org.uk/guidance/igp674>.
35. Pozdeyeva NA, Pashtayev NP, Lukin VP, Batkov YN. Artificial iris-lens diaphragm in reconstructive surgery for aniridia and aphakia. *J Cataract Refract Surg.* 2005;31:1750–9. doi:10.1016/j.jcrs.2005.02.037.
36. Qiu X, Ji Y, Zheng T, Lu Y. Long-term efficacy and complications of black diaphragm intraocular lens implantation in patients with traumatic aniridia. *Br J Ophthalmol.* 2015;99:659–64. doi:10.1136/BJOPHTHALMOL-2014-305581.
37. Qiu X, Ji Y, Zheng T, Lu Y. The efficacy and complications of black diaphragm intra-ocular lens implantation in patients with congenital aniridia. *Acta Ophthalmol.* 2016;94. doi:10.1111/aos.12923.
38. Reinhard T, Engelhardt S, Sundmacher R. Black diaphragm aniridia intraocular lens for congenital aniridia long-term follow-up. *J Cataract Refract Surg.* 2000;26. doi:10.1016/S0886-3350(99)00432-0.
39. Rickmann A, Szurman P, Januschowski K, et al. Long-term results after artificial iris implantation in patients with aniridia. *Graefes Arch Clin Exp Ophthalmol.* 2016;254:1419–24. doi:10.1007/s00417-016-3292-3.
40. Samant M, Chauhan BK, Lathrop KL, Nischal KK. Congenital aniridia etiology, manifestations and management. *Expert Rev Ophthalmol.* 2016;11:135. doi:10.1586/17469899.2016.1152182.
41. Schardt C, Adams MB, Owens T, Keitz S, Fontelo P. Utilization of the PICO framework to improve searching PubMed for clinical questions. *BMC Med Inform Decis Mak.* 2007;7:16. doi:10.1186/1472-6947-7-16.
42. Shalash A, el Bahrawy M. Five-slice technique for the explantation of complicated BrightOcular® cosmetic iris implants. *Int Ophthalmol.* 2020;40:1565–70. doi:10.1007/s10792-020-01328-1.
43. Siepser SB. The closed chamber slipping suture technique for iris repair. *Ann Ophthalmol.* 1994;26(3):71–2.
44. Spitzer MS, Yoeruek E, Leitritz MA, Szurman P, Bartz-Schmidt KU. A new technique for treating posttraumatic aniridia with aphakia first results of haptic fixation of a foldable intraocular lens on a foldable and custom-tailored iris prosthesis. *Arch Ophthalmol.* 2012;130:771–5. doi:10.1001/ARCHOPHTHALMOL.2011.1778.
45. Srinivasan S, Ting DSJ, Snyder ME, Prasad S, Koch HR. Prosthetic iris devices. *Can J Ophthalmol.* 2014;49:6–17. doi:10.1016/j.jcjo.2013.10.001.
46. Sterne JA, Hernán MA, Reeves BC, et al. ROBINS-I a tool for assessing risk of bias in non-randomised studies of interventions. *BMJ.* Published online. 2016:i4919. doi:10.1136/bmj.i4919.
47. Thompson CG, Fawzy K, Bryce IG, Noble BA. Implantation of a black diaphragm intraocular lens for traumatic aniridia. *J Cataract Refract Surg.* 1999;25. doi:10.1016/S0886-3350(99)00049-8.
48. Varna-Tigka K, Löffler F, Kohnen T. Bilaterale Irisimplantatexplantation bei Pigmentdispersionssyndrom (PDS) und Hornhautdekomensation nach kosmetischer Irisimplantation (BrightOcular). *Der Ophthalmologe.* 2020;117:1116–20. doi:10.1007/s00347-020-01040-6.
49. Vass C, Menapace R, Schmetterer K, Findl O, Rainer G, Steineck I. Prediction of pseudophakic capsular bag diameter based on biometric variables12. *J Cataract Refract Surg.* 1999;25:1376–81. doi:10.1016/S0886-3350(99)00204-7.
50. Viberg A, Vicente A, Samolov B, Hjortdal J, Byström B. Corneal transplantation in aniridia-related keratopathy with a two-year follow-up period, an uncommon disease with precarious course. *Acta Ophthalmol.* 2022 Published online August 9. doi:10.1111/aos.15229.

51. Wachler BB, Krueger RR. Double-armed McCannell suture for repair of traumatic iridodialysis. *Am J Ophthalmol.* 1996;122. doi:10.1016/S0002-9394(14)71971-3.
52. Wells G, Shea B, O'Connell D, et al. The Newcastle-Ottawa Scale (NOS) for assessing the quality of nonrandomised studies in meta-analyses. Published 2000. Accessed November 30, 2022. https://web.archive.org/web/20210716121605id_/http://www3.med.unipmn.it/dispense_ebm/2009-2010/Corso%20Perfezionamento%20EBM_Faggiano/NOS_oxford.pdf.
53. Yazdanpanah G, Bohm KJ, Hassan OM, et al. Management of congenital aniridia-associated keratopathy long-term outcomes from a tertiary referral center. *Am J Ophthalmol.* 2020;210:8–18. doi:10.1016/j.ajo.2019.11.003.
54. Yildirim TM, Khoramnia R, Masyk M, Son HS, Auffarth GU, Mayer CS. Aesthetics of iris reconstruction with a custom-made artificial iris prosthesis. *PLoS One.* 2020;15:e0237616. doi:10.1371/journal.pone.0237616.