

## Biobanking corneal tissues for emergency procedures during COVID-19 era

Dear Editor,

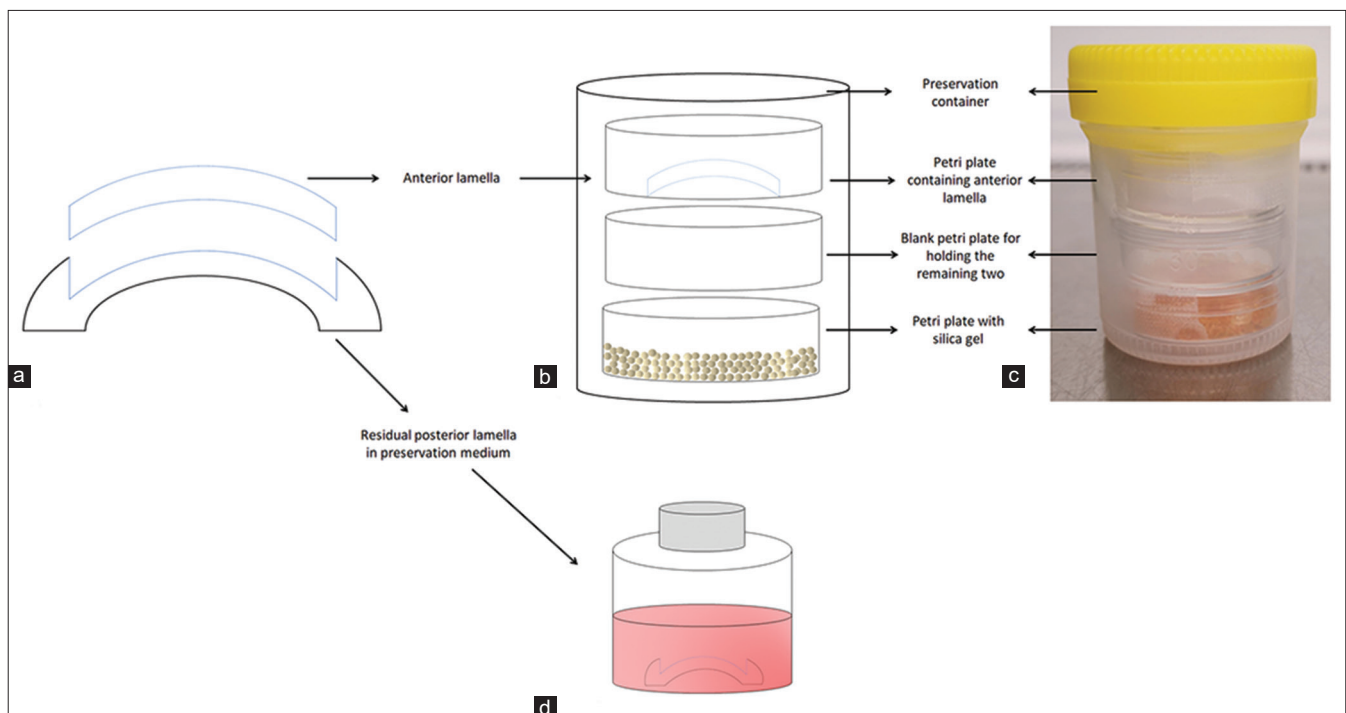
COVID-19 pandemic has significantly affected the ophthalmic practice and the eye banking field.<sup>[1,2]</sup> Hence, new guidelines are being developed to safeguard corneal transplantation. Recently, in a retrospective study, we reported a significant decline in the number of tissues procured (-41%) and distributed for transplantation (-62%) in 2020 compared with 2019 at the Veneto Eye Bank Foundation, Venice, Italy. However, one week after the lockdown was lifted, although the procurement did not improve significantly (-30%) the request for tissues had already inclined (+14%) as soon as the elective surgeries were partially resumed.<sup>[3]</sup> A similar trend, in terms of tissue procurement is therefore expected in other centers that have been severely hit by COVID-19. For such reasons, it is not only important to procure the tissues, but also to store the previously collected tissues for a longer period until the surgeries are resumed.

In a recent laboratory investigation,<sup>[4]</sup> we reported that dehydrating corneal tissue (after removing the endothelium) for up to 14 days by placing silica gel around the tissue can be a potential viable option for storing corneal tissues for emergency procedures. Once re-hydrated, this procedure has shown no impact on tissue transparency, but reduction in overall thickness by 147  $\mu\text{m}$  (speculated to be due to epithelial cell loss) after rehydration. The stiffness profile (tensile stress-strain) did not show any significant difference before (27 mPa) or after

rehydration (31 mPa). Periodic acid-Schiff showed presence of keratocytes and the protein ( $\alpha$ -SMA) was expressed after rehydration. This means that the tissue maintained the characteristics required for anterior lamellar keratoplasty.

In a retrospective clinical study between May 2001 and June 2017, seventeen rehydrated tissues that were stored for  $8.4 \pm 2.9$  [Range 4-12] months in dehydrated form were transplanted in a tertiary eye centre after obtaining full consent from the patient. The corneal tissue was cut into anterior and posterior lamellae [Fig. 1a]. The anterior lamella, after washing with sterile PBS, was placed in a sterile petri plate. Another petri plate was filled with silica gel. The tissue and the gel were stored in a container in the order shown in Fig. 1b and the entire unit [Fig. 1c] was preserved between 2-8°C. Simultaneously, the residual posterior lamella was stored in organ culture media supplemented with 6% dextran T-500 at 31°C [Fig. 1d]. The entire procedure was carried out in a laminar flow hood ensuring complete sterility. Before transplantation, the anterior lamella was rehydrated in sterile BSS for 15-30 minutes to regain the thickness and transparency. The storage media from the posterior lamella was collected for microbiological examination following the standard operating procedure [Note: If the posterior lamella was deemed suitable for transplantation during the storage tenure then the microbiological examination performed before shipping the posterior lamella was considered final for both, anterior and posterior lamella].

Only emergency procedures such as corneal perforation due to corneal infection or trauma, grafts for keratoconus, corneal surgery combined with vitrectomy and others were performed in case of unavailability of tissues. Microbiological examination



**Figure 1:** Dehydration process to store corneal grafts. (a) Representation of a corneal tissue divided into anterior and posterior lamellae. (b) Representation of the storage container containing petri plate with the anterior lamella (top), blank petri plate for holding (middle) and petri plate filled with silica gel (bottom). (c) Real-time storage container with anterior lamella and silica gel, which is preserved between 2-8°C. (d) Representation of storing the posterior lamella from the same corneal tissue in the storage medium, which is also used for post preservation microbiological examination

(from the storage media) was confirmed negative, thus ensuring the sterility for all the transplanted grafts. Only one graft showed higher residual astigmatism, the rest did not show any complications during the post-op follow-up (unpublished data). Overall, the advantages of dehydrating a tissue are manifold such as – a) long-term (up to 12 months) preservation of corneal grafts is possible, b) tissues can be preserved at room temperature for short term (0-2 weeks) and between 2-8°C up to 12 months, c) easy to rehydrate with PBS or BSS, d) easily transportable, e) requires minimal manipulation, f) offers option for microbiological examination ensuring sterility of the graft for transplant and g) has economical benefits. However, the dehydration technique does not preserve the corneal endothelium and therefore must only be used for anterior lamellar keratoplasty or emergency procedures.

Various options were recently reviewed to prolong the storage of corneal tissues<sup>[5]</sup> and to ease an immediate burden on the availability of tissues post-COVID-19 lockdown period. Strong evidence is required whether a corneal transplant can transmit the virus from donor to the recipient in order to increase the currently challenged supply of donor tissues. However, until the supply of corneal tissue increases, it could be reasonable to optimally store and utilize a single tissue for multiple transplants, i.e., divide anterior/posterior lamellar grafts and dehydrate the anterior lenticule for future uses, while transplanting the posterior lenticule for DSAEK or DMEK or; sub-selective transplants like Hemi-DMEK or quarter-DMEK.<sup>[6]</sup> This would increase the utility of a single graft to its maximum capacity.<sup>[7]</sup> Given the advantages of using a dehydrated tissue, it appears to be a viable option for long-term storage of surplus tissues.

#### Acknowledgements

The authors thank Mrs. Jaini Parekh for the illustration of Fig. 1.

#### Financial support and sponsorship

Nil.

#### Conflicts of interest

There are no conflicts of interest.

**Mohit Parekh<sup>1,2</sup>, Stefano Ferrari<sup>2</sup>, Alessandro Ruzza<sup>2</sup>, Pia Leon<sup>2,3</sup>, Antonella Franch<sup>2,3</sup>, Davide Camposampiero<sup>2</sup>, Kunal A Gadhvi<sup>4</sup>, Diego Ponzin<sup>2</sup>, Sajjad Ahmad<sup>1,4</sup>, Vito Romano<sup>5</sup>**

<sup>1</sup>Institute of Ophthalmology, University College London, <sup>4</sup>Moorfields Eye Hospital NHS Foundation Trust, London, <sup>5</sup>St. Paul's Eye Unit, Royal Liverpool University Hospital, Liverpool, UK, <sup>2</sup>International Center for Ocular Physiopathology, Fondazione Banca Degli Occhi del Veneto Onlus, <sup>3</sup>Department of Ophthalmology, SS Giovanni and Paolo hospital, Venice, Italy

**Correspondence to:** Dr. Mohit Parekh,

Institute of Ophthalmology, University College London, 11-43 Bath Street, London EC1V 9EL, UK.  
E-mail: [m.parekh@ucl.ac.uk](mailto:m.parekh@ucl.ac.uk)

## References

1. Busin M, Christy Yu A, Ponzin D. Coping with COVID-19: An Italian perspective on corneal surgery and eye banking in the time of a pandemic and beyond. *Ophthalmology* 2020;127:e68-9.
2. Romano MR, Montericchio A, Montalbano C, Raimondi R, Allegrini D, Ricciardelli G, *et al.* Facing COVID-19 in ophthalmology department. *Curr Eye Res* 2020;45:653-8.
3. Parekh M, Ferrari S, Romano V, Myerscough J, Jones G, Griffoni C, *et al.* Impact of COVID-19 on corneal donation and distribution. *Eur J Ophthalmol* 2020 Aug 5;1120672120948746.
4. Romano V, Levis HJ, Gallon P, Lacey R, Borroni D, Ponzin D, *et al.* Biobanking of dehydrated human donor corneal stroma to increase the supply of anterior lamellar grafts. *Cornea* 2019;38:480-4.
5. Chaurasia S, Das S, Roy A. A review of long term corneal preservation techniques: Relevance and renewed interests in the COVID-19 era. *Indian J Ophthalmol* 2020;68:1357-63.
6. Zygoura V, Baydoun L, Ham L, Bourgonje VJA, van Dijk K, Lie JT, *et al.* Quarter-descemet membrane endothelial keratoplasty (Quarter-DMEK) for Fuchs endothelial corneal dystrophy: 6 months clinical outcome. *Br J Ophthalmol* 2018;102:1425-30.
7. Gadhvi KA, Coco G, Pagano L, Kaye SB, Ferrari S, Levis HJ, *et al.* Eye banking: One cornea for multiple recipients. *2020*;39:1599-603.

This is an open access journal, and articles are distributed under the terms of the Creative Commons Attribution-NonCommercial-ShareAlike 4.0 License, which allows others to remix, tweak, and build upon the work non-commercially, as long as appropriate credit is given and the new creations are licensed under the identical terms.

Access this article online	
<b>Quick Response Code:</b>	<b>Website:</b> <a href="http://www.ijo.in">www.ijo.in</a>
	<b>DOI:</b> 10.4103/ijo.IJO_2615_20

**Cite this article as:** Parekh M, Ferrari S, Ruzza A, Leon P, Franch A, Camposampiero D, *et al.* Biobanking corneal tissues for emergency procedures during COVID-19 era. *Indian J Ophthalmol* 2021;69:167-8.

© 2020 Indian Journal of Ophthalmology | Published by Wolters Kluwer - Medknow

# TIME IS OF THE ESSENCE

Keeler's MIO – a revolution in Fundus Imaging Technology for adult and paediatric patients, helping Ophthalmologists worldwide conduct fast and affordable retinal examination!



Non-contact & portable digital retinal exams



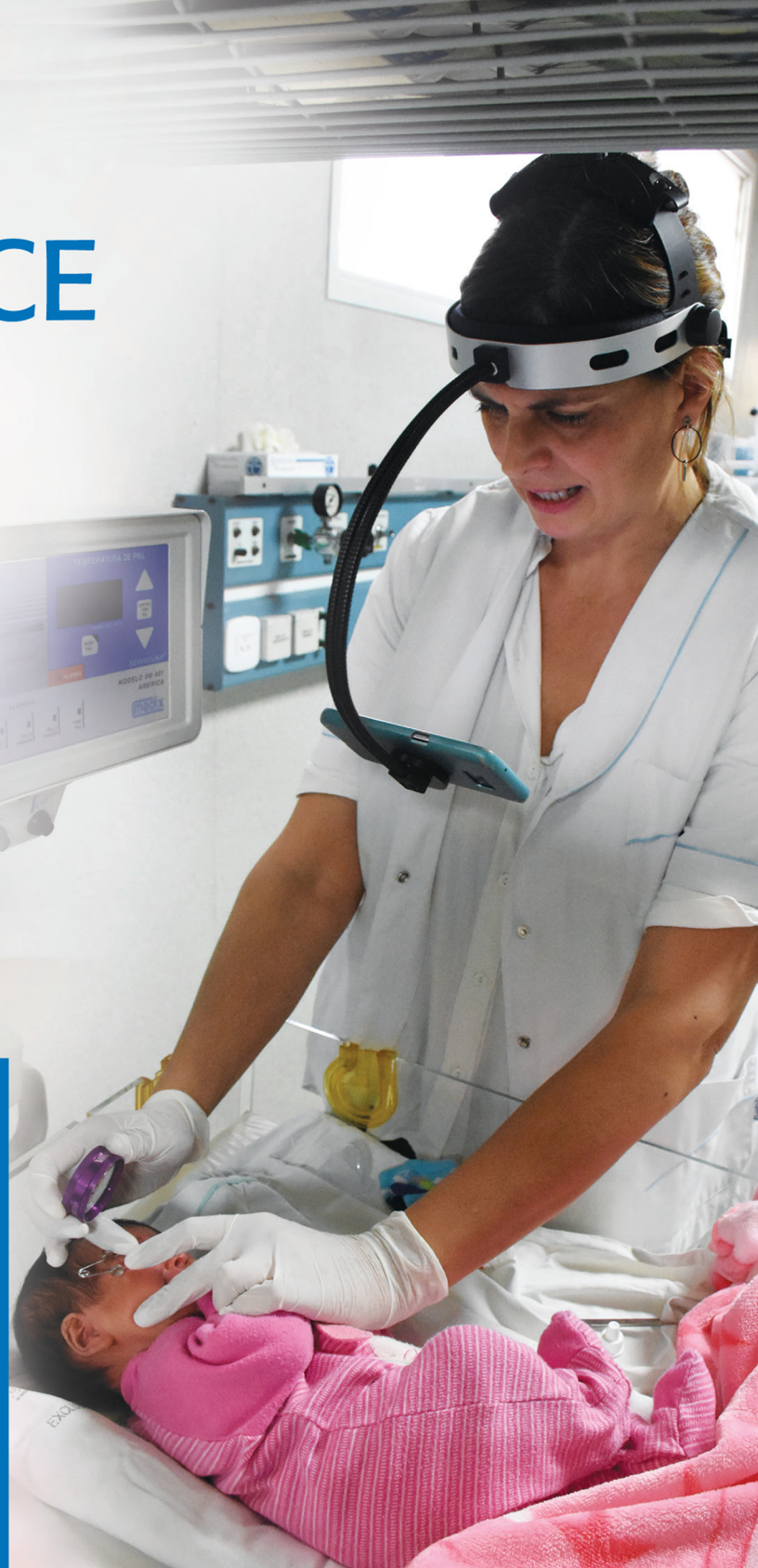Saves time with KineXis Imager for fundus auto-capture



Share documentation securely for patient engagement, education and analysis

“In a busy out-patient environment, the visit led to quick diagnosis, clear explanation of the required treatment to the patient and urgent treatment. The diagnosis would have been difficult to explain to the patient without images of the eye, prolonging the appointment and potentially delaying treatment.”

Dr. N.R. Rangaraj  
Premiere Eye Care, Chennai



Today patients across the world are avoiding essential eye treatment for fear of the on-going pandemic. Innovative telemedicine technology in the ophthalmic field, like MIO, helps ensure safety for both doctor and patient. Retinal treatment is important. [#EyeCareCannotWait](#)

Available in India

[www.keelermio.com](http://www.keelermio.com)



A Halma Company

**Keeler**  
– A world without vision loss –