



## Position Paper

## Diagnostic approach to neonatal and infantile cholestasis: A position paper by the SIGENP liver disease working group



Giusy Ranucci<sup>a,\*</sup>, Claudia Della Corte<sup>b</sup>, Daniele Alberti<sup>c</sup>, Maria Pia Bondioni<sup>d</sup>, Giovanni Boroni<sup>c</sup>, Pier Luigi Calvo<sup>e</sup>, Mara Cananzi<sup>f</sup>, Manila Candusso<sup>b</sup>, Maria Grazia Clemente<sup>g</sup>, Lorenzo D'Antiga<sup>h</sup>, Irene Degrassi<sup>i</sup>, Jean De Ville De Goyet<sup>j</sup>, Fabiola Di Dato<sup>k</sup>, Angelo Di Giorgio<sup>h</sup>, Carlo Dionisi Vici<sup>l</sup>, Federica Ferrari<sup>m</sup>, Paola Francalanci<sup>n</sup>, Maurizio Fuoti<sup>o</sup>, Fabio Fusaro<sup>p</sup>, Paola Gao<sup>f</sup>, Chiara Grimaldi<sup>q</sup>, Maria Iascone<sup>r</sup>, Giuseppe Indolfi<sup>s</sup>, Raffaele Iorio<sup>k</sup>, Giuseppe Maggiore<sup>b</sup>, Claudia Mandato<sup>a</sup>, Lorenza Matarazzo<sup>t</sup>, Lidia Monti<sup>u</sup>, Fabio Mosca<sup>v</sup>, Gabriella Nebbia<sup>i</sup>, Federica Nuti<sup>i</sup>, Giulia Paolella<sup>i</sup>, Michele Pinon<sup>e</sup>, Paola Roggero<sup>v</sup>, Marco Sciveres<sup>w</sup>, Daniele Serranti<sup>s</sup>, Marco Spada<sup>q</sup>, Pietro Vajro<sup>x</sup>, Emanuele Nicastrò<sup>h,\*\*</sup>

<sup>a</sup> Department of Pediatrics, Santobono-Pausilipon Children's Hospital AORN, Naples, Italy

<sup>b</sup> Hepatology, Gastroenterology, Nutrition and Liver transplantation Unit, Bambino Gesù Children's Hospital IRCCS, Rome, Italy

<sup>c</sup> Paediatric Surgery, University of Brescia, Brescia, Italy

<sup>d</sup> Pediatric Radiology, University of Brescia, ASST Spedali Civili di Brescia, Brescia, Italy

<sup>e</sup> Pediatric Gastroenterology Unit, Regina Margherita Children's Hospital, Azienda Ospedaliera-Universitaria Città della Salute e della Scienza, Turin, Italy

<sup>f</sup> Unit of Gastroenterology, Digestive Endoscopy, Hepatology and Care of Children with Liver Transplantation, University Hospital of Padova, Padova, Italy

<sup>g</sup> Department of Medical, Surgical and Experimental Sciences, University of Sassari, Sassari, Italy

<sup>h</sup> Hepatology, Gastroenterology and Transplantation Unit, Hospital Papa Giovanni XXIII, Bergamo, Italy

<sup>i</sup> Service of Paediatric Hepatology, Department of Paediatrics, Fondazione IRCCS Ca' Granda Ospedale Maggiore Policlinico, Milan, Italy

<sup>j</sup> Pediatric Department for the Treatment and Study of Abdominal Diseases and Abdominal Transplantation, ISMETT UPMC, Palermo, Italy

<sup>k</sup> Department of Translational Medical Science, School of Medicine and Surgery, University of Naples Federico II, Naples, Italy

<sup>l</sup> Division of Metabolism and Metabolic Diseases Research Unit, Bambino Gesù Children's Hospital IRCCS, Rome, Italy

<sup>m</sup> Department of Pediatrics, Sant'Eugenio Hospital, Rome, Italy

<sup>n</sup> Department of Pathology, Bambino Gesù Children's Hospital IRCCS, Rome, Italy

<sup>o</sup> Pediatric Gastroenterology and Endoscopy Unit Children's Hospital, ASST Spedali Civili di Brescia, Brescia, Italy

<sup>p</sup> Department of Medical and Surgical Neonatology, Bambino Gesù Children's Hospital IRCCS, Rome, Italy

<sup>q</sup> Division of Abdominal Transplantation and Hepatobiliopancreatic Surgery, Bambino Gesù Children's Hospital IRCCS, Rome, Italy

<sup>r</sup> Medical Genetics Laboratory, Hospital Papa Giovanni XXIII, Bergamo, Italy

<sup>s</sup> Department of Pediatrics, Meyer Children's University Hospital, Florence, Italy

<sup>t</sup> Pediatrics Division, Niguarda Ca' Granda Hospital, Milan, Italy

<sup>u</sup> Department of Radiology, Bambino Gesù Children's Hospital IRCCS, Rome, Italy

<sup>v</sup> Neonatal Intensive Care Unit, Fondazione IRCCS Ca' Granda Ospedale Maggiore Policlinico, Milan, Italy

<sup>w</sup> Pediatric Hepatology and Liver Transplantation, ISMETT UPMC, Palermo, Italy

<sup>x</sup> Department of Medicine, Surgery and Dentistry, "Scuola Medica Salernitana" University of Salerno, Baronissi, Italy

## ARTICLE INFO

## Article history:

Received 3 May 2021

Accepted 12 September 2021

Available online 20 October 2021

## Keywords:

Alagille syndrome

Biliary atresia

Diagnosis

Genetic liver disease

## ABSTRACT

Neonatal and infantile cholestasis (NIC) can represent the onset of a surgically correctable disease and of a genetic or metabolic disorder worthy of medical treatment. Timely recognition of NIC and identification of the underlying etiology are paramount to improve outcomes.

Upon invitation by the Italian National Institute of Health (ISS), an expert working group was formed to formulate evidence-based positions on current knowledge about the diagnosis of NIC.

A systematic literature search was conducted to collect evidence about epidemiology, etiology, clinical aspects and accuracy of available diagnostic tests in NIC. Evidence was scored using the GRADE system.

\* Corresponding author at: Department of Pediatrics, Children's Hospital AORN, Via Mario Fiore, 6 – 80129 – Napoli, Italy.

\*\* Corresponding author at: Pediatric Hepatology, Gastroenterology and Transplantation, Hospital Papa Giovanni XXIII, Piazza OMS, 1 – 24127 – Bergamo, Italy.

Inborn errors of metabolism  
Jaundice  
Monogenic liver disease  
Newborn

All recommendations were approved by a panel of experts upon agreement of at least 75% of the members. The final document was approved by all the panel components.

This position document summarizes the collected statements and defines the best-evidence diagnostic approach to cholestasis in the first year of life.

© 2021 Editrice Gastroenterologica Italiana S.r.l. Published by Elsevier Ltd. All rights reserved.

## 1. Introduction

Neonatal/Infantile cholestasis (NIC) is defined as an impairment in bile formation and/or flow presenting by the first year of age, usually in the first three months, and resulting in the retention of bile and biliary substances within the liver that cause liver damage [1]. NIC affects 1 in 2500 children at term and is caused by either surgical or medical disorders, whose prompt recognition may substantially improve the outcome [2]. The identification of the underlying etiology is compelling in order to initiate appropriate surgical or medical treatment. In fact, the most common cause of NIC is biliary atresia (BA), in which an early surgical referral is needed to optimize the success rate [3]. Also in other treatable inherited metabolic conditions, such as galactosemia or the rare inborn errors of bile acids synthesis, a timely diagnosis certainly warrants a prompt specific treatment and a better outcome [4,5]. The present document aims to provide recommendations to support: a) pediatricians working in primary and secondary care for the initial management of NIC; b) neonatologists and pediatric gastroenterologists working in a tertiary referral center for the extensive diagnostic work-up. To the purposes of this document, NIC is defined in presence of: *i*) serum conjugated bilirubin > 1 mg/dl, when total bilirubin is < 5 mg/dl or *ii*) a conjugated component > 20% of the total, when total bilirubin is > 5 mg/dl, in a child aging less than 1 year [6].

## 2. Methods

The project started in October 2019, under the auspices of the SIGENP (Italian Society for Pediatric Gastroenterology, Hepatology and Nutrition), in response to the invitation by the ISS (Italian National Institute of Health) to draw specific recommendations on diagnosis and management of NIC. A working group consisting of 39 members (26 pediatric hepatologists, 6 pediatric surgeons, 2 radiologists, 2 neonatologists, 1 metabolic diseases specialist, 1 pathologist, 1 geneticist) was formed.

A core panel identified the relevant questions to be addressed, with subgroups of experts being assigned to specific sections, and providing positions based on evidence resulting from a selection of key publications. Every subgroup was responsible for identifying relevant evidence, which included existing guidelines, literature reviews and/or systematic literature search from 1980 to 2020, using accessible relevant databases (PubMed, MEDLINE). For this search, English language restriction was applied while geographical restrictions were not.

Two grades of recommendation were considered (1 = strong and 2 = weak); quality of evidence was scored according to the GRADE system as [7,8]:

- A = High (further research is unlikely to change our confidence in the estimate of effect)
- B = Medium (further research is likely to have impact on our confidence in the estimate of effect)
- C = Low (any estimate of effect is very uncertain).

This position paper does not analyze aspects regarding management and treatment of NIC, that are object of another document.

## 3. Consensus and voting

Panel meetings took place in May 2019 and December 2019 to agree upon document specific issues and the graded positions. In September 2020, due to the COVID-19-related distancing measures, two meetings involving the whole working group took place online to vote each recommendation using the nominal voting technique as follows: agree/disagree. The agreement reached for each recommendation is listed as percentage.

An agreement of at least 75% of the panel members was required to accept the recommendations.

The final document was drafted in January 2021 and was reviewed and approved by all members.

## 4. Causes of neonatal/infantile cholestasis

Hyperbilirubinemia occurs in around 50% of newborns - although not always clinically evident - as an expression of physiological jaundice in the vast majority of cases [9]. Prolonged jaundice (defined as jaundice lasting for longer than 2 weeks), observed in up to 15% of all infants, must evoke the suspicion of a cholestasis promoting further investigations and in particular the determination of serum conjugated bilirubin. Elevated serum levels of conjugated bilirubin define cholestasis. Once cholestasis has been documented in an infant, achieving a rapid etiological definition is of primary importance. The wide spectrum of causes potentially underlying NIC entails a complex diagnostic approach that depends on the accompanying clinical picture. For practical purposes, causes of cholestasis are divided in surgical and medical conditions.

## 5. Surgical causes of cholestasis

### 5.1. Biliary atresia (BA)

BA is the most common identifiable cause of NIC, with an incidence ranging from 0.55 to 1.3 /10,000 live births, the highest incidence being observed in Asia. In addition, it represents the most frequent reason for liver transplantation in childhood [10,11].

BA is the result of a rapidly progressive inflammatory and fibrotic process causing the partial or complete obliteration of the extrahepatic and often the intrahepatic bile ducts. Genetic, epigenetic, malformative, vascular, infective, toxic or autoimmune factors have been investigated in the attempt of clarifying BA pathogenesis that is believed to be likely multifactorial [12].

BA is classified into three types according to morphology (Fig. 1). In the rare types 1 and 2 (~20%), the disease is limited to the distal extrahepatic bile ducts, i.e., the choledocal duct (type 1) and the common hepatic duct (type 2). In these types - more often associated with a better outcome after surgical correction - part of the extrahepatic biliary system can be spared from the inflammatory destruction and thus remains patent and usable for the intervention. In Type 2A, the lower part of the bile ducts (gallbladder and choledocus) can be found at the cholangiography [13]. An extrahepatic biliary cyst at "porta hepatis" is rare (but allowing prenatal suspicion) and is mostly associated with type 1 (once called

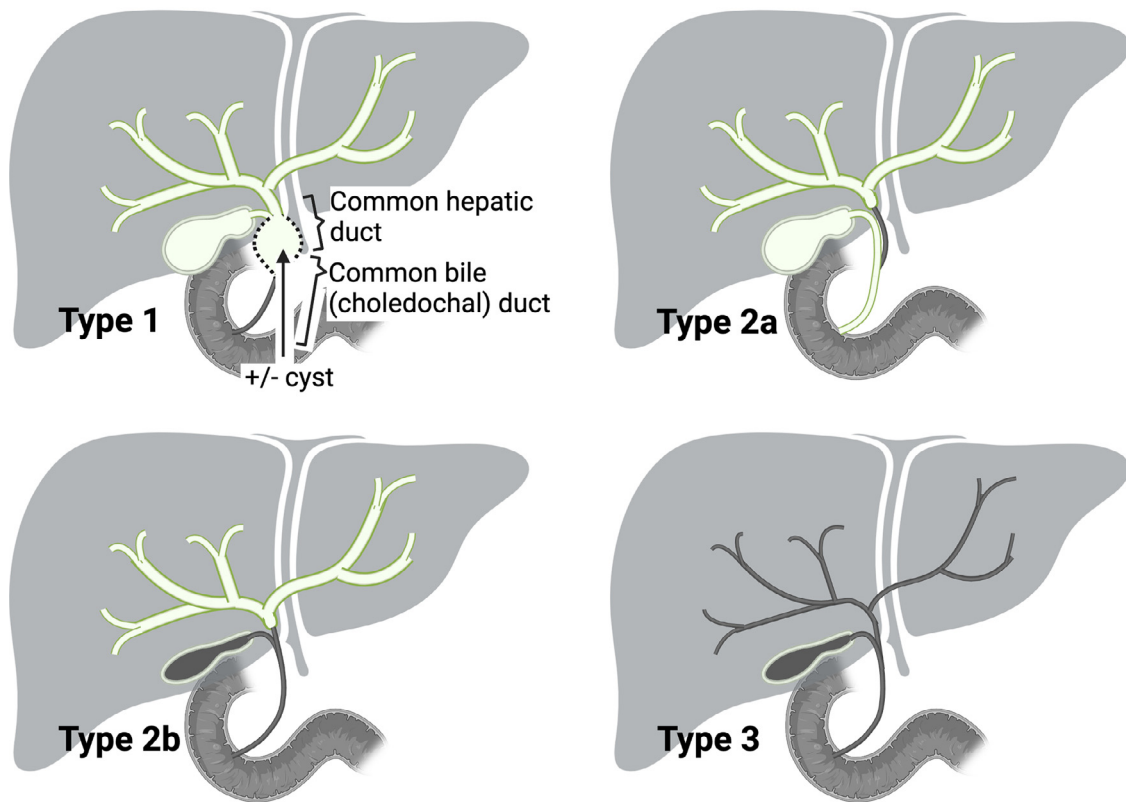


Fig. 1. Types of biliary atresia according to the extent of extrahepatic bile ducts involvement.

“correctable forms” of BA, as the atretic process may be, in these cases, limited to only the lower part of the bile ducts) [14].

In the most common type 3, a deep fibrous plate involves the extrahepatic bile ducts, associated with a fibrous transformation of the gallbladder in most cases, and transformation in mucocele in few ones. In the alternatively adopted French classification, types 2A, 2B, and 3 of the Japanese nomenclature are referred to as types 3, 2, and 4, respectively [15].

Apart from the isolated form, BA can occur in the context of other clinical scenarios. In 20% of cases, BA is associated with extrahepatic malformations, mainly splenic (BA with splenic malformations, BASM). BASM is characterized by asplenia or polysplenia, laterality defects (intestinal malrotation, situs inversus) and cardiovascular malformations (dextrocardia, preduodenal portal vein, agenesis of retro-hepatic inferior vena cava, anomalies superior vena cava) [16].

### 5.2. Choledochal malformation (CM)

CM (or congenital biliary dilatation, CBD) is a pancreaticobiliary anomaly characterized by dilatation of the biliary tract and, in the vast majority of cases, a pancreatico-biliary maljunction (PBM) [17–19].

The diagnosis is based on the abdominal imaging, essentially with ultrasound, but it needs to be confirmed by cholangio-MRI. Regardless of the symptoms or age at presentation, the surgical correction (generally, excision of the extrahepatic bile ducts followed by a bilio-digestive reconstruction using a jejunal Roux-en-Y loop) is mandatory. Timely management is important [20–23] to prevent chronic damage to the liver, biliary obstruction with jaundice, cholangitis and pancreatitis, growth retardation, increased hepatic fibrosis and even cirrhosis. Late malignant transformation

is described and can occur in any portion of the biliary system that will remain in the patient [24–27]. There is however no need for urgent surgery in most cases, and many authors have recommended to delay surgery when possible beyond 6 months and/or a weight > 5 kg, to reduce the risk of complications [21,28]. The differential diagnosis involves liver cyst, duodenal duplication and more importantly cystic biliary atresia.

### 6. Medical causes of neonatal/infantile cholestasis

Beyond the extrahepatic (surgical) causes, the knowledge about the underlying etiology of the medical (non-surgical, so called “intrahepatic”) cholestasis has been rapidly expanding in the last decades. These conditions can be mainly grouped into genetic-metabolic, endocrine, infectious, and related to hematologic conditions.

The extraordinary advance in sequencing techniques has demonstrated that the majority of these conditions are monogenic liver disorders [29]. Genetic causes include defects in canalicular bile acid transport (e.g. progressive familial intrahepatic cholestasis, PFIC), tight junction defects, inborn errors of bile acid metabolism, inborn errors of metabolism (IEM) not related to bile acid synthesis, and other pictures in the context of syndromic/systemic conditions.

The main clinical and laboratory findings are listed in Table 1. Although these diseases are generally poorly identifiable on the clinical grounds, definite diagnosis is important to identify treatable conditions. Congenital endocrine disorders also may present with cholestatic jaundice, while in presence of an acutely/critically ill infant with severe liver function impairment, a severe systemic infection, or a decompensated metabolic disorder should be suspected.

**Table 1**  
Intra- and extra-hepatic causes of neonatal and infantile cholestasis and their biochemical features.

Disease	Laboratory hallmarks and biomarkers	Gene
<b>EXTRA-HEPATIC CAUSES</b>		
Biliary atresia	High platelets count; high GGT, sBA.	NA
Choledocal cyst	-	NA
Cholelithiasis	-	NA
Inspissated bile/mucous plug	-	NA
Congenital perforation of common bile duct	-	NA
<b>INTRAHEPATIC CHOLESTASIS</b>		
Cystic fibrosis *	Elevated sweat chloride	CFTR
$\alpha$ -1-antitrypsin deficiency	Low serum A1AT	SERPINA1
<b>Defects of the biliary canalicular transport</b>		
PFIC1	High sBA; low GGT; elevated sweat chloride	ATP8B1
PFIC2	High sBA; low GGT; high AFP	ABCB11
PFIC3	High sBA; high GGT	ABCB4
FXR deficiency (PFIC5)	High sBA; low GGT; high AFP	NR1H4
MYO5B cholestasis	High sBA; low GGT	MYO5B
<b>Tight junction defects</b>		
TJP2 deficiency (PFIC4)	High sBA; low GGT	TJP2
USP53 deficiency	High sBA; low GGT	USP53
NISCH syndrome	High sBA; high GGT	CLDN1
<b>Bile acid synthesis and conjugation disorders</b>		
3- $\beta$ -HSD-oxidoreductase deficiency	Low sBA, GGT; bile acid mass spectrometry	HSD3B7
D4-3-oxosteroid 5 $\beta$ -reductase deficiency	High GGT; low sBA; biliary acid mass spectrometry	AKR1D1
Cerebrotendinous xanthomatosis	Low sBA; high cholesterol and cholestanol	CYP27A1
BACL deficiency	Low GGT, sBA; biliary acid mass spectrometry	SLC27A5
BAAT deficiency	Low GGT, sBA; biliary acid mass spectrometry	BAAT
2-methylacil-CoA racemase deficiency	Low GGT, sBA; biliary acid mass spectrometry	AMACR
Oxysterol-7 $\alpha$ -hydroxylase deficiency	Low GGT, sBA; biliary acid mass spectrometry	CYP7B1
<b>Biliary development defects</b>		
Alagille syndrome	High GGT, sBA, cholesterol, triglycerides	JAG1, NOTCH 2
Neonatal sclerosing cholangitis	High GGT, sBA	DCDC2; CLDN1
ARC syndrome	High sBA; low or high GGT; metabolic acidosis, hypophosphatemia	VPS33B, VIPAS39
Caroli disease	High GGT, sBA	PKHD1
Ciliopathies	High GGT, sBA	different genes
<b>Lysosomal storage disease</b>		
Niemann-Pick disease type C *	Markedly elevated oxysterols and lysosphingolipids in plasma; accumulation of intracytoplasmic unesterified cholesterol in skin fibroblasts (filipin staining); elevated chitotriosidase; sea blue histiocytes in bone marrow	NPC1; NPC2
Acid sphingomyelinase deficiency (Niemann-Pick disease type A and B) *	Markedly elevated oxysterols and lysosphingolipids in plasma; reduced acid sphingomyelinase activity (dried blood spot, leukocytes, fibroblasts);	SMPD1
Lysosomal acid lipase deficiency (Wolman disease) *	Reduced acid lipase activity (dried blood spot, leukocytes, fibroblasts); abnormal lipid profile; vacuolated lymphocytes; macrophage activation	LIPA
Gaucher disease (neurologic) *	Reduced glucocerebrosidase activity (dried blood spot, leukocytes, fibroblasts); foamy cells in bone marrow; high angiotensin-converting enzyme, tartrate-resistant acid phosphatase, chitotriosidase; thrombocytopenia	GBA
<b>Mitochondrial disorders</b>		
Mitochondrial DNA depletion syndrome	Hypoglycemia; lactic acidosis; high plasma alpha-fetoprotein; hyperferritinemia iron overload; coagulopathy; abnormal urine organic acid	POLG, DGUOK, MPV17
SUCLG1, C10ORF2, elongation factor G1, TRMU related and BCS1L deficiency	Hypoglycemia; lactic acidosis; abnormal urine organic acid	SUCLG1, C10ORF2, EGF1, TRMU, BCS1L
<b>Mitochondrial Fatty Acid Oxidation defects</b>		
LCHAD/MTP deficiency*	Hypoketotic hypoglycemia; high levels of CPK; abnormal blood acylcarnitine and urine organic acids profiles	HADHA, HADHB
<b>Peroxisomal disorders</b>		
Zellweger spectrum disorders	Elevated very long-chain fatty (VLCFA), phytanic and pristanic acids in plasma; reduced plasmalogenes in erythrocytes and fibroblasts; reduced catalase activity in fibroblasts	PEX genes

(continued on next page)

Table 1 (continued)

Disease	Laboratory hallmarks and biomarkers	Gene
<b>Aminoacidopathies</b>		
Tyrosinemia type 1*	Elevated succinylacetone (dry blood spot, plasma, urine); elevated tyrosine and methionine (dry blood spot, plasma); elevated AFP; coagulopathy; hypophosphatemia; hypoglycemia; hyperaminoaciduria; elevated delta-aminolevulinic acid urine	FAH
Adenosine kinase deficiency *	Hypoglycemia (hyperinsulinemic); elevation (intermittent) of methionine in plasma; coagulopathy; elevated adenosine in dry blood spot and urine (transient)	ADK
S-adenosylhomocysteine hydrolase deficiency*	Elevated methionine, S-adenosyl-homocysteine, S-adenosyl-methionine and homocysteine in plasma; high levels of CPK	AHCY
<b>Inborn error of polyols and pentose metabolism</b>		
Transaldolase deficiency	Coagulopathy; anemia and thrombocytopenia; hypothyroidism; renal tubulopathy; abnormal profile of urinary polyols	TALDO1
<b>Carbohydrate metabolism defects</b>		
Classic galactosemia*	Elevated galactose (dry blood spot, erythrocytes); reduced GALT activity in erythrocytes; coagulopathy; hypoglycemia; renal tubulopathy; neonatal <i>E. Coli</i> sepsis; positive urinary reducing substances	GALT
Glycogen storage disease type IV	Fasting hypoglycemia; high levels of CPK; PAS positive inclusions at liver and muscle histology; reduced enzyme activity (liver tissue, muscle, leukocytes, fibroblasts)	GBE1
Congenital disorders of glycosylation	Low coagulation factors (VII, IX, X, XI, AT-III, protein C and S); abnormal serum transferrin isoforms	different genes
<b>Urea cycle defects</b>		
Urea cycle defects*	Hyperammonemia; abnormal aminoacid profile in plasma; elevated orotic acid in urine	OTC, ASS, ASL, ARG
Citrin deficiency (NICCD)	Elevated citrulline (dry blood spot; plasma); elevated galactose and AFP; hypoglycemia; hyperammonemia	SLC25A13
<b>Cholesterol metabolism disorders</b>		
Smith-Lemli-Opitz syndrome	Elevated 7-dehydrocholesterol and 8-dehydrocholesterol in plasma	DHCR7
Mevalonic aciduria	Anemia and thrombocytopenia; hyper-Ig D; abnormal organic urine acids	MVK
<b>Cellular trafficking abnormalities</b>		
NBAS deficiency	Hypoglycemia; lactic acidosis; coagulopathy, abnormal urine organic acid	NBAS
CALFAN syndrome	Low GGT	SCYL1
<b>Metal metabolism disorder</b>		
MEDNIK syndrome	Low serum copper and ceruloplasmin; high urinary copper; mild elevation of plasma VLCFA	AP1S1
<b>Syndromic cholestasis (most relevant)</b>		
Down and Edwards Syndrome	Abnormal karyotype	Trisomy 21, 18
Kabuki syndrome	Low or high GGT	KMT2D, KDM6A, MLL2
Noonan syndrome	High GGT	PTPN11, SOS1, RAF1 and KRAS
Aagenaes syndrome	High GGT	LSC1, CCBE1
<b>ENDOCRINOLOGIC DISEASES</b>		
Thyroid disorders	TSH and FT4 values	different genes. in congenital hypothyroidism (e.g., FOXE1, NKX2-1/5, PAX8, SLC26A4, TSHR)
Panhypopituitarism	TSH and FT4, ACTH, cortisol, GH, IGF1, PRL, LH, FSH, stimulating test, brain MRI	different genes in genetic forms (e.g., HESX1, PROP1, POUF1, LHX3, LHX4, GLI2, SOX3)
Adrenal insufficiency	ACTH, cortisol stimulating test	monogenic forms (e.g., POR, MC2R, MRAP, StAR, AYP11A1, NNT, TRXR2) syndromic forms (eg.CDKN1C, MCM4, SAMD9, SGPL1)
<b>INFECTIOUS DISORDERS</b>		
Cytomegalovirus, Herpes virus type 1–2–6; toxoplasma; rubella; parvovirus B19; enterovirus (including coxsackievirus, echovirus), adenovirus, syphilis, HIV, listeria monocitogenes, congenital tuberculosis	Low or high GGT, serology in the proband and mother, specific direct nucleic acid testing via PCR	NA
<b>HEMATOLOGIC AND IMMUNE-MEDIATED DISORDERS</b>		

(continued on next page)

Table 1 (continued)

Disease	Laboratory hallmarks and biomarkers	Gene
Hemophagocitic lymphoistiocytosis	HLH clinical and testing criteria (cytopenia, hypertriglyceridemia or hypofibrinogenemia, hemophagocytosis in biopsy samples, low or absent NK activity, high serum ferritin, elevated CD25 levels)	<i>different genes (e.g., PRF1, UNC13D, STX11, STXBP2, RAB 27, XLP)</i>
Neonatal hemochromatosis (GALD and non-GALD)	Hypoglycemia, coagulopathy, high ferritin, high alpha-fetoprotein, low transferrin and high iron saturations	<i>non-GALD (e.g., DGUOK, SRD5B1, BCS1L)</i>
Congenital lupus	ANA, positive Coombs-test	NA
Post-hemolytic cholestasis	Hemolytic disease of the newborn due to Rh or ABO alloimmunization	NA
<b>TOXIC AND SECONDARY CHOLESTASIS</b>		
Parenteral nutrition associated cholestasis (PNALD); drugs; intestinal obstruction; cardiovascular disorders, neoplastic disorders; perinatal asphyxia	Low or High GGT	NA

\* detectable by extended newborn screening, where available. A1AT,  $\alpha$ -1-antitrypsin; PFIC, progressive familial intrahepatic cholestasis; sBA, serum bile acids; GGT,  $\gamma$ -glutamyl-transpeptidase; AFP,  $\alpha$ -fetoprotein; ARC, Arthrogyrosis renal dysfunction cholestasis; CDG, congenital disorders of glycosylation; CPK, creatine-phosphokinase; GALT, Galactose-1-Phosphate Uridyltransferase; PAS, Periodic acid-Schiff; ATIII, Antithrombin; NICCD, Neonatal intrahepatic cholestasis caused by citrin; NBAS, neuroblastoma amplified sequence; CALFAN, low  $\gamma$ -glutamyl-transferase cholestasis, acute liver failure, and neurodegeneration; MEDNIK, Mental retardation, Enteropathy, Deafness, Neuropathy, Ichthyosis, Keratoderma; LCHAD/MTP, long-chain 3-hydroxyacyl-CoA dehydrogenase/ mitochondrial trifunctional protein; VLCFA, very-long-chain fatty acid; TSH, thyroid-stimulating hormone; FT4, free tetraiodothyroxine; ACTH, adrenocorticotropic hormone; GH, growth hormone; IGF-1, insulin-like growth factor 1; PRL, prolactin; FSH, follicle-stimulating hormone; LH, luteinizing hormone; MRI, magnetic resonance imaging; PCR, Polymerase chain reaction; GALD, Gestational alloimmune liver disease; ANA, anti-nucleus antibodies; PNALD, Parenteral nutrition associated cholestasis.

## 7. Diagnostic work-up of biliary atresia

Children with BA are candidate for Kasai hepatoportoenterostomy (HPE) with the aim of restoring bile flow, clearing the jaundice, and preserving liver function [11]. The importance of an early diagnosis and/or referral is justified by the fact that the patient should be proposed for surgical exploration early in life, as the success rate of surgery decreases with the age of the child at the operation [3]. Early suspicion of BA is necessary to allow a timely diagnostic work-up aiming to exclude other causes of neonatal cholestasis and to collect clinical, laboratory and non-invasive imaging elements in favor of the diagnosis of BA. Since there is no a single test or procedure to establish a positive diagnosis, a number of concordant elements contribute to establish a well-founded suspicion ultimately setting the indication for performing a cholangiography [30–32]. An effective work-up protocol should select patients for cholangiography within one week with the minimum number of invasive procedures.

Clinical examination and laboratory results can suggest the diagnosis; in the last decade the diagnostic potential of fasting abdominal ultrasonography (US) was extensively investigated and a combination of US signs can offer an extremely high positive predictive power [33–35]. Liver biopsy can be of great value in ruling in or out BA; however, the only procedure to definitely establish the diagnosis is the cholangiography and/or surgical exploration (usually performed together), which represents the gold standard for the diagnosis of BA [36,37].

The time to referral to an expert team for the assessment is a cornerstone problem, as the mean age at referral in most countries has remained as high as 6 weeks and a minority of children with BA undergoes HPE under 60 days of age [38]. Thus, timing and accuracy of the diagnostic work-up are essential, as the surgical exploration should be ideally proposed only to patient with a high index of suspicion – thereby avoiding unnecessary laparotomy in those who are not BA.

Infrequently, the clinical presentation may be atypical exacerbating the challenge of a positive diagnosis in an adequate time. Some children may present with hypocholic stools, a complex neonatal clinical history and not specific findings at laboratory tests or even at liver biopsy, and are not immediately proposed for cholangiography. In the case of persisting cholestasis, the pedi-

atrician should not hesitate to reassess a child shortly later if the first work-up did achieved a certain diagnosis, as the clinical picture may evolve rapidly in case of BA [39,40].

As a future direction, the serum matrix metalloproteinase-7 (MMP-7) has recently emerged as a promising standalone non-invasive marker of BA, bearing a sensitivity of 95–98% and a specificity of 83–95% [41–44]. The lack of standardized collection and dilution protocols, and – subsequently – of clear cut-offs, have limited so far its large-scale validation and clinical use.

Children with initially cholic stools, and evolution towards acholic stools between the age of 2 to 4 months have been described [45]. To what extent these cases represent a misclassification of the newborn's stool color or they are late forms of BA, is controversial. However, the diagnosis of BA should not be definitely excluded on the basis of the presence of normal stools in the early neonatal period.

## 8. Initial evaluation

### 8.1. Medical history

Familial and personal medical details should be collected in children with prolonged jaundice and especially in those in which NIC has been already demonstrated [1,2,46]. Details in the family history including previous and current pregnancy and information on miscarriages, pruritus or liver disease, hemolytic diseases and/or cardiac anomalies in maternal history or other family members should be noted. Detailed medical history can highlight some clues important to the final diagnosis [1,47,48]. Gestational and perinatal history are crucial in defining factors associated with some forms of multifactorial, transient cholestasis, such as low birth weight and prematurity, a low Apgar score, sepsis, asphyxia, total parenteral nutrition, history of organ failure [1,49]. Genetic-metabolic causes or congenital infection should be considered in the differential diagnosis in presence of intrauterine growth retardation, fetal hydrops with or without malformations [47].

Red flags suggesting IEM as the cause of the liver disease include suggestive family history, early-onset (or triggered by intercurrent illnesses) episodes of acute metabolic decompensation

**Table 2**  
Clinical findings in the physical examination of a newborn or infant with cholestatic jaundice.

Assessment of general health	Ill appearance may indicate infection or metabolic disease; infants with biliary atresia typically appear in good general and nutritional conditions; severe pruritus (biliary canalicular transport, development and tight junction defects)
Stool and urine observation	Acholic stools, totally decolored with clay-like aspect, are the strongest argument to suspect a biliary obstructive disease such as BA; colored urine are strongest suggestive of cholestasis
General appearance	Dysmorphic features: e.g., Alagille syndrome (rarely exhibits characteristic facial anomalies before age 6 months), Zellweger spectrum disorders, Smith-Lemli-Opitz, ARC syndrome, syndromic cholestasis
Vision/slit lamp examination	Posterior embryotoxon (Alagille syndrome), cataract (galactosemia, Zellweger spectrum disorders, lysosomal storage disorders, congenital infections), cherry red spot (lysosomal storage disorders); rotatory eye movement (DGUOK deficiency)
Hearing	Hear loss (e.g., congenital infections, Zellweger spectrum disorders, other IEM, CDG)
Cardiac examination	Murmur/congenital cardiac malformations (Alagille Syndrome, biliary atresia with splenic malformation syndrome); situs inversus (biliary atresia) cardiomyopathy (mitochondrial disorders, fatty acid oxidation defects, glycogen storage diseases)
Abdominal examination	Presence of ascites, abdominal wall visible veins, liver size and consistency, spleen size (splenomegaly suggests Niemann-Pick and Gaucher diseases), abdominal mass, umbilical hernia, cystic kidneys (ciliopathies, Zellweger spectrum disorders)
Neurologic evaluation	Note overall vigor and tone (severe hypotonia suggests peroxisomal disorders or mitochondrial cytopathies), lethargy, poor feeding (several IEM, CDG)
Skin evaluation	Ichthyosis/collodion baby (ARC syndrome, MEDNIK, Gaucher, congenital disorders of glycosylation), laxity (CDG, transaldolase deficiency), rash (mevalonic aciduria)
Genitalia	Micropenis (hypofisarian dysfunction), ambiguous genitalia (e.g., Smith-Lemli-Opitz)

BA, serum bile acids; ARC, Arthrogyrposis, renal dysfunction, cholestasis; CDG, Congenital disorders of glycosylation; IEM, inborn errors of metabolism; MEDNIK: Mental retardation, Enteropathy, Deafness, Neuropathy, Ichthyosis, Keratoderma.

(e.g. hypoglycemia, hyperammonemia, acidosis, acute liver failure/involvement), recurrent/chronic vomiting, selective food aversion, unusual odor of body fluids, associated neurological signs or multi-organ involvement [50].

Careful information about the onset of jaundice, changes in stool pigmentation and urine color must be collected [1,51].

#### Recommendation

- In jaundiced infants with suspected or confirmed cholestasis a detailed pre-, peri-, and postnatal medical and family history should be collected (GRADE 1B; 100% agree).

### 8.2. Physical examination

Typically, the infant with BA is born at term and has been feeding nicely since birth until the jaundice is recognized as a pathologic condition [52]. Less frequently, the suspicion of BA may be evoked in a premature baby because of a rising level of direct bilirubin in presence of acholic stools; in these small babies, jaundice can be multifactorial and the diagnostic work-up may even be more difficult than usual. The most important element in physical examination is the direct observation of stools color and a careful abdominal inspection looking at hepatomegaly and/or splenomegaly. Acholic stools, totally decolored with clay-like aspect (<https://www.atresiabiliare.org/guida-fotografica-sulla-cacca-del-bambino/>) are the strongest argument to suspect a biliary obstructive disease but can be observed in only a few other diseases, notably Alagille syndrome (AGS), alpha-1-antitrypsin deficiency (A1ATD), and cystic fibrosis. Hypocholic (light yellowish) stools are not specific of any disease and can be found in late onset BA cases as a transition period towards acholic stools (during the second month of life). However, either parents nor youth healthcare doctors nor general practitioners seems to reliably recognize discolored stool [53].

Although the association of acholic stools and dark urine is very typical of BA, the observation of dark urine is per se not specific, as it is present in any cholestatic disease.

The clinical observation of a firm hepatomegaly with or without splenomegaly in a jaundiced infant is the other most relevant clinical finding in BA infants [31]. However, because splenomegaly in BA is secondary to the development of portal hypertension, it may be less pronounced in very young infants or in late onset BA

cases; massive splenomegaly is rather suggestive of lysosomal storage diseases or hematological conditions.

An exhaustive physical examination in any infant with cholestasis has great importance because it may reveal hallmarks of other diseases - as for example, a systolic murmur audible from the back in Alagille syndrome (AGS) (peripheral pulmonary artery stenosis). Clinical findings suggestive of specific causes of NIC are listed in Table 2.

#### Recommendations

- Infants with jaundice should receive a complete physical examination in particular searching for the presence of hepatomegaly and/or splenomegaly, dysmorphic features, growth and nutritional status, skin lesions, cardiac murmurs and neurologic examination (GRADE 1A, 100% agree).
- Direct visualization of stools color and its monitoring should be part of the clinical evaluation of any infant with jaundice (GRADE 1A, 100% agree).

### 8.3. Laboratory investigations

Laboratory is essential in confirming the suspicion of a cholestatic jaundice, estimating the presence and the proportion of conjugated bilirubin. Specific measurements of conjugated bilirubin are optimal if available. However, the most commonly used laboratory determination, the diazo or van den Bergh method, does not specifically measure conjugated bilirubin but reports direct reacting bilirubin (entailing free and albumin-bound conjugated bilirubin) [54]. The measurement of direct bilirubin with standard methods is accurate in identifying children with BA also when performed shortly after birth, and recent studies demonstrated its feasibility and cost-effectiveness as a newborn screening [55–58].

#### Recommendations

- Infants with jaundice persisting after 2 weeks of age should be evaluated for cholestasis by measurements of serum total and direct-reacting (conjugated) bilirubin (GRADE 1A, 97% agree).
- Conjugated bilirubin >1 mg/dL (17 mmol/L) if total bilirubin is <5 mg/dL, or >20% if total bilirubin is >5 mg/dL, is considered diagnostic of cholestasis and warrants further evaluation (GRADE 1A, 100% agree).

Table 3

First- and second-tier investigations in newborn and infants with cholestasis.

TIER 1: Investigations to evaluate the severity of the liver involvement and first line work-up	Comment
Total and conjugated bilirubin, ALT and AST, alkaline phosphatase, GGT, total protein and albumin, INR/PT and aPTT	To define the severity of liver involvement
WBC + differential	To suspect the presence of infection and metabolic disease
Serum bile acids	Usually elevate in cholestasis, low levels suggestive of BASD (according to upper limit of normal value for age)
TSH and T4 values, ACTH, cortisol	Screen for congenital hypothyroidism, adrenal insufficiency and hypopituitarism
Urine: urine analysis, culture	To rule out infection
Glucose, electrolytes, blood gas analysis with evaluation of bicarbonate and lactate, ammonium	First level screening for metabolic diseases
CPK, BUN, creatine, Ca/P, AFP*, lipid profile (C, C-LDL, C-HDL, triglycerides)	To analyze systemic involvement and suspect the presence of a metabolic conditions; high levels of C in Alagille syndrome
Sweat chloride analysis (trypsinogen level and CFTR genetic testing if appropriate)	To diagnose CF where newborn screening is not available
$\alpha$ -1-antitrypsin level, $\alpha$ -1-antitrypsin phenotype (where available)	To screen for $\alpha$ -1-antitrypsin deficiency
Serum iron, ferritin and transferrin	If high, suspicion of GALD and HLH
Bacterial cultures of blood and other fluids if clinically ill infant	To rule out infections
Serology (IgG and IgM) for infections in the propositus and mother	To diagnose antenatal/perinatal infections
Abdominal ultrasound	To detect presence of ascites, to explore extrahepatic biliary tree, adrenal calcification (Wolman), renal cysts (ciliopathies, Zellweger), hepato-splenomegaly (lysosomal storage disorders), liver echogenicity
Echocardiogram	To find congenital heart defects or cardiomyopathy (mitochondrial disorders, fatty acid oxidation defects)
Eye visit, FO and slit lamp examination	To detect ocular involvement (hallmarks of perinatal infections, genetic and metabolic disorders)
<b>TIER 2: Second-line work-up</b>	<b>Comment</b>
GH, IGF1, PRL, LH, FSH	To rule out panhypopituitarism
Vitamin A, D, E	To detect fat-soluble vitamins depletion
Infective work-up (specific direct nucleic acid testing via PCR)	As suggested by serology and clinical findings
Selected metabolic work-up (driven by first line clinical and laboratory evaluation)	Amino acids (P), acylcarnitine (DBS, P), organic acids (U), orotic acid (U), succinylacetone (DBS, P,U), galactose (DBS), VLCFA (P), sialotransferrins (S), oxysterols (P), 7-dehydrocholesterol (P), lysoshingolipids (P), bile acids (DBS/S/U), cholestanol (P), polyols (U), lysosomal enzymes (DBS/WBC/F), GALT activity (DBS/RBC), mitochondrial enzymes (M/F)
$\alpha$ -1-antitrypsin genotype	To diagnose $\alpha$ -1-antitrypsin deficiency
Genetic testing	Karyotype, array-CGH, targeted gene panels, WES, WGS
Skeletal X-ray	Spinal abnormalities (such as butterfly vertebrae Alagille), bone dysplasia (lysosomal storage disorders), punctate calcification (Zellweger and peroxisomal disorders), signs of congenital infections, arthrogryposis (ARC syndrome)
Bone marrow aspiration	Storage cells suspecting a lysosomal storage disease; hematological/infiltrative conditions (e.g., HLH)
EEG, cerebral ultrasound, brain MRI, evoked potentials	Neurological impairment
Liver Biopsy	See paragraph
MRI cholangiogram/scintigraphy/ERCP	See paragraph

AST, aspartate aminotransferase; ALT, alanine aminotransferase; GGT,  $\gamma$ -glutamyl-transpeptidase; INR, international normalized ratio; PT, prothrombin time; aPTT, activated partial thromboplastin time; WBC, white blood cells; TSH, thyroid-stimulating hormone; FT4, thyroxine; CPK, creatine-phosphokinase; BUN, Blood Urea Nitrogen; BASD, Bile acid synthesis defects; CF, Cystic Fibrosis; FO, fundus oculi; ACTH, adrenocorticotropic hormone; GH, growth hormone; IGF-1, insulin-like growth factor 1; PRL, prolactin; FSH, follicle-stimulating hormone; LH, luteinizing hormone; PCR, Polymerase chain reaction; WES, whole-exome sequencing; WGS, whole-genome sequencing; ARC, Arthrogryposis renal dysfunction cholestasis; P, plasma; S, serum; DBS, dried blood spot; U, urine; RBC, red blood cells; F, fibroblasts; M, muscle; GALD, gestational alloimmune liver disease; EEG, Electroencephalogram; MRI, Magnetic resonance imaging; ERCP, Endoscopic Retrograde Cholangiopancreatography; HLH, hemophagocytic lymphohistiocytosis.

#### 8.4. Further investigations

Table 3 displays a targeted investigation protocol for infantile cholestasis. First-level laboratory tests represent the initial work-up to evaluate type and severity of liver involvement. In some cases, these tests point to a specific diagnosis or rule out confounding clinical pictures, such as alpha-1-antitrypsin deficiency that can present with neonatal hepatitis syndrome mimicking BA [59]. Also, some conditions such as Alagille syndrome and cystic fibrosis are reported causes of false positive intraoperative cholan-

giogram, and should be excluded before surgical exploration, as a mistakenly performed HPE may worsen their condition [60–62]. After exclusion of BA, second-line investigations aim at identifying other disorders responsible for non-obstructive (intrahepatic) causes of cholestasis.

A biochemical crossroad in the evaluation of NIC is the serum gamma-glutamyl transpeptidase (GGT) concentration. GGT is typically markedly increased in BA, in fact high levels (> 200 IU/L) in presence of acholic stools strongly suggest BA, although this finding is not specific to this condition [52,63]. Notably, in a large ret-



respective cohort, GGT values higher than 500 IU/L were found only in BA patients [64]. Conversely, a normal GGT level may suggest a poor prognosis [65] as in progressive intrahepatic familial cholestasis type 1 and 2 and other inborn defects of canalicular transport or synthesis of bile acids [63].

Elevated (above 7  $\mu\text{mol/L}$ ) total serum bile acids can be considered a very sensitive biomarker of cholestasis. However, slight elevations may reflect physiologic bilirubin metabolism immaturity in infants under 6 months of age, while their concentration may be low/normal in bile acid synthesis defects [66,67].

#### Recommendation

- In cholestatic infants, alpha-1-antitrypsin deficiency, Alagille syndrome, and cystic fibrosis must be ruled out by specific tests before any invasive diagnostic procedure, since these diseases may mimic biliary atresia (GRADE 1 B, 100% agree).

### 8.5. Metabolic workup for inborn errors of metabolism presenting with NIC

IEM causing infantile cholestasis include a wide and heterogeneous group of diseases. In some disorders the liver is the only affected organ, while others present NIC in the context of a multi-system disease. The orientation of second level laboratory tests requires a careful evaluation of the clinical picture and of first-level laboratory analyses.

Recently, expanded newborn screening (NBS) may identify some treatable IEM causing NIC. Depending on the different screening panels, the following disorders can be detected at birth: tyrosinemia type 1, galactosemia, urea cycle disorders [e.g., citrullinemia type I and II (citrin deficiency), argininosuccinate lyase and arginase deficiencies], long-chain fatty acid oxidation disorders (e.g., CPT I, LCHAD/MTP, MAD deficiencies). All disorders identified by NBS should be confirmed by biochemical and molecular analysis [47,50]. However, confounding NBS results may occur in preterm infants and in those on prolonged parenteral nutrition.

The red flags suggesting an IEM as the underlying cause of NIC are listed in Table 4. Second-level laboratory testing and/or genetic testing should be then performed based on the diagnostic suspicion.

The diagnosis of an IEM causing NIC may allow the identification of treatable disorders, provides the clues for genetic counselling and should alert clinicians on potentially associated risk of liver failure, acute metabolic events and of a multi-organ/multisystem involvement.

#### Recommendation

- In infants with cholestasis, inborn errors of metabolism (IEM) should always be considered in the differential diagnosis (GRADE 1A, 100% agree).
- Clinicians should be aware of which IEM causing cholestasis is included in the expanded newborn screening of their own region/country (GRADE 1A, 100% agree).
- A careful clinical evaluation, combined with first-level laboratory testing, may arise the suspicion of specific IEM, indicating second level laboratory analyses for confirmatory diagnosis (GRADE 1 C, 100% agree).

## 9. Imaging

### 9.1. Liver ultrasound

Abdominal ultrasound is helpful in evaluating cholestatic infant, particularly to look for signs of BA and other biliary obstructive diseases. A 4-hour fasting abdominal ultrasound is the

first-line diagnostic imaging technique to assess several hepatic sonographic parameters because it is noninvasive, easily available, painless, safe and without need for sedation. The main goal of the ultrasound in cholestatic infants is to exclude other anatomic causes of cholestasis, such as a choledochal cyst or complicated gallstone disease. The triangular cord sign, abnormal gallbladder length and contractility index, gallbladder ghost triad, non-visualization of the common bile duct, hepatic artery diameter, hepatic artery to portal vein diameter ratio, hepatic subcapsular blood flow, and splenic, portal vein and/or inferior vena cava abnormalities have been considered ultrasound findings suggestive of BA. However, none by itself can confirm the diagnosis, and their detection and interpretation imply substantial radiological expertise [68]. In particular, findings such as laterality anomalies, midline liver, polysplenia, asplenia, absence of inferior vena cava and preduodenal portal vein raise the suspicion of BASM [69].

A recent meta-analysis showed ultrasound pooled sensitivity of 77% and specificity of 93% for the diagnosis of BA, with a positive predictive value of 88.6% and a negative predictive value of 85.3% [70]. Another meta-analysis showed that a combination of the triangular cord sign and an abnormal gallbladder yielded a sensitivity of 95% and specificity of 89%; therefore, these are considered the two most accurate ultrasound findings used for the diagnosis or exclusion of BA [71].

However, clinicians should remember that a normal ultrasonography, does not rule out non-syndromic BA. Shear Wave Elastography and transient elastography appear to help discriminate BA from other causes of NIC, but they still are not routinely performed [72,73].

#### Recommendation

- Infants with cholestasis should undergo liver ultrasound to exclude biliary obstructive conditions other than biliary atresia, such as choledochal malformations or gallstone disease (GRADE 1A, 100% agree).
- Ancillary findings such as the absence of the gallbladder or its dysmorphic aspect, along with other minor features suggestive of biliary atresia, should always be searched at liver ultrasound (GRADE 1 A, 100% agree).

### 9.2. Other imaging

#### 9.2.1. Hepatobiliary scintigraphy

Used in the past to assess biliary tract patency, the hepatobiliary scintigraphy (HBS) is not anymore part of standard work-up, because of its low specificity and positive predictive value [74]. Falsely positive results are seen in non-obstructive bile flow alteration (non-BA severe cholestasis). On the contrary, a normal bile passage in the intestine has nearly 100% negative predictive value for BA, but since these children generally also have colored stools, HBS seems not to add much to a thorough clinical examination [75,76]. In no case the HBS should delay the referral of a child with suspect BA to a center with experience in pediatric hepatology.

#### 9.2.2. Cholangiogram

The lack of visualization of the bile ductal system is the cornerstone in the diagnosis of BA. Direct or indirect biliary tract imaging essentially distinguishes between BA from all other non-BA cholestasis. However, in low-weight infants, a normal biliary system is not visible on standard imaging, thus making definite identification of BA very challenging. All the cholangiographic techniques may give false positive results (e.g., in AGS or in cystic fibrosis) due to marked ductal hypoplasia.

Direct cholangiography is obtained through different approaches:

**Table 4**  
"Red flags" for inborn error of metabolism in cholestatic infant.

Red flags	Disorders
Hyperammonemia, lethargy/coma, feeding difficulties	Urea cycle disorders
Cataract, hypoglycemia, coagulopathy, E.Coli sepsis	Galactosemia
Hypoglycemia, hepatomegaly	Disorders of carbohydrate metabolism, mitochondrial disorders, adenosine kinase deficiency
Early nodular liver lesions, high $\alpha$ -fetoprotein, coagulopathy, renal tubular dysfunction	Tyrosinemia type 1
Hepato-splenomegaly, neurologic involvement, cherry red spot, non-immune fetal hydrops	Lysosomal storage disorders
Selective coagulation factor deficiency (factor VII, IX, X, XI, AT3, protein C/S), neurological and systemic signs	Congenital disorders of glycosylation (CDG)
Lactic acidosis, neurological signs, cardiomyopathy	Mitochondrial disorder
Rotatory eye movements, hypoglycemia, coagulopathy, elevated blood lactate, hyperferritinemia	Mitochondrial DNA depletion syndrome (DGUOK)
Adrenal calcification, hepatosplenomegaly, failure to thrive, macrophage activation syndrome	Wolman disease (LAL deficiency)
Hypotonia, wide anterior fontanel, cataract, renal cysts	Zellweger spectrum disorders
Chronic diarrhea	Bile acid synthesis and conjugation disorders, PFIC 1
Hypoketotic hypoglycemia, cardiomyopathy, maternal HELPP, rhabdomyolysis	Fatty acid oxidation defects (e.g., LCHAD/MTP)
Renal tubular dysfunction	Tyrosinemia, mitochondrial disorders, transaldolase deficiency, galactosemia, ARC syndrome
Polydactily/Syndactily, ambiguous genitalia, micrognathia	Smith-Lemli-Opitz syndrome
Non immune fetal hydrops	Lysosomal storage disorders, Smith-Lemli-Opitz, mevalonic aciduria, congenital disorders of glycosylation (CDG), peroxisomal disorders, mitochondrial disorders
Acute liver failure	Tyrosinemia type 1, galactosemia, mitochondrial disorders, urea cycle disorders, CDG, NBAS deficiency, CALFAN syndrome, adenosine kinase deficiency, Transaldolase deficiency, fatty acid oxidation defects, mevalonic aciduria, Wolman disease

AT3, Antithrombin; LAL, Lysosomal acid lipase; PFIC, progressive familial intrahepatic cholestasis; HELPP, hemolysis, elevated liver enzyme levels, and low platelet levels; LCHAD/MTP, long-chain 3-hydroxyacyl-CoA dehydrogenase/ mitochondrial trifunctional protein; ARC, Arthrogyroposis renal dysfunction cholestasis; CDG, congenital disorders of glycosylation; CDG, congenital disorders of glycosylation; NBAS, neuroblastoma amplified sequence; CALFAN, low  $\gamma$ -glutamyl-transferase cholestasis, acute liver failure, and neurodegeneration.

- **Surgical direct cholangiography (intraoperative cholangiography, IOC):** IOC allows a direct opacification of the biliary tree, and is performed as the second step of a laparoscopic or open surgical assessment (after abdominal and liver macroscopic evaluation). IOC is currently the gold standard to diagnose BA, and it allows to perform a HPE at the same time [77,78].
- **Endoscopic Retrograde Cholangio-Pancreatography (ERCP)** has been shown to be a possible alternative to intra-operative cholangiogram, with similar diagnostic accuracy. However, the limited availability on the market of pediatric ERCP equipment and the lack of experienced endoscopists in this field limit the utility of this approach to selected centers [79].
- **Percutaneous cholangiography (PC):** direct cholangiography by percutaneous transhepatic puncture of an intrahepatic bile duct is only feasible in patients with dilated intrahepatic bile ducts and it is rarely proposed in NIC. Alternatively, a PC can be carried out in some patients through gallbladder puncture (cholecystography). This is the case of suspected BA with patent gallbladder, such as type 1. Overall, that approach can be used in selected jaundiced babies with cholestasis and absence of dilatation of the biliary system but a normal gallbladder.

**Magnetic Resonance Cholangio-Pancreatography (MRCP)** is not reliable as the normal biliary tract is not consistently visualized in children under 3 months of age; false negative results are thus common.

#### Recommendations

- **Surgical exploration and direct evaluation of biliary tract by cholangiogram is considered the gold standard to positively and definitively establish the diagnosis of biliary atresia and neonatal sclerosing cholangitis (GRADE 1A, 82% agree).**
- **Hepatobiliary scintigraphy and magnetic resonance cholangio-pancreatography should not be used as a single test in the diagnosis of BA due to their scarce specificity (GRADE 1B, 100% agree).**

## 10. Histology

Liver biopsy often remains the cornerstone of the diagnostic work-up of infants with cholestatic jaundice as interpretation by an experienced pathologist will provide the correct diagnosis in 90% to 95% of cases, avoiding unnecessary surgery in patients with intrahepatic disease [80]. In addition to its diagnostic role, the liver biopsy may also reveal histologic features of significant prognostic value, such as the estimated degree of fibrosis, which may help predict outcome following HPE and the decision to proceed with HPE. Accuracy depends on several factors, especially on the adequacy of the specimen and on the patient's age.

Paraffin-embedded liver biopsies are routinely stained with hematoxylin and eosin, periodic acid-Schiff (PAS), PAS after diastase and Masson trichrome stain. Adequacy in size and number of portal tracts, as well as size and shape of portal bile ductules should be reported.

The main role of histology in the investigation of NIC is to distinguish between intrahepatic and extrahepatic (biliary obstructive, essentially BA) causes, ultimately allowing timely surgery for

infants with BA. Intrahepatic cholestasis could be further distinguished between cholestatic conditions caused by a disturbance located at the level of the liver cell or canaliculus (*intrahepatic cholestasis*) and pathological states where the primary lesion is thought to operate the intrahepatic biliary passage (*extrahepatic cholestasis*) [81].

Ductal/ductular bile plugs, generalized moderate to marked ductular reaction and bile duct proliferation, portal stromal edema, higher stages of portal fibrosis, prominent pseudorosette formation, moderate to marked peribiliary neutrophilic infiltrates, and interlobular bile duct injury are acknowledged markers of biliary obstructive cholestasis, such as BA. Conversely, bile duct paucity, predominant giant cell transformation, macrovesicular steatosis, and extramedullary hematopoiesis are commonly associated with non-obstructive causes [82].

Parenteral nutrition-associated cholestasis, cystic fibrosis and alpha-1-antitrypsin deficiency may show variable ductular reaction and may be impossible to distinguish from BA without clinical data.

However, early histological changes of BA may be relatively nonspecific, and biopsies performed too early in life may result in a falsely negative diagnosis [83]. Moreover, although ultrasound-guided percutaneous core liver biopsy is generally considered to be a safe and effective procedure, complications are reported in 1.7 to 4.6% of infants [84].

For the above-mentioned reasons, the decision as to whether and when a liver biopsy should be performed has to be taken on a case-by-case basis by experienced pediatric hepatologists, also considering the local pathology expertise.

#### Recommendations

- Liver biopsy is useful to discriminate between extrahepatic and intrahepatic causes of NIC and may provide important clues for specific underlying etiologies, when performed at the appropriate timing and evaluated by an experienced pathologist (GRADE 2C; 100% agree).
- Percutaneous liver biopsy should not be performed when histology is not expected to add substantial information on the etiology of NIC, the diagnosis of biliary atresia is very likely on clinical and ultrasound findings, and surgical exploration and treatment could be delayed (GRADE 2C; 100% agree).

### 11. Genetic testing

In a child with NIC, once surgical (BA, CM), infectious and secondary causes are ruled out, the picture is most likely related to a monogenic liver disease. Over the last decade, next-generation sequencing (NGS)-based testing strategies have been refined, attaining high-throughput massively parallel sequencing platforms, thus providing simultaneous analysis of a large number of genes [85,86]. NGS is increasingly used in clinical setting with different approaches varying in wideness and analytic complexity, from selected targeted gene panels (TGP) to whole exome sequencing (WES) and whole genome sequencing (WGS) [87]. Their role has been moving upwards in the diagnostic algorithm of NIC, from that of retrieving a genetic diagnosis among patients with indefinite conditions, to a second-tier screening for genetic causes just after having ruled out the “extrahepatic” ones [46].

The overall accuracy of NGS testing for neonatal/infantile cholestasis is poorly known. Considering as positive results the detection of pathogenic or likely pathogenic variants [88] in accordance with Mendelian inheritance, sensitivity and specificity are close to 100% in different reports [89–94]. However, the real-life diagnostic yield largely varies according to study population, design and setting: TGP identified a genetic etiology in 20% to 61% of children with persistent cholestasis [89,92–94], while a tiered

clinically-steered approach with TGP and WES was able to accomplish a genetic diagnosis in 60% of the children [91]. Selection bias accounts for the variability in the diagnostic capacity of such approaches.

Taken together, these results show that NGS is a promising tool to differentiate within different causes of intrahepatic cholestasis, and could be adopted as a second-tier evaluation after the exclusion of etiologies susceptible of rapid surgical or medical treatment, provided that a reasonable turnaround time and sufficient expertise in results' interpretation are warranted, and that quality parameters are met.

Interpretation of genetic results and variant classification should comply with the American College of Medical Genetics and Genomics guidelines [88,95], and confirmation should be obtained by a different method (e.g., Sanger sequencing) using a second independent DNA sample of the parent-proband trio. The wideness of the genetic testing should be adapted to the index of suspicion as defined per clinical, biochemical, instrumental and histologic features.

If NGS sequencing is not diagnostic for an etiology highly suspected on the phenotype, further testing is recommended to detect large deletions, duplications or inversions that can be missed at NGS. In this setting, WGS has proven superior to WES to detect all major classes of variants [96].

#### Recommendations

- NGS-based genetic testing has high diagnostic accuracy in identifying monogenic liver disorders causing NIC (GRADE 1C, 100% agree).
- NGS-based genetic testing should be considered early after exclusion of BA, in parallel with a metabolic work-up, and based on local availability (GRADE 2C, 100% agree).

### 12. Non-invasive diagnostic scores

The clinical differential diagnosis of BA cases from any other causes of neonatal cholestasis can be challenging. Early studies focused on laboratory data [97], in recent years all described clinical, radiological and laboratory signs were combined to obtain a scoring system with enough sensitivity and specificity to allow a positive diagnosis of BA.

These efforts led in recent years to propose several “diagnostic scoring systems” for BA, including histological findings in some [63,98–100]. In the United States a huge multicentric prospective study conducted among the Childhood Liver Disease Research Network (ChILDReN - formerly BARC) failed in this effort of generating an algorithm that could discriminate BA and Non-BA cases, without the need for including the results of invasive procedures [52]. Overall, there are no currently available algorithm that has shown enough accuracy and/or that has been validated in independent pediatric cohorts to avoid a standard work-up.

#### Recommendation

- A positive diagnosis of BA is the result of a combination of clinical elements and different diagnostic tools. Clinical scoring systems for biliary atresia should not replace standard work-up due to the lack of validation in clinical setting (GRADE 1B, 100% agree).

### 13. Cholestasis in neonatal intensive care unit

Neonatal cholestasis is much more frequent in preterm children, and its incidence can be as high as 1:200 in the setting of neonatal intensive care unit [49]. Beside prematurity, other common risk factors are long-term parenteral nutrition, sepsis, delayed enteral intakes, intrauterine growth retardation, asphyxia, surgery, hemodynamic instability, male sex [101]. These conditions, often associ-

ated with higher oxidative stress, represent risk factors for developing transient neonatal cholestasis.

Preventative measures should include the use of adequate caloric intakes and appropriate proportion of fish oil-based lipid emulsions in children requiring parenteral support, the early introduction of enteral feeding, as well as prompt recognition and treatment of infectious comorbidities [102,103].

Although generally self-limiting, in a child with multifactorial transient neonatal cholestasis, other causes should be investigated if direct bilirubin levels > 2 mg/dL persists after 2 weeks to avoid the risk of delaying the diagnosis of an underlying primary liver disease. Time and diagnostic effort should be tailored on the clinical appearance and on the course of cholestasis. Persistent cholestasis in any infant should be considered pathologic and detectable causes of cholestasis, including biliary atresia should be excluded in a timely and appropriate manner. Incidence of biliary atresia or genetic forms of cholestasis is the same in premature as in term infants [1].

## 14. Conclusions

NIC poses a diagnostic challenge for the pediatrician. A delay in referral to the specialist can have a detrimental impact on outcomes. A stepwise approach, aiming at ruling out first diseases with available treatments, is proposed.

The recommendations reported in the present document assist the primary care pediatrician and the neonatologist in recognizing the newborns and infants with cholestasis among those with prolonged jaundice. Secondly, they orient the pediatric gastroenterologist to the rationale use of the available diagnostic repertoire.

SIGENP is not responsible for the practices of physicians and provides guidelines and Position Papers as indicators of best practice only. Diagnosis and treatment are at the discretion of the health care provider.

## References

- [1] Fawaz R, Baumann U, Ekong U, Fischler B, Hadzic N, Mack CL, et al. Guideline for the evaluation of Cholestatic Jaundice in infants: joint recommendations of the North American Society for Pediatric Gastroenterology, Hepatology, and Nutrition and the European Society for Pediatric Gastroenterology, Hepatology, and Nutrition. *J Pediatr Gastroenterol Nutr* 2017;64:154–68. doi:10.1097/MPG.0000000000001334.
- [2] Catzola A, Vajro P. Management options for cholestatic liver disease in children. *Expert Rev Gastroenterol Hepatol* 2017;11:1019–30. doi:10.1080/17474124.2017.1359538.
- [3] Serinet M-O, Wildhaber BE, Broué P, Lachaux A, Sarles J, Jacquemin E, et al. Impact of age at Kasai operation on its results in late childhood and adolescence: a rational basis for biliary atresia screening. *Pediatrics* 2009;123:1280–6. doi:10.1542/peds.2008-1949.
- [4] Gonzales E, Matarazzo L, Franchi-Abella S, Dabadie A, Cohen J, Habes D, et al. Cholic acid for primary bile acid synthesis defects: a life-saving therapy allowing a favorable outcome in adulthood. *Orphanet J Rare Dis* 2018;13:190. doi:10.1186/s13023-018-0920-5.
- [5] Karadag N, Zenciroglu A, Eminoglu FT, Dilli D, Karagol BS, Kundak A, et al. Literature review and outcome of classic galactosemia diagnosed in the neonatal period. *Clin Lab* 2013;59:1139–46. doi:10.7754/clin.lab.2013.121235.
- [6] Moyer V, Freese DK, Whittington PF, Olson AD, Brewer F, Colletti RB, et al. Guideline for the evaluation of Cholestatic Jaundice in infants: recommendations of the North American Society for Pediatric Gastroenterology, Hepatology and Nutrition. *J Pediatr Gastroenterol Nutr* 2004;39:115–28.
- [7] Andrews J, Guyatt G, Oxman AD, Alderson P, Dahm P, Falck-Ytter Y, et al. GRADE guidelines: 14. Going from evidence to recommendations: the significance and presentation of recommendations. *J Clin Epidemiol* 2013;66:719–25. doi:10.1016/j.jclinepi.2012.03.013.
- [8] Andrews JC, Schünemann HJ, Oxman AD, Pottie K, Meerpohl JJ, Coello PA, et al. GRADE guidelines: 15. Going from evidence to recommendation—determinants of a recommendation's direction and strength. *J Clin Epidemiol* 2013;66:726–35. doi:10.1016/j.jclinepi.2013.02.003.
- [9] Porter ML, Dennis BL. *Hyperbilirubinemia in the Term Newborn* 2002:65:8.
- [10] Sanchez-Valle A, Kassira N, Varela VC, Radu SC, Paidas C, Kirby RS. Biliary atresia: epidemiology, genetics, clinical update, and public health perspective. *Adv Pediatr* 2017;64:285–305. doi:10.1016/j.yapd.2017.03.012.
- [11] Hartley JL, Davenport M, Kelly DA. Biliary atresia. *Lancet Lond Engl* 2009;374:1704–13. doi:10.1016/S0140-6736(09)60946-6.
- [12] Wong ZH, Davenport M. What happens after Kasai for Biliary Atresia? A European multicenter survey. *Eur J Pediatr Surg* 2019;29:1–6. doi:10.1055/s-0038-1668146.
- [13] Odièvre M, Valayer J, Razemon-Pinta M, Habib EC, Alagille D. Hepatic portoenterostomy or cholecystostomy in the treatment of extrahepatic biliary atresia. A study of 49 cases. *J Pediatr* 1976;88:774–9. doi:10.1016/s0022-3476(76)81113-4.
- [14] Lilly JR, Stellin G. Catheter decompression of hepatic portocholecystostomy. *J Pediatr Surg* 1982;17:904–5. doi:10.1016/s0022-3468(82)80465-x.
- [15] Chardot C, Buet C, Serinet M-O, Golmard J-L, Lachaux A, Roquelaure B, et al. Improving outcomes of biliary atresia: french national series 1986–2009. *J Hepatol* 2013;58:1209–17. doi:10.1016/j.jhep.2013.01.040.
- [16] Schwarz KB, Haber BH, Rosenthal P, Mack CL, Moore J, Bove K, et al. Extrahepatic anomalies in infants with biliary atresia: results of a large prospective North American multicenter study. *Hepatol Baltim Md* 2013;58:1724–31. doi:10.1002/hep.26512.
- [17] Hamada Y, Ando H, Kamisawa T, Itoi T, Urushihara N, Koshinaga T, et al. Diagnostic criteria for congenital biliary dilatation 2015. *J Hepato-Biliary-Pancreat Sci* 2016;23:342–6. doi:10.1002/jhbp.346.
- [18] Parolini F, Davenport M. Choledochal malformation: terminology and aetiology. *Pediatr Surg Int* 2018;34:117–18. doi:10.1007/s00383-017-4203-3.
- [19] Kato T. Etiological relationships between choledochal cyst and anomalous junction of the pancreaticobiliary ductal system. *Keio J Med* 1989;38:136–51. doi:10.2302/kjm.38.136.
- [20] Weng R, Hu W, Cai S, Guo X, Luo Q. Prenatal diagnosis and prognosis assessment of congenital choledochal cyst in 21 cases. *J Obstet Gynaecol J Inst Obstet Gynaecol* 2016;36:324–7. doi:10.3109/01443615.2015.1050648.
- [21] Diao M, Li L, Cheng W. Timing of surgery for prenatally diagnosed asymptomatic choledochal cysts: a prospective randomized study. *J Pediatr Surg* 2012;47:506–12. doi:10.1016/j.jpedsurg.2011.09.056.
- [22] Urushihara N, Fukumoto K, Yamoto M, Miyake H, Takahashi T, Nomura A, et al. Characteristics, management, and outcomes of congenital biliary dilatation in neonates and early infants: a 20-year, single-institution study. *J Hepato-Biliary-Pancreat Sci* 2018;25:544–9. doi:10.1002/jhbp.590.
- [23] Ford KE, Cooper LRL, Davenport M. Growth in children with choledochal malformations: effect of the Roux loop. *Pediatr Surg Int* 2015;31:1015–19. doi:10.1007/s00383-015-3759-z.
- [24] Madadi-Sanjani O, Wirth TC, Kuebler JF, Petersen C, Ure BM. Choledochal cyst and malignancy: a plea for lifelong follow-up. *Eur J Pediatr Surg* 2019;29:143–9. doi:10.1055/s-0037-1615275.
- [25] Ten Hove A, de Meijer VE, Hulscher JBF, de Kleine RHJ. Meta-analysis of risk of developing malignancy in congenital choledochal malformation. *Br J Surg* 2018;105:482–90. doi:10.1002/bjs.10798.
- [26] Ohashi T, Wakai T, Kubota M, Matsuda Y, Arai Y, Ohya T, et al. Risk of subsequent biliary malignancy in patients undergoing cyst excision for congenital choledochal cysts. *J Gastroenterol Hepatol* 2013;28:243–7. doi:10.1111/j.1440-1746.2012.07260.x.
- [27] Watanabe Y, Toki A, Todani T. Bile duct cancer developed after cyst excision for choledochal cyst. *J Hepatobiliary Pancreat Surg* 1999;6:207–12. doi:10.1007/s005340050108.
- [28] Lee S-C, Kim H-Y, Jung S-E, Park K-W, Kim W-K. Is excision of a choledochal cyst in the neonatal period necessary? *J Pediatr Surg* 2006;41:1984–6. doi:10.1016/j.jpedsurg.2006.08.023.
- [29] Balistreri WF, Bezerra JA. Whatever happened to “Neonatal Hepatitis”? *Clin Liver Dis* 2006;10:27–53. doi:10.1016/j.cld.2005.10.008.
- [30] Mowat AP, Psacharopoulos HT, Williams R. Extrahepatic biliary atresia versus neonatal hepatitis. Review of 137 prospectively investigated infants. *Arch Dis Child* 1976;51:763–70. doi:10.1136/adc.51.7.763.
- [31] Alagille D. Cholestasis in the first three months of life. *Prog Liver Dis* 1979;6:471–85.
- [32] Ferry GD, Selby ML, Udall J, Finegold M, Nichols B. Guide to early diagnosis of biliary obstruction in infancy. Review of 143 cases. *Clin Pediatr* 1985;24:305–11. doi:10.1177/000992288502400601.
- [33] Humphrey TM, Stringer MD. Biliary atresia: US diagnosis. *Radiology* 2007;244:845–51. doi:10.1148/radiol.2443061051.
- [34] Lee MS, Kim M-J, Lee M-J, Yoon CS, Han SJ, Oh J-T, et al. Biliary atresia: color doppler US findings in neonates and infants. *Radiology* 2009;252:282–9. doi:10.1148/radiol.2522080923.
- [35] Koob M, Pariente D, Habes D, Ducot B, Adamsbaum C, Franchi-Abella S. The porta hepatis microcyst: an additional sonographic sign for the diagnosis of biliary atresia. *Eur Radiol* 2017;27:1812–21. doi:10.1007/s00330-016-4546-5.
- [36] Hays DM, Woolley MM, Snyder WH, Reed GB, GWINN JL, Landing BH. Diagnosis of biliary atresia: relative accuracy of percutaneous liver biopsy, open liver biopsy, and operative cholangiography. *J Pediatr* 1967;71:598–607. doi:10.1016/s0022-3476(67)80118-5.
- [37] el-Youssef M, Whittington PF. Diagnostic approach to the child with hepatobiliary disease. *Semin Liver Dis* 1998;18:195–202. doi:10.1055/s-2007-1007156.
- [38] Townsend MR, Jaber A, Abi Nader H, Eid SM, Schwarz K. Factors associated with timing and adverse outcomes in patients with biliary atresia undergoing Kasai hepatoportenterostomy. *J Pediatr* 2018;199 237–42.e2. doi:10.1016/j.jpeds.2018.04.001.
- [39] Azar G, Beneck D, Lane B, Markowitz J, Daum F, Kahn E. Atypical morphologic presentation of biliary atresia and value of serial liver biopsies. *J Pediatr Gastroenterol Nutr* 2002;34:212–15. doi:10.1097/00005176-200202000-00020.

- [40] Lemoine C, Melin-Aldana H, Brandt K, Mohammad S, Superina R. The evolution of early liver biopsy findings in babies with jaundice may delay the diagnosis and treatment of biliary atresia. *J Pediatr Surg* 2020;55:866–72. doi:10.1016/j.jpedsurg.2020.01.027.
- [41] Lertudomphonwanit C, Mourya R, Fei L, Zhang Y, Gutta S, Yang L, et al. Large-scale proteomics identifies MMP-7 as a sentinel of epithelial injury and of biliary atresia. *Sci Transl Med* 2017;9:eaa8462. doi:10.1126/scitranslmed.aan8462.
- [42] Jiang J, Wang J, Shen Z, Lu X, Chen G, Huang Y, et al. Serum MMP-7 in the diagnosis of biliary atresia. *Pediatrics* 2019;144:e20190902. doi:10.1542/peds.2019-0902.
- [43] Wu J-F, Jeng Y-M, Chen H-L, Ni Y-H, Hsu H-Y, Chang M-H. Quantification of serum matrix metalloproteinase 7 levels may assist in the diagnosis and predict the outcome for patients with biliary atresia. *J Pediatr* 2019;208:30–7 e1. doi:10.1016/j.jpeds.2018.12.006.
- [44] Yang L, Zhou Y, Xu P-P, Mourya R, Lei H-Y, Cao G-Q, et al. Diagnostic accuracy of serum matrix metalloproteinase-7 for biliary atresia. *Hepatol Baltim Md* 2018;68:2069–77. doi:10.1002/hep.30234.
- [45] Yang M-C, Chang M-H, Chiu S-N, Peng S-F, Wu J-F, Ni Y-H, et al. Implication of early-onset biliary atresia and extrahepatic congenital anomalies. *Pediatr Int Off J Jpn Pediatr Soc* 2010;52:569–72. doi:10.1111/j.1442-200X.2009.03014.x.
- [46] Feldman AG, Sokol RJ. Neonatal cholestasis: emerging molecular diagnostics and potential novel therapeutics. *Nat Rev Gastroenterol Hepatol* 2019;16:346–60. doi:10.1038/s41575-019-0132-z.
- [47] Moreira-Silva H, Maio I, Bandeira A, Gomes-Martins E, Santos-Silva E. Metabolic liver diseases presenting with neonatal cholestasis: at the cross-road between old and new paradigms. *Eur J Pediatr* 2019;178:515–23. doi:10.1007/s00431-019-03328-5.
- [48] Suchy FJ. Neonatal cholestasis. *Pediatr Rev* 2004;25:388–96.
- [49] Tufano M, Nicastro E, Gilberti P, Vegnente A, Raimondi F, Iorio R. Cholestasis in neonatal intensive care unit: incidence, aetiology and management. *Acta Paediatr Oslo Nor* 1992;2009;98:1756–61. doi:10.1111/j.1651-2227.2009.01464.x.
- [50] Ferreira CR, Cassiman D, Blau N. Clinical and biochemical footprints of inherited metabolic diseases. II. Metabolic liver diseases. *Mol Genet Metab* 2019;127:117–21. doi:10.1016/j.ymgme.2019.04.002.
- [51] Lien T-H, Chang M-H, Wu J-F, Chen H-L, Lee H-C, Chen A-C, et al. Effects of the infant stool color card screening program on 5-year outcome of biliary atresia in Taiwan. *Hepatol Baltim Md* 2011;53:202–8. doi:10.1002/hep.24023.
- [52] Shneider BL, Moore J, Kerkar N, Magee JC, Ye W, Karpen SJ, et al. Initial assessment of the infant with neonatal cholestasis—is this biliary atresia? *PLoS ONE* 2017;12:e0176275. doi:10.1371/journal.pone.0176275.
- [53] Witt M, Lindeboom J, Wijnga C, Kesler A, Keyzer-Dekker CMG, Verkade HJ, et al. Early detection of neonatal cholestasis: inadequate assessment of stool color by parents and primary healthcare doctors. *Eur J Pediatr Surg* 2016;26:67–73. doi:10.1055/s-0035-1566101.
- [54] Rosenthal P, Blanckaert N, Kabra PM, Thaler MM. Formation of bilirubin conjugates in human newborns. *Pediatr Res* 1986;20:947–50. doi:10.1203/00006450-198610000-00010.
- [55] Harpavat S, Finegold MJ, Karpen SJ. Patients with biliary atresia have elevated direct/conjugated bilirubin levels shortly after birth. *Pediatrics* 2011;128:e1428–33. doi:10.1542/peds.2011-1869.
- [56] Harpavat S, Garcia-Prats JA, Shneider BL. Newborn bilirubin screening for biliary atresia. *N Engl J Med* 2016;375:605–6. doi:10.1056/NEJMc1601230.
- [57] Harpavat S, Ramraj R, Finegold MJ, Brandt ML, Hertel PM, Fallon SC, et al. Newborn direct or conjugated bilirubin measurements as a potential screen for biliary atresia. *J Pediatr Gastroenterol Nutr* 2016;62:799–803. doi:10.1097/MPG.0000000000001097.
- [58] Harpavat S, Garcia-Prats JA, Anaya C, Brandt ML, Lupo PJ, Finegold MJ, et al. Diagnostic yield of newborn screening for biliary atresia using direct or conjugated bilirubin measurements. *JAMA* 2020;323:1141–50. doi:10.1001/jama.2020.0837.
- [59] De Bruyne R, Van Biervliet S, Vande Velde S, Van Winckel M. Clinical practice: neonatal cholestasis. *Eur J Pediatr* 2011;170:279–84. doi:10.1007/s00431-010-1363-8.
- [60] Fujishiro J, Suzuki K, Watanabe M, Uotani C, Takezoe T, Takamoto N, et al. Outcomes of Alagille syndrome following the Kasai operation: a systematic review and meta-analysis. *Pediatr Surg Int* 2018;34:1073–7. doi:10.1007/s00383-018-4316-3.
- [61] Kaye AJ, Rand EB, Munoz PS, Spinner NB, Flake AW, Kamath BM. Effect of Kasai procedure on hepatic outcome in Alagille syndrome. *J Pediatr Gastroenterol Nutr* 2010;51:319–21. doi:10.1097/MPG.0b013e3181df5fd8.
- [62] Lee HP, Kang B, Choi SY, Lee S, Lee S-K, Choe YH. Outcome of alagille syndrome patients who had previously received kasai operation during infancy: a single center study. *Pediatr Gastroenterol Hepatol Nutr* 2015;18:175–9. doi:10.5223/pghn.2015.18.3.175.
- [63] Liu X, Peng X, Huang Y, Shu C, Liu P, Xie W, et al. Design and validation of a noninvasive diagnostic criteria for biliary atresia in infants based on the STROBE compliant. *Medicine (Baltimore)* 2019;98:e13837. doi:10.1097/MD.00000000000013837.
- [64] Sun S, Chen G, Zheng S, Xiao X, Xu M, Yu H, et al. Analysis of clinical parameters that contribute to the misdiagnosis of biliary atresia. *J Pediatr Surg* 2013;48:1490–4. doi:10.1016/j.jpedsurg.2013.02.034.
- [65] Maggiore C, Bernard O, Riely CA, Hadchouel M, Lemonnier A, Alagille D. Normal serum gamma-glutamyl-transpeptidase activity identifies groups of infants with idiopathic cholestasis with poor prognosis. *J Pediatr* 1987;111:251–2. doi:10.1016/s0022-3476(87)80079-3.
- [66] Suchy FJ, Balistreri WF, Heubi JE, Searcy JE, Levin RS. Physiologic cholestasis: elevation of the primary serum bile acid concentrations in normal infants. *Gastroenterology* 1981;80:1037–41.
- [67] Heubi JE, Setchell KDR, Bove KE. Inborn errors of bile acid metabolism. *Clin Liver Dis* 2018;22:671–87. doi:10.1016/j.cld.2018.06.006.
- [68] Abbey P, Kandasamy D, Naranje P. Neonatal Jaundice. *Indian J Pediatr* 2019;86:830–41. doi:10.1007/s12098-019-02856-0.
- [69] Davenport M, Tizzard SA, Underhill J, Mieli-Vergani G, Portmann B, Hadzić N. The biliary atresia splenic malformation syndrome: a 28-year single-center retrospective study. *J Pediatr* 2006;149:393–400. doi:10.1016/j.jpeds.2006.05.030.
- [70] Wang L, Yang Y, Chen Y, Zhan J. Early differential diagnosis methods of biliary atresia: a meta-analysis. *Pediatr Surg Int* 2018;34:363–80. doi:10.1007/s00383-018-4229-1.
- [71] Zhou L, Shan Q, Tian W, Wang Z, Liang J, Xie X. Ultrasound for the diagnosis of biliary atresia: a meta-analysis. *AJR Am J Roentgenol* 2016;206:W73–82. doi:10.2214/AJR.15.15336.
- [72] Dillman JR, DiPaola FW, Smith SJ, Barth RA, Asai A, Lam S, et al. Prospective assessment of ultrasound shear wave elastography for discriminating biliary atresia from other causes of neonatal cholestasis. *J Pediatr* 2019;212:60–5 e3. doi:10.1016/j.jpeds.2019.05.048.
- [73] Wu J-F, Lee C-S, Lin W-H, Jeng Y-M, Chen H-L, Ni Y-H, et al. Transient elastography is useful in diagnosing biliary atresia and predicting prognosis after hepatoporoenterostomy. *Hepatol Baltim Md* 2018;68:616–24. doi:10.1002/hep.29856.
- [74] Kianifar HR, Tehrani S, Shojaei P, Adinehpour Z, Sadeghi R, Kakhki VRD, et al. Accuracy of hepatobiliary scintigraphy for differentiation of neonatal hepatitis from biliary atresia: systematic review and meta-analysis of the literature. *Pediatr Radiol* 2013;43:905–19. doi:10.1007/s00247-013-2623-3.
- [75] Tsuda N, Shiraiishi S, Sakamoto F, Ogasawara K, Tomiguchi S, Yamashita Y. Tc-99m PMT scintigraphy in the diagnosis of pediatric biliary atresia. *Jpn J Radiol* 2019;37:841–9. doi:10.1007/s11604-019-00882-8.
- [76] Low CS, Ahmed H, Notghi A. Pitfalls and limitations of radionuclide hepatobiliary and gastrointestinal system imaging. *Semin Nucl Med* 2015;45:513–29. doi:10.1053/j.semnuclmed.2015.06.001.
- [77] Kishore R, Kisku SMC, Thomas RJ, Jeemipalli SK. Laparoscopic cholangiogram in biliary atresia: a refinement in the gallbladder hitch technique. *Pediatr Surg Int* 2018;34:395–8. doi:10.1007/s00383-018-4236-2.
- [78] Alkan M, Tutus K, Fakioglu E, Ozden O, Hatipoglu Z, Iskit SH, et al. Laparoscopy-assisted percutaneous cholangiography in biliary atresia diagnosis: comparison with open technique. *Gastroenterol Res Pract* 2016;5637072. doi:10.1155/2016/5637072.
- [79] Negm AA, Petersen C, Markowski A, Luettig B, Ringe KI, Lankisch TO, et al. The role of endoscopic retrograde cholangiopancreatography in the diagnosis of biliary atresia: 14 years' experience. *Eur J Pediatr Surg* 2018;28:261–7. doi:10.1055/s-0037-1602260.
- [80] Russo P, Magee JC, Boitnott J, Bove KE, Raghunathan T, Finegold M, et al. Design and validation of the biliary atresia research consortium histologic assessment system for cholestasis in infancy. *Clin Gastroenterol Hepatol* 2011;9:357–62.e2. doi:10.1016/j.cgh.2011.01.003.
- [81] Desmet VJ. Histopathology of cholestasis. *Verh Dtsch Ges Pathol* 1995;79:233–40.
- [82] Russo P, Magee JC, Anders RA, Bove KE, Chung C, Cummings OW, et al. Key histopathologic features of liver biopsies that distinguish biliary atresia from other causes of infantile cholestasis and their correlation with outcome: a multicenter study. *Am J Surg Pathol* 2016;40:1601–15. doi:10.1097/PAS.0000000000000755.
- [83] Mandelja A, Lal R, Mutt N. Role of hepatobiliary scintigraphy and preoperative liver biopsy for exclusion of biliary atresia in neonatal cholestasis syndrome. *Indian J Pediatr* 2017;84:685–90. doi:10.1007/s12098-017-2408-z.
- [84] Lee JYJ, Sullivan K, El Demellawy D, Nasr A. The value of preoperative liver biopsy in the diagnosis of extrahepatic biliary atresia: a systematic review and meta-analysis. *J Pediatr Surg* 2016;51:753–61. doi:10.1016/j.jpedsurg.2016.02.016.
- [85] Antonarakis SE, Beckmann JS. Mendelian disorders deserve more attention. *Nat Rev Genet* 2006;7:277–82. doi:10.1038/nrg1826.
- [86] Metzker ML. Sequencing technologies - the next generation. *Nat Rev Genet* 2010;11:31–46. doi:10.1038/nrg2626.
- [87] Nicastro E, D'Antiga L. Next generation sequencing in pediatric hepatology and liver transplantation. *Liver Transplant* 2018;24:282–93. doi:10.1002/lt.24964.
- [88] Richards S, Aziz N, Bale S, Bick D, Das S, Gastier-Foster J, et al. Standards and guidelines for the interpretation of sequence variants: a joint consensus recommendation of the American College of Medical Genetics and Genomics and the Association for Molecular Pathology. *Genet Med* 2015;17:405–24. doi:10.1038/gim.2015.30.
- [89] Chen H-L, Li H-Y, Wu J-F, Wu S-H, Chen H-L, Yang Y-H, et al. Panel-based next-generation sequencing for the diagnosis of cholestatic genetic liver diseases: clinical utility and challenges. *J Pediatr* 2019;205:153–9.e6. doi:10.1016/j.jpeds.2018.09.028.
- [90] Matte U, Mourya R, Miethke A, Liu C, Kauffmann G, Moyer K, et al. Analysis of gene mutations in children with cholestasis of undefined etiology. *J Pediatr Gastroenterol Nutr* 2010;51:488–93. doi:10.1097/MPG.0b013e3181dffe8f.

- [91] Nicastrò E, Di Giorgio A, Marchetti D, Barboni C, Cereda A, Iacone M, et al. Diagnostic yield of an algorithm for neonatal and infantile cholestasis integrating next-generation sequencing. *J Pediatr* 2019;211:54–62.e4. doi:10.1016/j.jpeds.2019.04.016.
- [92] Shagrani M, Burkholder J, Broering D, Abouelhoda M, Faquih T, El-Kalioby M, et al. Genetic profiling of children with advanced cholestatic liver disease. *Clin Genet* 2017;92:52–61. doi:10.1111/cge.12959.
- [93] Togawa T, Sugiura T, Ito K, Endo T, Aoyama K, Ohashi K, et al. Molecular genetic dissection and neonatal/infantile intrahepatic cholestasis using targeted next-generation sequencing. *J Pediatr* 2016;171:171–7 e1–4. doi:10.1016/j.jpeds.2016.01.006.
- [94] Wang N-L, Lu Y-L, Zhang P, Zhang M-H, Gong J-Y, Lu Y, et al. A specially designed multi-gene panel facilitates genetic diagnosis in children with intrahepatic cholestasis: simultaneous test of known large insertions/deletions. *PLoS ONE* 2016;11:e0164058. doi:10.1371/journal.pone.0164058.
- [95] Nykamp K, Anderson M, Powers M, Garcia J, Herrera B, Ho Y-Y, et al. Sherloc: a comprehensive refinement of the ACMG-AMP variant classification criteria. *Genet Med* 2017;19:1105–17. doi:10.1038/gim.2017.37.
- [96] Rajagopalan R, Gilbert MA, McEldrew DA, Nassur JA, Loomes KM, Piccoli DA, et al. Genome sequencing increases diagnostic yield in clinically diagnosed Alagille syndrome patients with previously negative test results. *Genet Med* 2021;23:323–30. doi:10.1038/s41436-020-00989-8.
- [97] Chiba T, Kasai M. An attempt to determine surgical indication for biliary atresia by laboratory examination. *Tohoku J Exp Med* 1975;115:345–53. doi:10.1620/tjem.115.345.
- [98] El-Guindi MA-S, Sira MM, Sira AM, Salem TA-H, El-Abd OL, Konsowa HA-S, et al. Design and validation of a diagnostic score for biliary atresia. *J Hepatol* 2014;61:116–23. doi:10.1016/j.jhep.2014.03.016.
- [99] Jancelewicz T, Barmherzig R, Chung CT-S, Ling SC, Kamath BM, Ng VL, et al. A screening algorithm for the efficient exclusion of biliary atresia in infants with cholestatic jaundice. *J Pediatr Surg* 2015;50:363–70. doi:10.1016/j.jpedsurg.2014.08.014.
- [100] Dong R, Jiang J, Zhang S, Shen Z, Chen G, Huang Y, et al. Development and validation of novel diagnostic models for biliary atresia in a large cohort of chinese patients. *EBioMedicine* 2018;34:223–30. doi:10.1016/j.ebiom.2018.07.025.
- [101] Champion V, Carbajal R, Lozar J, Girard I, Mitanchez D. Risk factors for developing transient neonatal cholestasis. *J Pediatr Gastroenterol Nutr* 2012;55:592–8. doi:10.1097/MPG.0b013e3182616916.
- [102] Jackson RL, White PZ, Zalla J. SMOFlipid vs intralipid 20%: effect of mixed-oil vs soybean-oil emulsion on parenteral nutrition-associated cholestasis in the neonatal population. *JPEN J Parenter Enteral Nutr* 2021;45:339–46. doi:10.1002/jpen.1843.
- [103] Potter CJ. Cholestasis in the premature infant. *Clin Perinatol* 2020;47:341–54. doi:10.1016/j.clp.2020.02.009.