Urology Case Reports 36 (2021) 101558

Contents lists available at ScienceDirect

Urology Case Reports

journal homepage: http://www.elsevier.com/locate/eucr

Oncology

A thigh urinary fistula following radical prostatectomy and external beam radiation therapy for prostate cancer: a case report

Stefania Zamboni [a,1], Chiara Lonati [a,1,*], Giuseppe Mirabella [a], Maria Furlan [a], Barbara Frittoli [b], Claudio Simeone [a]

[a] Department of Urology, Spedali Civili Hospital of Brescia, University of Brescia, Brescia, Italy
[b] Department of Radiology, Spedali Civili Hospital of Brescia, University of Brescia, Brescia, Italy

ARTICLE INFO

Keywords:
Prostate cancer
Radiation therapy
Urinary fistula
Thigh swelling

ABSTRACT

Urinary fistula is a rare but severe complication which could occur after radiation therapy for prostate cancer (PCa). We describe the case of an inner thigh urinary fistula in a patient treated with radical prostatectomy and adjuvant radiation therapy for PCa. A 76-year-old man presented to the emergency room complaining of right thigh swelling, pain and fever. Computed tomography scan and urethra-cystography showed bladder-neck leakage and fluid collection, extended from the pelvis to the right inner thigh. Patient was treated with ultrasound-guided drainage and intravenous antibiotics. Timely diagnosis and treatment are necessary in order to reduce possible evolution to necrotizing fasciitis.

Introduction

External beam radiotherapy (EBRT) (plus androgenic deprivation therapy) is recommended by European Association of Urology (EAU) Guidelines as an alternative treatment option for localized prostate cancer (PCa) since confers 10-years oncological outcomes comparable to radical prostatectomy (RP).[1] Moreover EBRT, is recommended after RP as an adjuvant therapy or in case of recurrence after surgery. Over time, with the improvement of technologies, several techniques and regimens of EBRT have been developed and applied in order to reduce its toxicity and collateral effects. However, EBRT is still burdened by several types of complications, included urinary fistula, which represents an extremely rare late complication.

The present case report describes a case of urinary fistula between urethra and the right thigh in a patient treated with RP and EBRT for PCa. The patient provided written informed consent. We present the following case report in accordance with the CARE reporting check list.

Case presentation

A 76-year-old male patient presented to the emergency department with right inner thigh pain and swelling. His medical history revealed prior PCa (pT3aN0M0 Gleason Score 7) treated in 2009 with open RP and adjuvant EBRT. In 2017, after development of progressive dysuria, the patient underwent cystoscopy with diagnosis of bladder-neck's sclerosis, consequently treated with transurethral resection (TUR) of the tissue. Although this treatment, the patients presented dysuria and underwent urethral dilatation; nonetheless, during the same year, the patient presented two episodes of acute urinary retention treated with temporary catheterization.

In January 2020, his persistent symptoms have been investigated with urinary cytology (negative), abdominal ultrasound and urethra-cystography, which showed the presence of bladder stones and left vesicoureteral reflux. The stones were consequently treated with bladder lithotripsy with the confirmation of bladder-neck sclerosis during the cystoscopy.

In April 2020, the patient presented to the emergency department for fever (38.4 °C) and right inner thigh swelling and pain; blood analyses were significant for infection with leukocytosis (white cell count: 11000/mm3) and elevated C-reactive protein (CRP) (286 mg/L). He was treated with ultrasound-guided aspiration of the thigh collection and broad-spectrum antibiotic therapy with Ceftriaxone 1 g iv for 12 days.

Three weeks later, due to persistence of inner thigh pain and swelling, he presented to our emergency department for the first time. Vital signs included a blood pressure of 110/60 mmHg, patient's pSO_2 was 94% in ambient air and heart rate 87 bpm. On physical

* Corresponding author. Department of Urology, Spedali Civili Hospital of Brescia, University of Brescia, piazzale Spedali Civili 1, Brescia, 25123, Italy.
E-mail address: chiara.lonati@libero.it (C. Lonati).
[1] Shared first authorship.

https://doi.org/10.1016/j.eucr.2020.101558
Received 12 December 2020; Received in revised form 22 December 2020; Accepted 30 December 2020
Available online 4 January 2021

Table 1
Clinical laboratory results at arrival on emergency department and at discharge.

Blood analysis			
Measure	Day of admission	Day of discharge	Reference range
White blood cells count, x 10^3/μL	9,41 × 10^3/μL	6,24 × 10^3/μL	4,0 - 10,80 × 103/μL
Red blood cells count, × 10^6/μL	4,43 × 10^6/μL	3,51 × 10^6/μL	4,50 - 5,50 × 106/μL
Hemoglobin, g/dL	13,1 g/dL	10,6 g/dL	14,0-18,0 g/dL
Hematocrit, %	39,7%	32,7%	42,0 - 52,0%
Lymphocyte count, relative, %	14%	31,9%	20,0 - 45,0%
Neutrophil count, relative, %	80,9%	50,9%	20,0 - 45,0%
Platelet count, × 10^3/μL	293 × 10^3/μL	214 × 10^3/μL	130 - 400 × 103/μL
Creatinine, mg/dL	3,31 mg/dL	0,86 mg/dL	0,70-1,20 mg/dL
C-reactive protein, mg/L	8,1 mg/L		<5,0 mg/L
Na, mmol/L	128 mmol/L	138 mmol/L	136–145 mmol/L
K, mmol/L	5,9 mmol/L	4,1 mmol/L	3,40 - 4,50 mmol/L

examination, his medial compartment of the right thigh was swollen and warm. Laboratory analyses results are reported in Table 1. The patient was evaluated with abdominal and right thigh ultrasound, which revealed a fluid collection, extended from the pelvis (where was contiguous to the pubic bone) to the medial compartment of the right thigh for about 20 cm. The collection was treated with an ultrasound-guided drainage, and about 60 cc of clear fluid were removed; laboratory analyses on the fluid revealed the presence of urine and neutrophil granulocytes. Subsequently, an abdominal computed tomography (CT) without contrast enhancement -for acute renal failure- was performed in order to evaluate the collection: despite the drainage, the collection extended from the pelvis to the adductor magnus caudally. CT scan was finally completed with urethra-cystography and showed a fluid collection in the right inner thigh in continuity to the bladder-neck (Fig. 1 and Fig. 2). Suprapubic cystostomy was performed in order to improve renal function. At the last ultrasound control before the discharge, the collection was reduced from 20 cm to 1.8 cm at the root of the thigh.

Discussion

EBRT represents an effective treatment option in alternative to RP in patients with localized PCa; moreover, it is recommended as salvage radiotherapy or adjuvant radiotherapy for recurrence after surgery. However, several complications could occur after EBRT. Wallis et al.[2] reported a higher rate of hospital re-admissions and higher incidence of minimally invasive urologic procedures in patients treated with EBRT for PCa compared to those treated with prostatectomy alone. Complications' rate increases with the association of the two techniques.

We reported a case of late radiotherapy/prostatectomy-related complication, consisting in an urinary fistula after a transurethral resection of bladder-neck, performed for the development of sclerosis after radiotherapy. To our knowledge, this is the fourth case of thigh

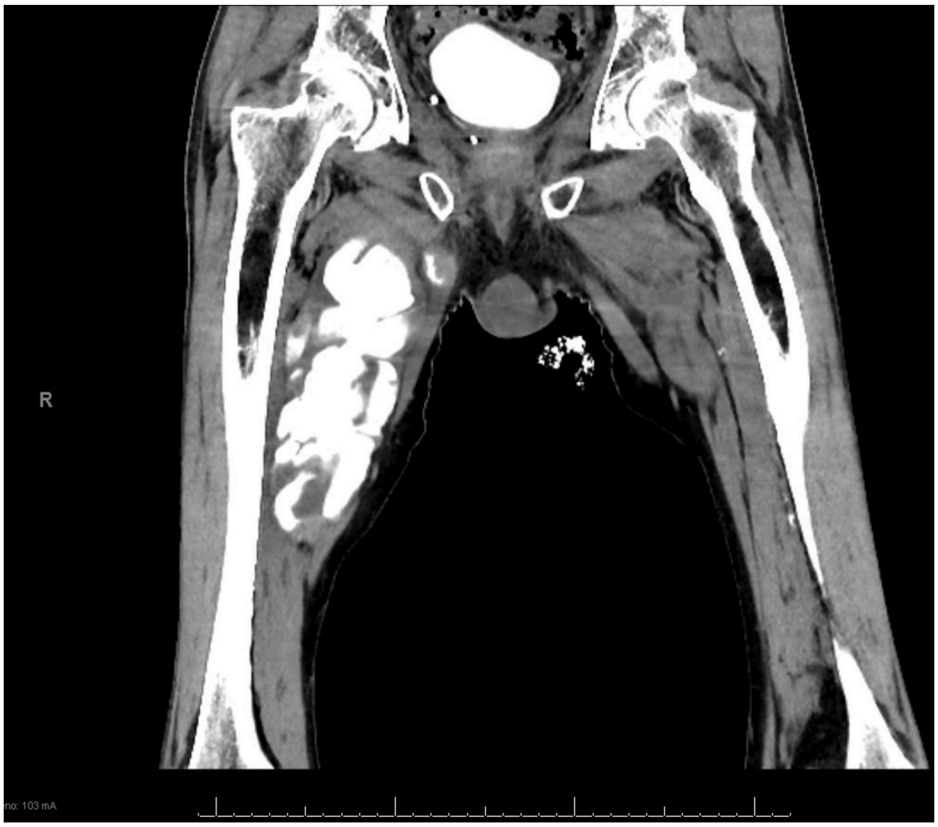

Fig. 1. Computed Tomography scan shows a fluid collection from the pelvis to the right inner thigh.

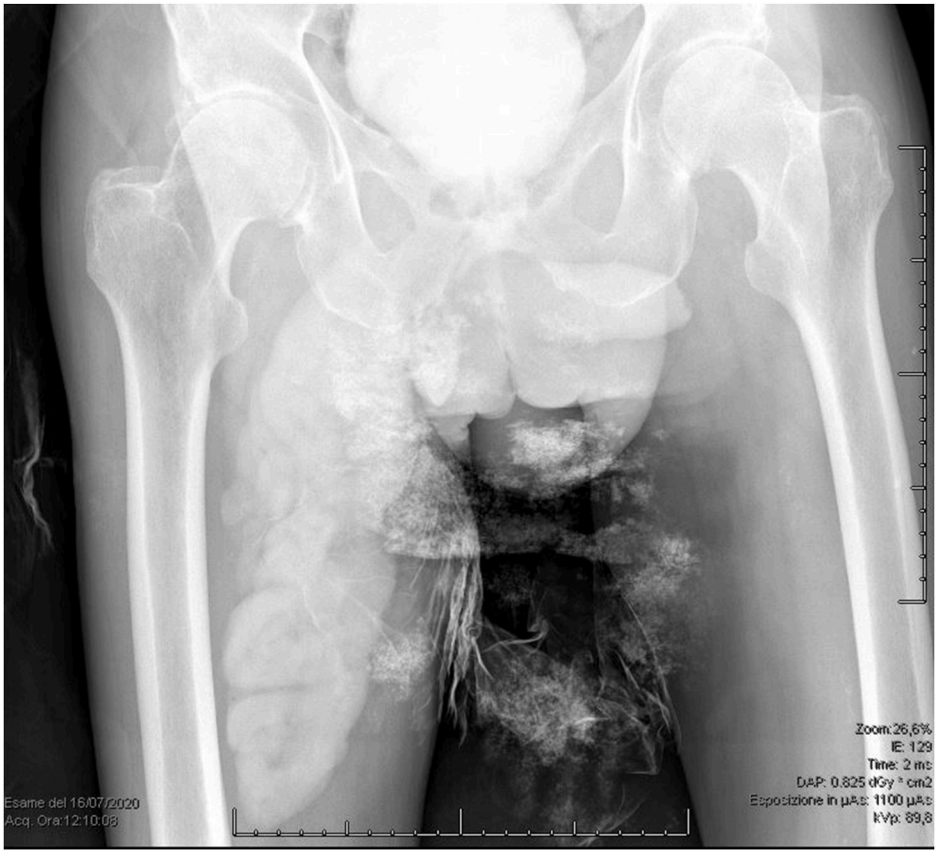

Fig. 2. Urethra-cystography shows bladder-neck leakage and a fluid collection from the pelvis to the right inner thigh.

fistula after EBRT for PCa. Yamashita et al.[3] described the case of a 77-year-old man with necrotizing fasciitis (NF) after high-dose rate brachytherapy and EBRT for PCa. Three years after treatment, this patient presented dysuria. Patient's evaluation included cystoscopy, which revealed prostatic urethra obstruction due to the presence of necrotic tissue; he was subsequentially treated with TUR of the necrotic tissue. Several months later, he presented to the emergency department for fever and inguinal swelling. CT scan showed extensive gas within the femoral and retroperitoneal tissues. He underwent surgical exploration and was treated with negative pressure wound therapy and broad-spectrum antibiotics. Ennaciri et al.[4] reported a case of recurrent thigh swelling four years after RP followed by EBRT for PCa. The patient was treated with surgical drainage and antibiotic therapy. Boinpally et al.[5] described a case of bilateral necrotizing myositis in a 74-year-old man who underwent EBRT and TUR for PCa. Serial debridements were performed in order to remove all the necrotic tissue. Clinical diagnosis was confirmed at the histopathological analysis. These cases were characterized by progressive swelling and pain at the groin or thigh level associated with signs of infection, such as fever and leukocytosis at blood analysis. The optimal treatment could be represented by broad-spectrum intravenous antibiotics and drainage of the fluid collection. Immediate surgical exploration may be necessary in case of rapid progression to NF. No risk of osteonecrosis of the femur was reported in all these cases.

Conclusion

Although urinary fistula extended to the thigh represents a rare radiation-related complication, clinical suspicious in case of swelling, pain and fever is required in order to promptly diagnose and correctly treat this rare condition and to strongly reduce mortality.

Funding sources

This research did not receive any specific grant from funding agencies in the public, commercial, or not-for-profit sectors.

Statement of ethics

The authors declare that they have obtained patient's consent for publication.

Authors' Contributions:

Stefania Zamboni: conceptualization, methodology, investigation, writing – review & editing; **Chiara Lonati**: conceptualization, methodology, investigation, writing – review & editing; **Giuseppe Mirabella**: investigation, resources; **Maria Furlan**: investigation, resources; **Barbara Frittoli**: methodology, resources; **Claudio Simeone**: investigation, supervision, writing – review & editing.

Declarations of competing interest

None.

Acknowledgement

None.

References

1. Mottet N, Bellmunt J, Bolla M, et al. EAU-ESTRO-SIOG Guidelines on prostate cancer. Part 1: screening, diagnosis, and local treatment with curative intent. *Eur Urol.* 2017; 71(4):618–629. https://doi.org/10.1016/j.eururo.2016.08.003.

2. Wallis CJD, Cheung P, Herschorn S, et al. Complications following surgery with or without radiotherapy or radiotherapy alone for prostate cancer. *Br J Canc*. 2015;112 (6):977–982. https://doi.org/10.1038/bjc.2015.54.
3. Yamashita S, Kohjimoto Y, Iba A, Kikkawa K, Hara I. Necrotizing fasciitis after high-dose rate brachytherapy and external beam radiation for prostate cancer: a case report. *BMC Urol*. 2017;17(1):107. https://doi.org/10.1186/s12894-017-0299-y.
4. Ennaciri S, Bitard TM. Collection de la cuisse révélant une fistule vésicale après radiothérapie pour cancer de la prostate. *Pan Afr Med J*. 2018;30. https://doi.org/10.11604/pamj.2018.30.197.16037.
5. Boinpally H, Howell RS, Ram B, et al. Necrotizing myositis: a rare necrotizing soft tissue infection involving muscle. *Wounds a Compend Clin Res Pract*. 2018;30(12): E116–E120. http://www.ncbi.nlm.nih.gov/pubmed/30561371.