

channel that it activates. However, this work highlights the fact that the permeability factor of MCD may not be solely a glomerular one (allowing the leakage of albumin through the glomerular filtration barrier), but also a systemic one, allowing the leakage of sodium in the interstitial space, possibly through the activation of an endothelial sodium channel by proteases.

In conclusion, this original work shows, for the first time, an increased endothelial permeability induced by sera from patients with MCD, allowing the passage of sodium through the endothelium, probably participating in the constitution of edema, and reversed by amiloride and by aprotinin.

## DISCLOSURE

All the authors declared no competing interests.

## SUPPLEMENTARY MATERIAL

Supplementary File (Word)

**Supplementary Material and Methods.**

**Table S1.** Patient characteristics.

**Figure S1.** Sera from MCD patients do not modify the permeability of HUVEC to high molecular weight molecules *in vitro*.

**Figure S2.** The increase in HUVEC permeability is not due to paracellular pathway modifications.

**Figure S3.** The increase of the HUVEC permeability for low molecular weight molecules *in vitro* is not linked to the Caveolin 1 pathway.

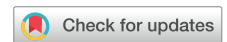**Figure S4.** The cleavage of ENaC *in vitro* is not increased by MCD sera.

**Supplementary References.**

## REFERENCES

1. Maas RJ, Deegens JK, Wetzels JF. Permeability factors in idiopathic nephrotic syndrome: historical perspectives and lessons for the future. *Nephrol Dial Transplant*. 2014;1(29):2207–2216.
2. Ellis D. Pathophysiology, evaluation, and management of edema in childhood nephrotic syndrome. *Front Pediatr*. 2016;3:111.
3. Warnock DG, Kusche-Vihrog K, Tarjus A, et al. Blood pressure and amiloride-sensitive sodium channels in vascular and renal cells. *Nat Rev Nephrol*. 2014;10:146–157.
4. Goddard LM, Iruela-Arispe ML. Cellular and molecular regulation of vascular permeability. *Thromb Haemost*. 2013;109:407–415.
5. Sowa G. Caveolae, caveolins, cavins, and endothelial cell function: new insights. *Front Physiol*. 2012;2:120.
6. Lourdel S, Loffing J, Favre G, et al. Hyperaldosteronemia and activation of the epithelial sodium channel are not required for sodium retention in puromycin-induced nephrosis. *J Am Soc Nephrol*. 2005;16:3642–3650.
7. Svenningsen P, Bistrup C, Friis UG, et al. Plasmin in nephrotic urine activates the epithelial sodium channel. *J Am Soc Nephrol*. 2009;20:299–310.
8. Artunc F, Wörn M, Schork A, Bohnert BN. Proteasuria—the impact of active urinary proteases on sodium retention in nephrotic syndrome. *Acta Physiol*. 2019;225:e13249.
9. Bohnert BN, Menacher M, Janessa A, et al. Aprotinin prevents proteolytic epithelial sodium channel (ENaC) activation and volume retention in nephrotic syndrome. *Kidney Int*. 2018;93:159–172.

# Type IV Collagen Mutations in Familial IgA Nephropathy



Yifu Li<sup>1,10</sup>, Emily E. Groopman<sup>1,10</sup>, Vivette D'Agati<sup>2</sup>, Sindhuri Prakash<sup>1</sup>, Junying Zhang<sup>1</sup>, Malgorzata Mizerska-Wasiak<sup>3</sup>, Yasar Caliskan<sup>4</sup>, David Fasel<sup>1</sup>, Hussein H. Karnib<sup>5</sup>, Luisa Bono<sup>6</sup>, Sadek Al Omran<sup>7</sup>, Essam Al Sabban<sup>7</sup>, Krzysztof Kiryluk<sup>1</sup>, Gianluca Caridi<sup>8</sup>, Gian Marco Ghiggeri<sup>8</sup>, Simone Sanna-Cherchi<sup>1</sup>, Francesco Scolari<sup>9</sup> and Ali G. Gharavi<sup>1</sup>

<sup>1</sup>Division of Nephrology, Columbia University, New York, New York, USA; <sup>2</sup>Division of Renal Pathology, Columbia University, New York, New York, USA; <sup>3</sup>Department of Pediatrics and Nephrology, Medical University of Warsaw, Warsaw, Poland; <sup>4</sup>Division of Nephrology, Istanbul University, Istanbul, Turkey; <sup>5</sup>Department of Medicine, American University of Beirut, Beirut, Lebanon; <sup>6</sup>Nephrology Dialysis with Renal Transplant Department, Civico and Di Cristina Hospital, Palermo, Italy; <sup>7</sup>King Faisal Specialist Hospital & Research Center (KFSHRC), Riyadh, Saudi Arabia; <sup>8</sup>Department of Nephrology and Transplantation, Istituto G. Gaslini Istituto di Ricovero e Cura a Carattere Scientifico, Genoa, Italy; and <sup>9</sup>Department of Medical and Surgical Specialties, Radiological Sciences and Public Health, University of Brescia, Brescia, Italy

**Correspondence:** Ali Gharavi, Division of Nephrology, Columbia University College of Physicians and Surgeons, 1150 St. Nicholas Avenue, Russ Berrie Pavilion 413, New York, New York 10032, USA. E-mail: [ag2239@columbia.edu](mailto:ag2239@columbia.edu)

<sup>10</sup>These authors are co-first authors.

Received 1 February 2020; revised 23 March 2020; accepted 10 April 2020; published online 24 April 2020

*Kidney Int Rep* (2020) 5, 1075–1078; <https://doi.org/10.1016/j.ekir.2020.04.011>

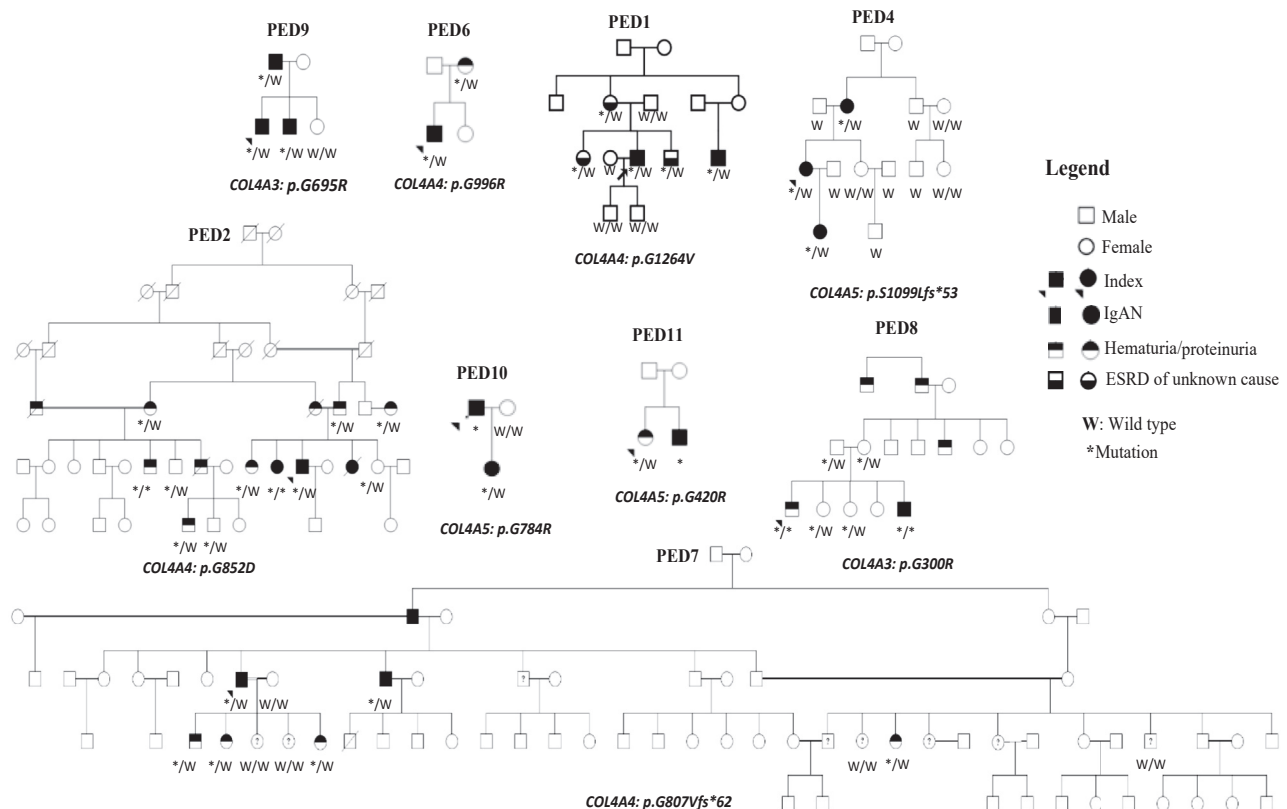
© 2020 International Society of Nephrology. Published by Elsevier Inc. This is an open access article under the CC BY-NC-ND license (<http://creativecommons.org/licenses/by-nc-nd/4.0/>).

IgA nephropathy (IgAN) is a leading cause of chronic glomerulonephritis, and exhibits highly heterogeneous clinical and pathological features<sup>1,2</sup>. Although IgAN classically presents as a young adult with macroscopic hematuria accompanying an upper respiratory infection or gastrointestinal illness, patients can present with isolated microscopic hematuria, mild proteinuria, and/or hypertension.<sup>1,2</sup> Diagnosis is based on renal biopsy, with characteristic features including mesangial hypercellularity and IgA-dominant deposits in the glomerular mesangium; however, diverse findings can be seen on light and electron microscopy.<sup>1,2</sup> The prevalence of IgAN varies with ethnicity, and correspondingly follows a geographic gradient, being found most commonly in East Asians, followed by Europeans, and rarely among individuals of African descent.<sup>1,51</sup> Both such ancestry-specific variation and familial clustering of disease support that hereditary factors contribute meaningfully to the pathogenesis of IgAN; yet, although genome-wide association studies have identified many risk loci for sporadic forms of IgAN, the genetic basis of familial disease remains largely unresolved.<sup>1,52</sup>

Interestingly, manifestations of IgAN, including microscopic hematuria and diffuse glomerular basement thinning,<sup>3</sup> can overlap considerably with those of type

IV collagen-associated nephropathy, which includes Alport syndrome (AS) and thin basement membrane disease (TBMD) and results from mutations in the *COL4A3*, *COL4A4*, and *COL4A5* genes. Moreover, prior genome-wide linkage scans of familial IgAN have detected significant signals at the chromosome 2q36 region,<sup>4</sup> which encompasses the *COL4A3/A4* locus, further supporting that in some cases, type IV collagen mutations may be associated with IgAN. To investigate this hypothesis, we retrospectively analyzed the exome sequence (ES) data of 46 familial IgAN cases for putatively pathogenic *COL4A3-5* variants.

We report notable ES results from 12 of these 46 familial cases. These 12 families were ascertained through a proband with biopsy-proven IgAN who was referred for evaluation of familial IgAN for having at least 1 other family member with known IgAN, chronic kidney disease of undetermined etiology, or hematuria (Figure 1). IgAN was diagnosed based on a kidney biopsy specimen showing mesangial expansion and/or proliferation with IgA-dominant deposits. Electron microscopy was available for 1 case. We excluded from analysis individuals with a personal and/or family history of clinical features potentially consistent with type IV collagen-associated nephropathy, including hearing loss, and visual impairment (Supplementary



**Figure 1.** IgA nephropathy (IgAN) pedigrees with variants in *COL4A3-5*. Genotypes are given for individuals with DNA samples available for genetic analysis. ESRD, end-stage renal disease.

**Table 1.** Putatively pathogenic variants segregating in IgAN families

Family	Gene	cDNA	Peptide change	dbSNP ID	CADD	PP-2	SIFT	MutTaster	GERP	gnomAD AF	Reference
PED1	<i>COL4A4</i>	c.3791G>T	p.G1264V	rs371915593	25	1	D	Dc	5.43	8.03E-06	Novel
PED2	<i>COL4A4</i>	c.2555G>A	p.G852D	NA	24.4	1	D	Dc	5.64	Absent	Novel
PED4	<i>COL4A5</i>	c.3295delT	p.S1099Lfs*53	NA	32	NA	NA	NA	NA	Absent	Novel
PED6	<i>COL4A4</i>	c.2986G>A	p.G996R	rs370474706	24.4	1	D	Dc	5.52	2.81E-05	S3
PED7	<i>COL4A4</i>	c.2420delG	p.G807Vfs*62	NA	35	NA	NA	NA	NA	Absent	S4, S5
PED8	<i>COL4A3</i>	c.898G>A	p.G300R	NA	28.4	1	D	Dc	5.8	Absent	S6–S8
PED9	<i>COL4A3</i>	c.2083G>A	p.G695R	rs200287952	25	1	D	Dc	5.92	Absent	S9–S14
PED10	<i>COL4A5</i>	c.2350G>C	p.G784R	NA	25.3	1	D	Dc	5.75	Absent	Novel
PED11	<i>COL4A5</i>	c.1258G>A	p.G420R	rs1556410266	24.9	1	D	Dc	5.26	Absent	S15

D, damaging; Dc, disease-causing; NA, not applicable; PP-2, Polyphen-2; gnomAD AF, allele frequency (AF) in gnomAD global exome database (with respect to all populations). See [Supplementary Table S2](#) for supporting American College of Medical Genetics and Genomics (ACMG) classification criteria used and [Supplementary References](#) designated with the “S” prefix.

**Methods**). Four patients had previously undergone familial genomewide linkage analysis; in 1 patient, PED2, a suggestive peak was detected at the *COL4A3/4* locus, with a LOD score of 2.2 ([Supplementary Table S1](#)).

Using consensus guidelines for diagnostic sequence interpretation for *COL4A3-5* variants,<sup>5</sup> we identified Pathogenic or Likely Pathogenic variants segregating in 9 families ([Table 1](#),<sup>S3–S15</sup> [Figure 1](#), [Supplementary Table S2](#)). In an additional 3 families, we found segregating rare variants ultimately classified as variants of uncertain significance due to insufficient evidence for pathogenicity ([Supplementary Table S3](#), [Supplementary Figure S1](#)). Of the 9 families with Pathogenic or Likely Pathogenic variants, 6 (67%) demonstrated autosomal dominant inheritance, with 2 harboring heterozygous variants in *COL4A3* and 4 in *COL4A4*; the remaining 3 showed X-linked inheritance, with variants in *COL4A5*. Substitution (missense) mutations affecting highly conserved glycine residues in the triple helical collagenous domain were noted in 7 of the 9 families (78%); the other 2 families (22%) had frameshift variants. Five of the 11 variants had been previously reported to be pathogenic in patients clinically diagnosed with AS or TBMD ([Table 1](#)). Incomplete penetrance was observed among 3 (PED1, PED2, and PED8) of the 6 families with autosomal disease; in contrast, nephropathy was fully penetrant among families with *COL4A5* variants ([Figure 1](#)).

Our study builds on prior reports of an expanded phenotypic spectrum among individuals harboring putatively pathogenic type IV collagen mutations. Although traditionally associated with AS and TBMD, such variants are now being detected among individuals clinically diagnosed with other nephropathies, such as focal segmental glomerulosclerosis (FSGS), and among cases with undiagnosed disease.<sup>6,7,S16,S17</sup> Moreover, several recent case reports have noted putatively pathogenic mutations in these genes among individuals with familial hematuric nephropathy initially diagnosed as IgAN.<sup>S18–S21</sup> To date,

we have found putatively pathogenic *COL4A3-5* mutations in 9 of the 46 familial IgAN cases (20%), a yield similar to that from assessments of patients clinically diagnosed with familial focal segmental glomerulosclerosis for mutations in these genes.<sup>7,S17</sup> As for focal segmental glomerulosclerosis, the majority of cases showed autosomal dominant inheritance, with heterozygous mutations in *COL4A3* and *COL4A4* accounting for 67% (6 of 9) of the positive cases.<sup>7,S17</sup> The greater phenotypic variability noted for autosomal dominant versus X-linked pedigrees, with incomplete penetrance observed in 50% (3 of 6) families with heterozygous *COL4A3* or *COL4A4* variants, is also consistent with prior studies.<sup>5</sup>

The role of type collagen IV mutations in IgAN pathogenesis is unclear. These findings may reflect the limitations of traditional clinical disease classifications, especially for more complex phenotypes. Kidney diseases have traditionally been classified on the basis of clinical symptomatology and histopathology. However, as many nephropathies can have nonspecific and/or heterogenous presentations, each of these can overlap considerably between clinical disease subtypes. Thus, although type IV collagen-associated nephropathy is classically characterized by progressive hematuric renal disease, hearing impairment, and ophthalmologic anomalies, patients may present with isolated hematuria and/or proteinuria, which can be seen across many different types of glomerulopathy, including IgAN.<sup>5</sup> Similarly, albeit consistent with a diagnosis of type IV collagen-associated nephropathy, the histopathologic findings of glomerular basement membrane thinning, splitting, and lamellation have been noted in IgAN patient biopsy specimens,<sup>8,S22,S23</sup> and IgAN has been found concurrently with TBMD.<sup>S24</sup> Thus, type IV collagen mutations may serve as modifying factors for IgAN. Alternatively, based on autopsy series and donor biopsy studies showing mesangial IgA deposition in as many as 16% of asymptomatic individuals, the detection of IgA deposits in the probands may be

coincidental.<sup>9,S25</sup> Although detailed histopathology was unavailable for the majority of our cases, we were able to obtain renal biopsy data for 2 probands: 1 individual from the PED10 family, who was hemizygous for the *COL4A5* p.G784R missense variant, and the other from the PED7 family, who was heterozygous for the *COL4A4* p.G807Vfs\*62 frameshift variant (Supplementary Figure S2). Interestingly, in both cases, glomerular basement membrane thinning was noted, although no clear-cut lamellation or basket-weaving was observed. Given with the observed phenotypic overlap and previous detection of significant linkage signals at the *COL4A3/A4* locus in familial IgAN,<sup>4</sup> our findings encourage additional investigation into a potential shared pathogenesis between these 2 disorders, including among nonfamilial cases.

Our study has notable strengths and important limitations. To our knowledge, our investigation represents the largest-scale report to date of type IV collagen variants in familial IgAN. In our analysis, we not only applied detailed, disease-specific criteria to identify putatively pathogenic *COL4A3/4/5* variants<sup>5</sup> from ES data, but also obtained DNA samples from family members and performed segregation analysis, further supporting their pathogenicity. However, because our ES analysis was retrospective, we had incomplete clinical data for the families assessed, thereby limiting our ability to examine genotype–phenotype relationships. In addition, our study has the technical limitations of ES-based analysis, including the inability to investigate noncoding variants and a low sensitivity for detecting copy-number variation (e.g., exonic deletions), both of which have been found as causal variants for type IV collagen-associated nephropathy.<sup>5</sup> Thus, our findings may underestimate the true prevalence of putatively pathogenic type IV collagen variants in familial IgAN. Future studies integrating genomic and phenotypic data from large, ethnically diverse cohorts of all-cause chronic kidney disease case patients and population controls will support a greater understanding of the phenotypic spectrum and longer-term clinical outcomes associated with type IV collagen mutations, thereby informing diagnostic genetic testing and personalized management for individuals with nephropathy.

## DISCLOSURE

All the authors declared no competing interests.

## ACKNOWLEDGMENTS

This work was supported by National Institutes of Health grants 1F30DK116473 and R01DK082753. We thank all the study participants and physicians for contributing to this effort.

## SUPPLEMENTARY MATERIAL

Supplementary File (PDF)

**Supplementary Methods.**

**Table S1.** Additional clinical and genetic data for the 12 families segregating type IV collagen variants.

**Table S2.** Pathogenic and likely pathogenic variants identified with supporting ACMG classification criteria.

**Table S3.** Variants of uncertain significance (VUS) detected segregating in 3 families.

**Figure S1.** Pedigrees of the 3 families with segregating variants of uncertain significance (VUS).

**Figure S2.** Biopsy data of (A) PED10 and (B) PED7 cases.

**Supplementary References.**

## REFERENCES

- Magistroni R, D'Agati VD, Appel GB, Kiryluk K. New developments in the genetics, pathogenesis, and therapy of IgA nephropathy. *Kidney Int.* 2015;88:974–989.
- Wyatt RJ, Julian BA. IgA nephropathy. *N Engl J Med.* 2013;368:2402–2414.
- Frasca GM, Soverini L, Gharavi AG, et al. Thin basement membrane disease in patients with familial IgA nephropathy. *J Nephrol.* 2004;17:778–785.
- Paterson AD, Liu XQ, Wang K, et al. Genome-wide linkage scan of a large family with IgA nephropathy localizes a novel susceptibility locus to chromosome 2q36. *J Am Soc Nephrol.* 2007;18:2408–2415.
- Savige J, Ariani F, Mari F, et al. Expert consensus guidelines for the genetic diagnosis of Alport syndrome. *Pediatr Nephrol.* 2019;34:1175–1189.
- Groopman EE, Marasa M, Cameron-Christie S, et al. Diagnostic utility of exome sequencing for kidney disease. *N Engl J Med.* 2019;380:142–151.
- Malone AF, Phelan PJ, Hall G, et al. Rare hereditary *COL4A3/4* variants may be mistaken for familial focal segmental glomerulosclerosis. *Kidney Int.* 2014;86:1253–1259.
- Masuda Y, Yamanaka N, Ishikawa A, et al. Glomerular basement membrane injuries in IgA nephropathy evaluated by double immunostaining for alpha5(IV) and alpha2(IV) chains of type IV collagen and low-vacuum scanning electron microscopy. *Clin Exp Nephrol.* 2015;19:427–435.
- Suzuki K, Honda K, Tanabe K, et al. Incidence of latent mesangial IgA deposition in renal allograft donors in Japan. *Kidney Int.* 2003;63:2286–2294.