

Insulinoma Identified in Puerperium: Association with Pregnancy and Literature Review

Rossana Orabona^{1,2}, Cristina Zanardini², Andrea Lojacono^{1,2}, Sonia Zatti², Carlo Cappelli³,
Guido AM Tiberio⁴, Vincenzo Villanacci⁵, Enrico Sartori^{1,2}

¹ Department of Clinical and Experimental Sciences, University of Brescia, Brescia, Italy

² Obstetrics and Gynecology, ASST Spedali Civili, Brescia, Italy

³ Department of Clinical and Experimental Sciences, Endocrine and Metabolic Unit, Medical Clinic, University of Brescia, Brescia, Italy

⁴ Department of Molecular and Translational Medicine, ASST Spedali Civili, Third Division of General Surgery, University of Brescia, Italy

⁵ Institute of Pathology, ASST Spedali Civili, Brescia, Italy

Doi: 10.12890/2020_001556 - European Journal of Case Reports in Internal Medicine - © EFIM 2020

Received: 05/02/2020

Accepted: 11/02/2020

Published: 16/03/2020

How to cite this article: Orabona R, Zanardina C, Lojacono A, Zatti S, Cappelli C, Tiberio GAM, Villanacci V, Sartori E. Insulinoma identified in puerperium: association with pregnancy and literature review. *EJCRIM* 2020;7: doi:10.12890/2020_001556.

Conflicts of Interests: The Authors declare that there are no competing interests.

This article is licensed under a Commons Attribution Non-Commercial 4.0 License

ABSTRACT

Postpartum hypoglycemia in non-diabetic women is a rare condition. We report the case of a 34-year-old woman who experienced neuroglycopenia 2 days after delivery. Corresponding to severe hypoglycemia, we found inappropriately elevated insulin and C-peptide levels. Following magnetic resonance imaging a lesion of 10x8 mm was detected in the head of the pancreas. An ultrasound-guided fine needle aspiration of the mass confirmed the diagnostic suspicion of a pancreatic neuroendocrine tumor. Complete surgical enucleation of the insulinoma resulted in immediate and permanent resolution of the hypoglycemia. The postoperative course was uneventful. Histopathological and immunohistochemical analyses were consistent with insulinoma. The diagnostic approach to postpartum hypoglycemia represents a challenge for multidisciplinary teamwork.

LEARNING POINTS

- Although insulinomas are extremely rare during pregnancy, most cases are recognized or become symptomatic during the first trimester.
- Symptoms of insulinomas may be initially masked due to changes in glucose metabolism and insulin resistance associated with pregnancy.
- In pregnancy, surgical treatment should be avoided whenever possible because of the risks to both mother and fetus; conservative treatment, including dietary intake, intravenous glucose and glucagon, should be initiated to control the hypoglycemia symptoms.

KEYWORDS

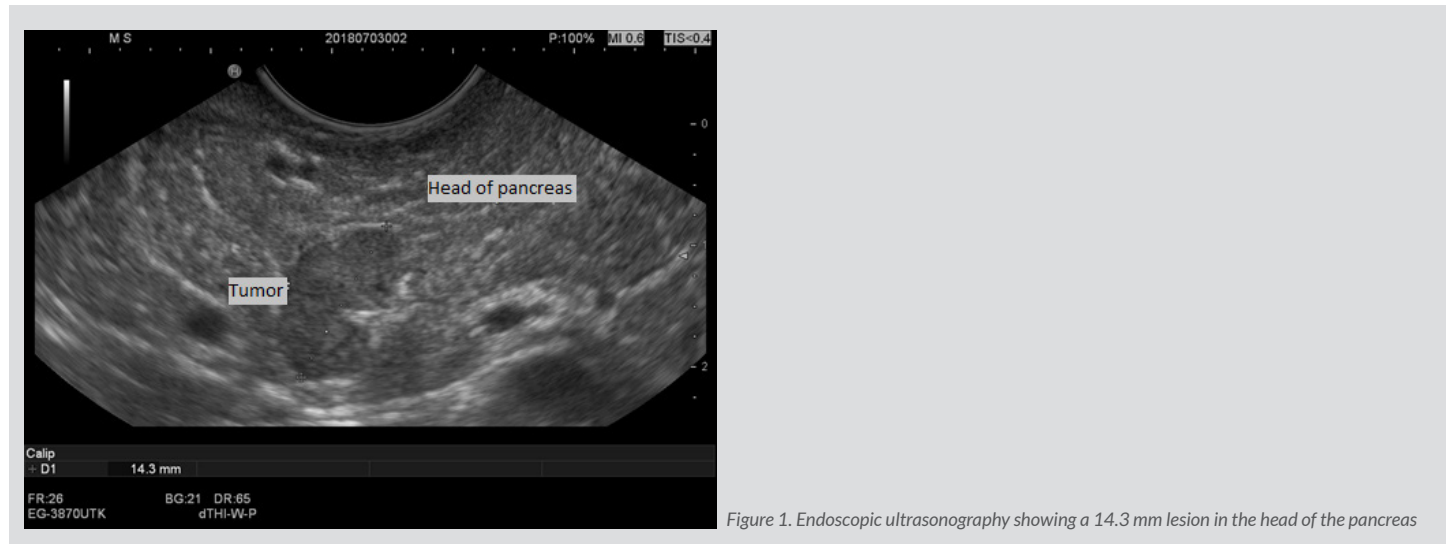Neuroendocrine tumor, hypoglycemia, pregnancy, postpartum, insulinoma, puerperium, neuroglycopenia

CASE DESCRIPTION

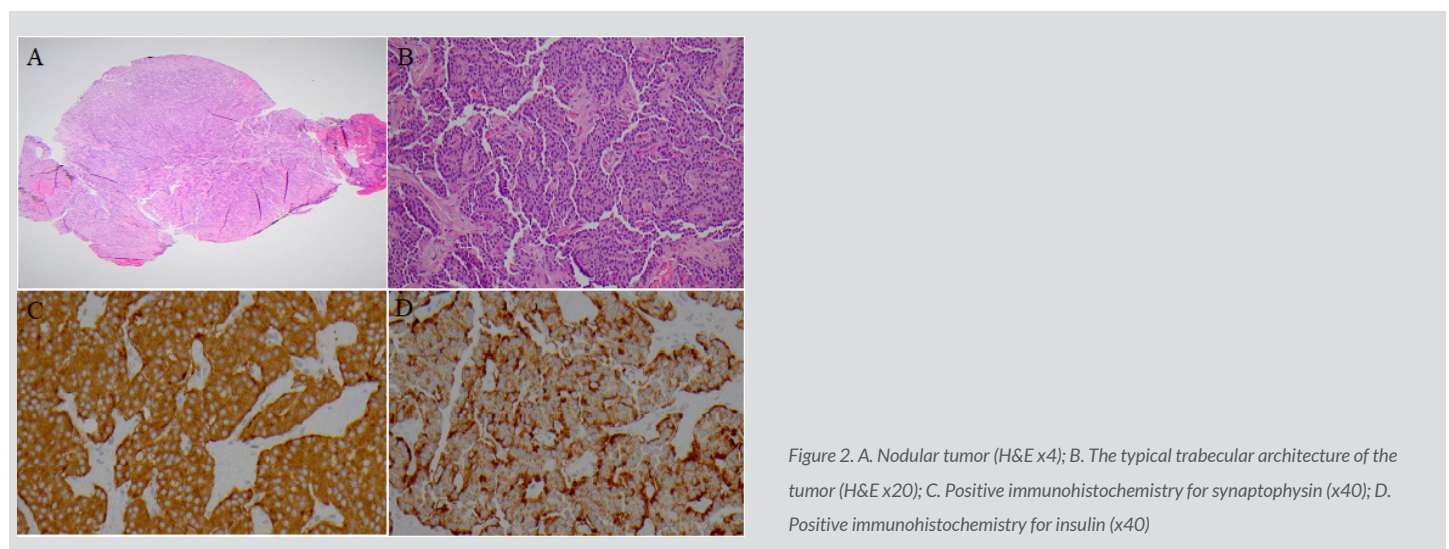
A 34-year-old female with an unremarkable past medical history presented with symptoms of general weakness, sweating, tremors and visual changes 2 days postpartum; the pregnancy was uncomplicated and she gave birth to a female baby in good health at full term. Blood analysis revealed severe hypoglycemia (36 mg/dL), while a cerebral computed tomography (CT) scan excluded neurological disorders. The patient recovered promptly with intravenous glucose administration, thus fulfilling Whipple's triad.

She was referred to our department for endocrine work-up, as her condition was consistent with insulinoma, showing elevated insulin concentrations (43.2 μ U/mL) and C-peptide levels (4.9 ng/mL). Tests for anti-insulin antibodies were negative. Calcium, phosphorus and potassium levels were normal, which excluded hyperparathyroidism. Together with the absence of a family history of endocrinopathies,

these findings made the diagnosis of multiple endocrine neoplasia type 1 (MEN 1) highly unlikely. Abdominal ultrasound was normal, while magnetic resonance imaging (MRI) showed an isolated enhancing lesion measuring 10x8 mm localized in the head of the pancreas. An ultrasound-guided fine needle aspiration, by means of transesophageal echoendoscopy (Fig. 1), of the mass confirmed the diagnostic suspicion of a pancreatic neuroendocrine tumor.



After a multidisciplinary team evaluation, the patient underwent laparoscopic enucleation of the insulinoma (surgical exploration revealed that the lesion was deeper than expected and thus laparoscopy became laparotomy), resulting in immediate and permanent resolution of hypoglycemia, with no further treatment required. Immunohistochemistry of the lesion showed a positive result for synaptophysin, confirming the neuroendocrine origin of the tumor, while immunohistochemistry for insulin also confirmed the insulinoma (Fig. 2). She was discharged with a planned clinical and imaging follow-up, of abdominal ultrasound and CT. Twelve months after surgery, the patient currently remains euglycemic, with no signs of relapse or other complaints.



DISCUSSION

Insulinomas are functional neuroendocrine tumors derived from the beta cells of the pancreatic islets of Langerhans, usually solitary, benign and curable with surgery (enucleation), and which cause non-ketotic hypoglycemia. It has an estimated incidence of four cases per million person-years. Although insulinomas are extremely rare during pregnancy, most cases are recognized or become symptomatic during the first trimester. Insulinomas are the most frequent functioning endocrine pancreatic tumors, which may present as malignant in 10% of cases. About 10% of insulinomas are associated with MEN 1^[1-3].

Clinical manifestations of insulinomas were first described by Whipple and Frantz and consist of a triad composed of hypoglycemic fasting symptoms, plasma glucose <50 mg/dL, and relief of symptoms after intravenous glucose administration^[4]; the diagnosis is confirmed by the presence of inadequately high serum insulin levels^[5]. During the insulin peak produced by these tumors, patients may present with adrenergic symptoms, especially sweating, tremors, hyperphagia and palpitations^[6, 7]. In addition, neuroglycopenic symptoms may also occur, including mental confusion, visual changes, convulsions, and changes in level of consciousness^[8]. Although in diabetic women iatrogenic hypoglycemia is the most frequent cause of low blood glucose levels, in non-diabetic patients insulinoma should be included in the differential diagnoses of postpartum hypoglycemia comprising ischemic pituitary necrosis due to severe postpartum hemorrhage (Sheehan's syndrome); acute fatty liver of pregnancy; autoimmune conditions (e.g. autoimmune insulin syndrome); organ failure; endocrine diseases (e.g. isolated adrenocorticotropic hormone (ACTH) deficiency or combined ACTH and growth hormone deficiency); dietary toxins; and miscellaneous conditions (e.g. sepsis, starvation and severe excessive exercise)^[9]. This case illustrates how the symptoms of insulinomas may be initially masked due to changes in glucose metabolism and insulin resistance associated with pregnancy. Historically, placental hormones (e.g. human placental lactogen), cortisol, tumor necrosis factor alpha, and leptin are considered the primary mediators of insulin resistance during gestation^[10, 11]. Our patient was asymptomatic throughout gestation and only developed neuroglycopenic symptoms after delivery, similar to two previous cases^[12, 13]. Nonspecific symptoms such as dizziness or drowsiness might be due to hypoglycemia; therefore, it is important to check Whipple's triad to rule out an insulinoma.

Biochemical diagnosis of insulinoma is confirmed by the inadequate elevation of insulin during a spontaneous or induced hypoglycemic episode; serum C-peptide elevation maybe useful in excluding causes related to the exogenous use of insulin.

After clinical and biochemical diagnosis, the lesion should be located by diagnostic imaging in order to plan the most appropriate therapeutic approach. Abdominal ultrasound is performed as the initial examination but its sensitivity varies between 20 and 60%^[14] and is higher for lesions greater than 5 mm^[15]. CT and MRI have higher sensitivity, while ultrasonographic endoscopy is an invasive method that allows a concomitant biopsy with fine needle aspiration for histopathological study.

Surgery is still the only curative treatment for pancreatic neuroendocrine tumors: enucleation is the technique of choice in single well-defined lesions smaller than 2 cm; when lesions are larger than 2 cm or malignancy suspected it is recommended to opt for pancreatic resection techniques (e.g. distal pancreatectomy, central pancreatectomy, and cephalic and total gastroduodenopancreatectomy)^[16].

In the literature, there are eight reports of patients being surgically treated for pancreatic insulinomas in pregnancy^[17]. In particular, surgery was performed in three cases in the first and in the second trimesters, respectively, and in two patients at the time of cesarean section or soon after labor induction. In pregnancy, surgery should be avoided whenever possible because of the risks to both mother and fetus. Conservative treatment, including dietary intake, intravenous glucose and glucagon (its use is not contraindicated during pregnancy and lactation), should be initiated to control the hypoglycemia symptoms.

Cases of insulinoma during pregnancy are rare, as reflected in the limited number reported in the literature. We therefore wish to add a further case of severe and symptomatic postpartum hypoglycemia due to insulinoma.

REFERENCES

1. Service FJ, McMahon MM, O'Brien PC, Ballard DJ. Functioning insulinoma – incidence, recurrence, and long-term survival of patients: a 60-year study. *Mayo Clin Proc* 1991;**66**(7):711–719.
2. Abu-Zaid A, Alghuneim LA, Metawee MT, Elkabbani RO, Almana H, Amin T, et al. Sporadic insulinoma in a 10-year-old boy: a case report and literature review. *JOP* 2014;**15**(1):53–57.
3. Miron I, Diaconescu S, Aprudu G, Ioniuc I, Diaconescu MR, Miron L. Diagnostic difficulties in a pediatric insulinoma: a case report. *Medicine (Baltimore)* 2016; **95**(11):e3045.
4. Whipple AO, Frantz VK. Adenoma of islet cells with hyperinsulinism: a review. *Ann Surg* 1935;**101**(6):1299–1335.
5. Hirshberg B, Livi A, Bartlett DL, Libutti SK, Alexander HR, Doppman JL, et al. Forty-eight-hour fast: the diagnostic test for insulinoma. *J Clin Endocrinol Metab* 2000;**85**(9):3222–3226.
6. Apodaca-Torrez FR, Triviño T, Lobo EJ, Goldenberg A, Figueira A. Insulinomas do pâncreas: diagnóstico e tratamento. *Arq Gastroenterol São Paulo* 2003;**40**(2):73–79.
7. Masciocchi M. Pancreatic imaging. *Endocrinol Metab Clin N Am* 2017;**46**:761–781.
8. Okabayashi T, Shima Y, Sumiyoshi T, Kozuki A, Ito S, Ogawa Y, et al. Diagnosis and management of insulinoma. *World J Gastroenterol* 2013;**19**(6):829–837.
9. Persson B, Hansson U. Hypoglycaemia in pregnancy. *Baillière's Clin Endocrinol Metab* 1993;**7**(3):731–799.
10. Ryan EA, Enns L. Role of gestational hormones in the induction of insulin resistance. *J Clin Endocrinol Metab* 1988;**67**(2):341–347.
11. Kirwan JP, Hauguel-De Mouzon S, Lepercq J, Challier JC, Huston-Presley L, Friedman JE, et al. TNF-alpha is a predictor of insulin resistance in human pregnancy. *Diabetes* 2002;**51**(7):2207–2213.
12. Diaz AG, Herrera J, López M, Puchulu FM, Ferraina P, Bruno OD. Insulinoma associated with pregnancy. *Fertil Steril* 2008;**90**(1):199.e1–e4.
13. Müssig K, Wehrmann M, Horger M. Insulinoma and pregnancy. *Fertil Steril* 2009;**91**(2):656.
14. Piraka C, Scheiman JM. New diagnostic imaging modalities for pancreatic disease. *Curr Opin Gastroenterol* 2011;**27**(5):475–480.
15. Mehrabi A, Fischer L, Hafezi M, Dirlwanger A, Grenacher L, Diener MK, et al. A systematic review of localization, surgical treatment options, and outcome of insulinoma. *Pancreas* 2014;**43**(5):675–686.
16. Lee J, Allendorf J, Chabot J. Surgical resection of sporadic pancreatic neuroendocrine tumors. UpToDate 2017.
17. de Albuquerque Neto CC, da Silva Lira N, Albuquerque MARC, Santa-Cruz F, França M Vasconcelos L, Ferraz AAB, et al. Surgical resection of pancreatic insulinoma during pregnancy: case report and literature review. *Int J Surg Case Rep* 2019;**61**:119–122.