

---

**SURGICAL TECHNIQUE**

---

# Outcomes of conjunctival compression sutures for hypotony after glaucoma filtering surgery

Luciano Quaranta<sup>1</sup>, Ivano Riva<sup>1</sup>, Irene C. Floriani<sup>2</sup>

<sup>1</sup> Department of Ophthalmology, University of Brescia, Brescia - Italy

<sup>2</sup> Laboratory of Clinical Research, Istituto di Ricerche Farmacologiche "Mario Negri" IRCCS, Milan - Italy

---

**Purpose:** To evaluate the outcomes of conjunctival compression sutures (CCS) for enlarged overfiltering blebs associated with ocular hypotony after uncomplicated trabeculectomy with mitomycin C (TM).

**Methods:** A retrospective analysis of consecutively recruited patients with enlarged conjunctival bleb associated with hypotony who had undergone CCS was performed. Patients were considered for CCS if they had enlarged overfiltering bleb for at least 4 weeks, following an uncomplicated TM, with no sign of resolution. Only patients with hypotony, defined as intraocular pressure (IOP) <6 mm Hg associated with a reduced vision of at least 2 lines, were included. Success was defined as an IOP >6 mm Hg 6 months after surgery.

**Results:** A total of 45 eligible patients were identified. In 29 eyes of 45 patients (64.4%), success in providing resolution of the preexisting hypotony (postoperative IOP mean  $\pm$  standard deviation 13.4  $\pm$  1.8 mm Hg, range 10-16 mm Hg) was obtained. Out of these 29 eyes, 9 eyes had a conjunctival bleb diffusion over 180 degrees, 19 eyes overfiltering bleb over 270 degrees, and 1 eye over 360 degrees. Complications from CCS included a transient spike of IOP in the first postoperative week (8 patients); a bleb rupture associated with conjunctival leaks and hypotony was observed in one eye.

**Conclusions:** The placement of CCS is a safe and effective technique for managing overfiltering blebs associated with hypotony. The present study suggests that CCS are not effective for dealing with circumferential blebs extending over 360 degrees.

**Keywords:** Complications, Compression Sutures, Glaucoma, Hypotony, Trabeculectomy

---

Accepted: February 26, 2013

## INTRODUCTION

At present, the use of antifibrotic agents as an adjunct to trabeculectomy has resulted in lower intraocular pressure (IOP) control over long-term follow-up, but at the price of a concomitant increase of complications (1-6). After trabeculectomy with mitomycin C (TM), extremely low IOP with excess of conjunctival filtration may cause hypotonous maculopathy, especially in the early postoperative period (7-11).

Diffusely enlarged blebs tend to result from overfiltration and can be associated with a significant reduction in visual acuity due to ocular hypotony (10, 11). The treatment of

hypotony due to overfiltering blebs includes cryotherapy (12), autologous blood injection (13), and resuturing the scleral flap (14, 15), each of which is associated with an increasing risk of postoperative complications, and failure of IOP control. Conjunctival compression sutures (CCS) have been used alone (16, 17) or in association with autologous blood injection (18) to induce adherence of conjunctiva to the underlying scleral tissue. This procedure has been reported to be effective for the management of ocular hypotony following TM.

In the present retrospective study, we report the outcomes of CCS for enlarged overfiltering blebs associated with ocular hypotony after uncomplicated TM.

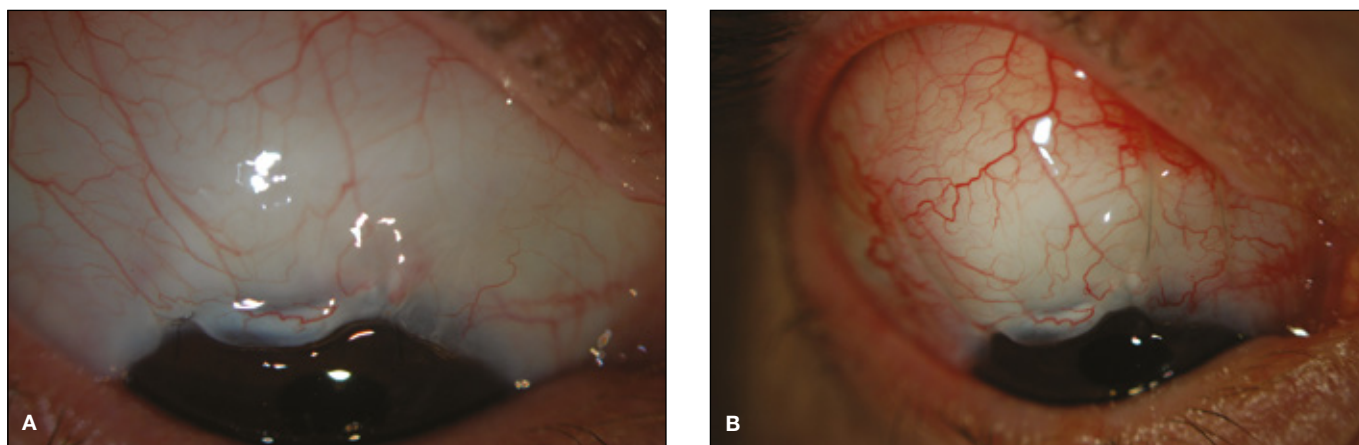


Fig. 1 - Bleb appearance before (A) and after (B) conjunctival compression sutures.

## METHODS

A retrospective analysis of consecutively recruited patients of the Glaucoma Service of the University of Brescia with enlarged conjunctival bleb associated with hypotony who had undergone placement of CCS was performed. Patients were considered for the surgical procedure if they had enlarged overfiltering bleb for at least 4 weeks, following an uncomplicated TM (mitomycin C 0.3 mg/mL intraoperatively applied for 3 minutes) with no sign of resolution. Only patients with hypotony, defined as IOP <6 mm Hg associated with reduced vision of at least 2 lines, and who had greater than 6 months of follow-up were included.

Following informed consent, topical anesthesia was achieved using 1% amethocaine drops delivered 10 minutes before surgery. After conjunctival anesthesia was obtained, a 9-0 nylon suture (Alcon Surgical SpA, Milan, Italy) was placed just anterior to the limbus at a corneal stroma depth of 50%; the suture then courses posteriorly to compress the underlying conjunctiva on either side of the central portion of the filtration bleb, and is anchored using a deep bite in the conjunctiva and Tenon capsule. In order to facilitate posterior suture, patients were asked to look inferiorly as much as possible. In 12 cases, a 6.0 silk traction suture was placed in the cornea at 12 o'clock position to rotate the globe inferiorly and achieve sufficient posterior exposure. The suture ends were tied to obtain the required degree of conjunctival compression. A second suture was then placed on the other side of the conjunctival bleb, at distance of about 6 mm from the other CCS. Chloramphenicol 0.5%

drops were given 4 times a day and topical steroids were given only twice a day to encourage scarring at the site of the CCS (Fig. 1).

As is customary in our clinical practice, patients were examined on the first postoperative day and then weekly until CCS were in place. After CCS removal, patients were followed every month during the first 6 postoperative months. The CCS were kept in place for at least 6 weeks, and then removed at different times when scarring lines were seen on the conjunctiva, or the sutures became loose. Clinical information was derived from charts including demographic information, diagnosis, and type and date of original glaucoma surgery; operative and postoperative course were reviewed with documentation of visual acuity, IOP, complications.

Success was defined as an IOP >6 mm Hg 6 months after surgery.

## RESULTS

From January 1998 to January 2012, 45 consecutive patients met the inclusion criteria defined by the study protocol. Table I shows clinical features of the patients included.

The CCS were placed on average 10 weeks after TM (range 8-14), and removed on average after 12 weeks (range 6-20). The sutures were buried in the conjunctiva spontaneously in 1 to 3 weeks (5 eyes). Success was obtained in 29 eyes of 45 patients (64.4%), in providing resolution of the preexisting hypotony (postoperative

**TABLE I - PATIENT CHARACTERISTICS**

Characteristics	Values
No. of patients (eyes)	45
Mean age, y (SD)	61 (4.5)
Male, n (%)	30 (40.7)
Preoperative IOP, mm Hg (SD)	2.9 (1.39)
Conjunctival bleb diffusion, no. eyes	
180 degrees	10
270 degrees	20
360 degrees	15
Diagnosis, no. eyes	
Primary open-angle glaucoma	35
Pigmentary glaucoma	3
Pseudoexfoliative glaucoma	5
Chronic angle closure glaucoma	2

IOP = intraocular pressure.

**TABLE II - RESULTS: SUCCESS AND CONJUNCTIVAL BLEB DIFFUSION**

Conjunctival bleb diffusion	Success (IOP >6 mm Hg), n (%) eyes
180 degrees	9/10 (90)
270 degrees	19/20 (95)
360 degrees	1/15 (6.6)
Total	29/45 (64.4)

IOP = intraocular pressure.

IOP mean ± standard deviation: 13.4 ± 1.8 mm Hg, range 10-16 mm Hg). Of these 29 eyes, 9 eyes had a conjunctival bleb diffusion over 180 degrees, 19 eyes overfiltering bleb over 270 degrees, and 1 eye over 360 degrees. In 22 cases, an improvement of visual acuity was recorded (preoperative and postoperative Snellen visual acuity, mean ± standard deviation: 0.48 ± 0.14 and 0.75 ± 0.13, respectively; paired t test: p<0.001). In the remaining 7 eyes, in spite of a postoperative increase of the IOP (ranging from 12 to 14 mm Hg), visual acuity did not improve. This was mainly due to the persistence of macular folds (Tab. II).

In 16 cases (35.5%), CCS were not effective in reducing aqueous overfiltration and restoring normal IOP levels (IOP >6 mm Hg) after 4-6 weeks following sutures placement. These patients underwent surgical revision of the filtra-

tion bleb, by resuturing the scleral flap (postoperative IOP mean ± standard deviation: 15.6 ± 1.2 mm Hg, range 14-18 mm Hg). Success was obtained in all the treated eyes, but in 6 cases additional topical hypotensive medical therapy was required in order to control the IOP.

Eight patients had a transient spike of IOP (ranging from 23 to 26) in the first postoperative week. The IOP spikes were mainly observed on the first operative day. Bleb rupture associated with conjunctival leaks and hypotony was observed in 1 eye.

## DISCUSSION

Hypotony caused by excessive bleb filtration usually resolves with routine postoperative medical management (19). Thus, the initial management of postoperative hypotony with a formed anterior chamber and overdraining conjunctival bleb is conservative. Our patients were carefully selected as those with prolonged conjunctival chemosis and hypotony; it is unlikely that our results may be due to spontaneous resolution. In our series, CCS technique was able to provide resolution of the preexisting hypotony in 64.4% of cases.

Our results suggest CCS to be more effective and indicated for blebs that do not exceed 270 degrees. Since antiproliferative agents had been used in this series, CCS had been applied to sectors of the conjunctiva in which fibroblasts are viable and able to make a sufficient healing response. It has been suggested that the sutures may have also a role in the management of acellular blebs, since they have been reported to thicken bleb tissue and to promote vascularity (16).

A major advantage of this technique is that it is minimally invasive, and does not preclude any further surgery, should the procedure be unsuccessful. Transient IOP spikes in the early postoperative period were recorded in 8 eyes; these were generally small, but should be carefully monitored and eventually managed by a gentle bleb massage or, if persistent, removing one of the 2 CCS. In all of our cases, IOP spikes spontaneously resolved within the first postoperative week, with no need for CCS removal.

Bleb rupture associated with conjunctival leaks was observed in one eye. This was probably due to the fact that a suture was placed in avascular and thin area of the bleb. As a general rule, CCS should always be positioned away from avascular area of the bleb in order to promote an

effective scarring and avoid perforation of the bleb. In case of circumferential bleb (i.e., over 360 degrees), CCS seems to be ineffective in remodeling the filtration bleb, and restoring normal levels of IOP. In these cases, CCS could be supplemented with autologous blood injection. This procedure has been reported to be effective in remodeling enlarged dysmorphic filtration bleb (18).

More recently, good results have been reported in suturing the scleral flap directly through the conjunctival flap, in cases of hypotony caused by excess filtration after trabeculectomy (15). This technique, reported in a small case series (10 eyes), seems to be more invasive and traumatic, especially in the presence of avascular and thin conjunctival blebs.

In conclusion, the placement of CCS is a safe and effective technique for managing overfiltering blebs associated with

hypotony. The present study suggests that CCS are not effective for dealing with circumferential blebs extending over 360 degrees.

**Financial Support:** None.

**Conflict of Interest Statement:** The authors report no proprietary interest.

Address for correspondence:  
Prof. Luciano Quaranta  
USVD "Centro per lo studio del Glaucoma"  
Piazzale Spedali Civili 1  
25123 Brescia  
Italy  
quaranta@med.unibs.it

---

## REFERENCES

1. Wilkins M, Indar A, Wormald R. Intra-operative mitomycin C for glaucoma surgery. *Cochrane Database Syst Rev* 2005; 4:CD002897.
2. Wormald R, Wilkins MR, Bunce C. Post-operative 5-Fluorouracil for glaucoma surgery. *Cochrane Database Syst Rev* 2001;3:CD001132.
3. Jampel HD, Musch DC, Gillespie BW, Lichter PR, Wright MM, Guire KE; Collaborative Initial Glaucoma Treatment Study Group. Perioperative complications of trabeculectomy in the collaborative initial glaucoma treatment study (CIGTS). *Am J Ophthalmol* 2005;140:16-22.
4. AGIS Investigators. The Advanced Glaucoma Intervention Study (AGIS): 11. Risk factors for failure of trabeculectomy and argon laser trabeculoplasty. *Am J Ophthalmol* 2002;134:481-98.
5. The Fluorouracil Filtering Surgery Study Group. Five-year follow-up of the fluorouracil filtering surgery study. *Am J Ophthalmol* 1996;121:349-66.
6. Jampel HD, Solus JF, Tracey PA, et al. Outcomes and bleb-related complications of trabeculectomy. *Ophthalmology* 2012;119:712-22.
7. Greenfield DS, Liebmann JM, Jee J, Ritch R. Late-onset bleb leaks after glaucoma filtering surgery. *Arch Ophthalmol* 1998;116:443-7.
8. Ticho U, Ophir A. Late complications after glaucoma filtering surgery with adjunctive 5-fluorouracil. *Am J Ophthalmol* 1993;115:506-10.
9. Stamper RL, McMenemy MG, Lieberman MF. Hypotonous maculopathy after trabeculectomy with subconjunctival 5-fluorouracil. *Am J Ophthalmol* 1992;114:544-53.
10. Costa VP, Wilson RP, Moster MR, Schmidt CM, Gandham S. Hypotony maculopathy following the use of topical mitomycin C in glaucoma filtration surgery. *Ophthalmic Surg* 1993;24:389-94.
11. Zacharia PT, Deppermann SR, Schuman JS. Ocular hypotony after trabeculectomy with mitomycin C. *Am J Ophthalmol* 1993;116:314-26.
12. Costa VP, Smith M, Spaeth GL, Gandham S, Markovitz B. Loss of visual acuity after trabeculectomy. *Ophthalmology* 1993;100:599-612.
13. Leen MM, Moster MR, Katz LJ, Terebuh AK, Schmidt CM, Spaeth GL. Management of overfiltering and leaking blebs with autologous blood injection. *Arch Ophthalmol* 1995;113:1050-5.
14. Eha J, Hoffmann EM, Wahl J, Pfeiffer N. Flap suture: a simple technique for the revision of hypotony maculopathy following trabeculectomy with mitomycin C. *Graefes Arch Clin Exp Ophthalmol* 2008;246:869-74.
15. Shirato S, Maruyama K, Haneda M. Resuturing the scleral flap through conjunctiva for treatment of excess filtration. *Am J Ophthalmol* 2004;137:173-4.
16. Palmberg P, Zacchei A. Compression sutures: a new treatment for leaking or painful filtering blebs. *Invest Ophthalmol Vis Sci* 1996;37:ARVO abstract 444.
17. Palmberg P. Late complications after glaucoma filtering surgery. In: Leader B, Calckwood J, eds. *Proceedings of the 45th Annual Symposium of the New Orleans Academy of Ophthalmology*. The Hague: Kugler Publications; 1996.
18. Morgan JE, Diamond JP, Cook SD. Remodelling the filtration bleb. *Br J Ophthalmol* 2002;86:872-5.
19. Azuara-Blanco A, Katz LJ. Dysfunctional filtering blebs. *Surv Ophthalmol* 1998;43:93-126.