Arch Orthop Trauma Surg (1985) 104:164–174

Archives of Orthopaedic
and Traumatic Surgery

Involvement of Metal Particles in Loosening of Metal-Plastic Total Hip Prostheses

U. E. Pazzaglia[1], L. Ceciliani[1], M. J. Wilkinson[3], and C. Dell'Orbo[2]

[1] Institute of Orthopedics and [2] Institute of Anatomy of the University of Pavia, Via Taramelli, I-27100 Pavia, Italy
[3] Institute of Orthopaedics (University of London), Brockley Hill, Stanmore, Middlesex HA7 4LP, United Kingdom

Summary. Four loosened metal-on-plastic total hip prostheses and associated tissues were examined. Each implant showed an uncommonly high formation of metal particles produced by wear or corrosion of the femoral stem. The granulation tissue between bone and cement was characterized by macrophages containing metal particles. Histological, histochemical, and ultrastructural investigations have been performed to assess cellular reactions to ingested metal particles. Pathogenesis of loosening in these cases is discussed in relation to the role of macrophages in bone resorption.

Zusammenfassung. Von 4 gelockerten Hüftgelenktotalendoprothesen wurden die aus Metall und Polymer/Kunststoff bestehenden Implantate und das umgebende Gewebe untersucht. Bei allen Implantaten fanden sich ungewöhnlich reichlich Metallpartikeln, die durch Abrieb oder Korrosion des Femurstiels entstanden waren. Das Granulationsgewebe zwischen Knochen und Zement war charakterisiert durch Makrophagen, die Metallpartikeln enthielten. Es wurden histologische, histochemische und ultrastrukturelle Untersuchungen durchgeführt, um die zellulären Reaktionen auf die gespeicherten Metallpartikeln zu erfassen. Die Pathogenese der Lockerung in diesen Fällen wird in Zusammenhang mit der Rolle von Makrophagen bei der Knochenresorption diskutiert.

Wear particles released from the articulating surface of total joint prostheses initially accumulate in the adjacent neosynovial tissue. The reaction of this tissue to wear debris has been widely studied, mainly by light microscopy of sections prepared from specimens obtained at the time of implant removal or revision. These observations have implicated adverse tissue responses to particulate material as a factor in prosthetic loosening [2, 4, 5, 8, 13, 16, 18, 30].

An abundance of metallic debris is especially associated with wear of the cup and head of metal-on-metal hip prostheses. Such prostheses suffer a high incidence of failure through loosening, and a number of factors may be involved, including metal sensitivity [3, 14, 17, 26], and phagocytosis of metal particles [17].

The quantity and effects of wear debris liberated by metal-on-plastic hip prostheses with a wear-resistant cup of high-density polyethylene are usually much less dramatic. Nevertheless, both polymeric and metallic debris have been observed in inflammatory tissues surrounding this type of prosthesis [1, 8, 20, 28, 30].

The tissue reaction to a mixed population of plastic and metallic wear particles is determined by factors such as particle size, morphology, and chemical composition [5, 24, 26]. Large polymeric particles on the order of 1 μm are usually surrounded by foreign-body giant cells or encapsulated within fibrous tissue. Smaller polymeric particles and most metallic debris are phagocytosed by macrophages [12, 20, 21, 31].

Wear debris may be removed from the site of release by lymphatic drainage or stored within a granulomatous tissue [19]. Extensive evidence has been obtained to support the view that the balance between particle production and particle transport and storage may be upset by excessive wear, usually of the polymeric cup. This leads to an extension of foreign-body granulation tissue along the fibrous capsule at the bone-cement interface, with consequent bone resorption and loosening of the prosthesis [5, 22, 30].

Reprint requests to: Ugo E. Pazzaglia (see above address)

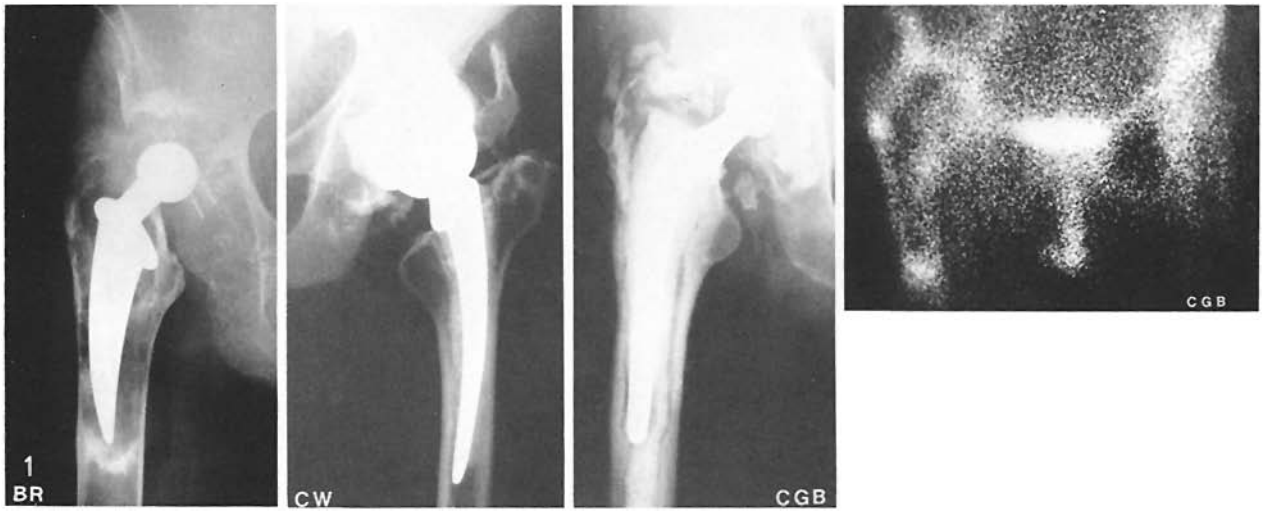

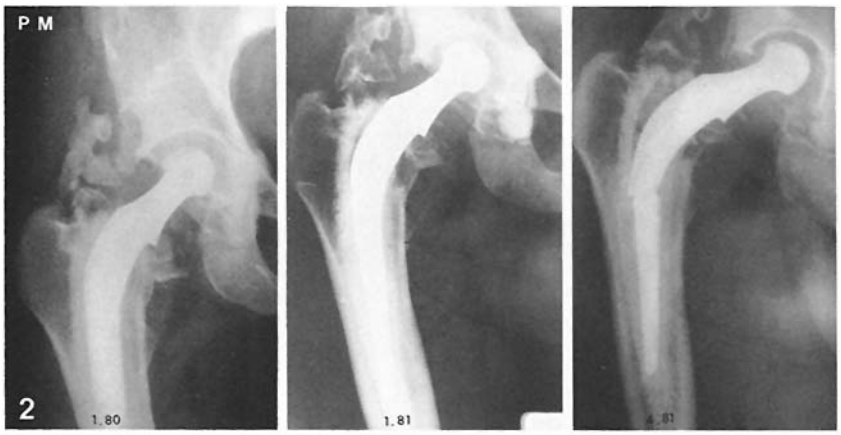

Fig. 1. Roentgenograms and scintigraphy of the removed prostheses. *BR* A radio-transparent cement was used, but loosening is nontheless evident because the stem has sunk in the diaphysis. *CGB* A bilateral arthroplasty was performed. Only the loose prosthesis shows ipercaptation

Fig. 2. Resorption of the calcar with progressive bending and fracture of the stem (Jan. 1980–April 1981)

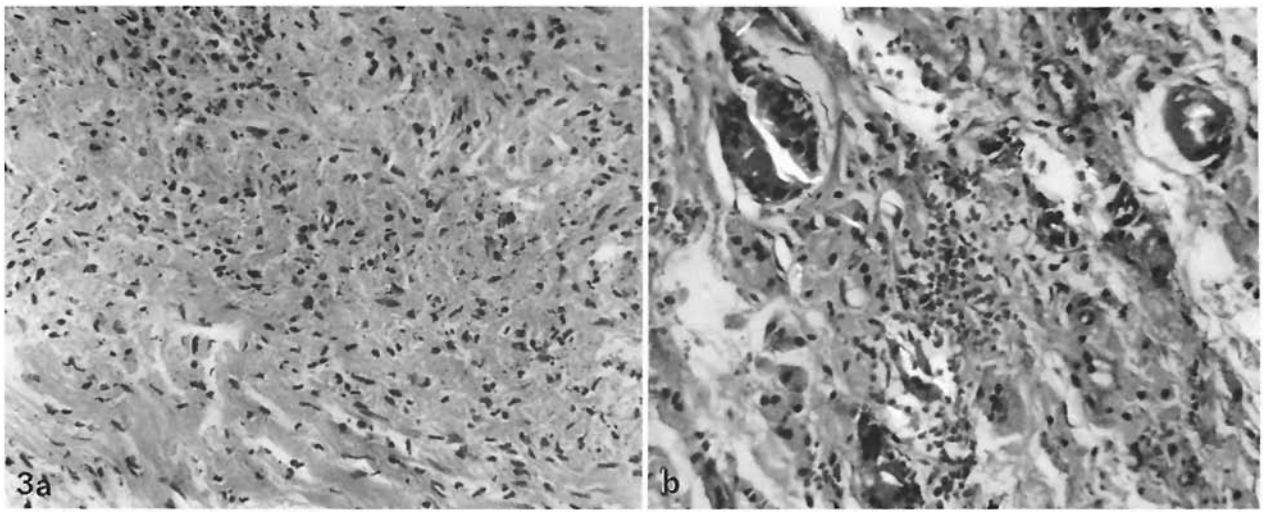

Fig. 3a, b. Tissue adjacent to the cup and the head; H&E. **a** Mononuclear histiocytes with many black particles; × 83. **b** Large, strongly birefringent polyethylene fibers engulfed by multinucleated giant cells; × 210

In contrast, this paper considers cases of loosening of metal-plastic hip prostheses in relation to cellular reactions due to metal particles released from the femoral stem as a result of abrasion and corrosion.

Case Reports

1. *CGB, male, aged 70.* In October 1970 a bilateral Charnley stainless-steel hip arthroplasty for osteoarthritis was perform-

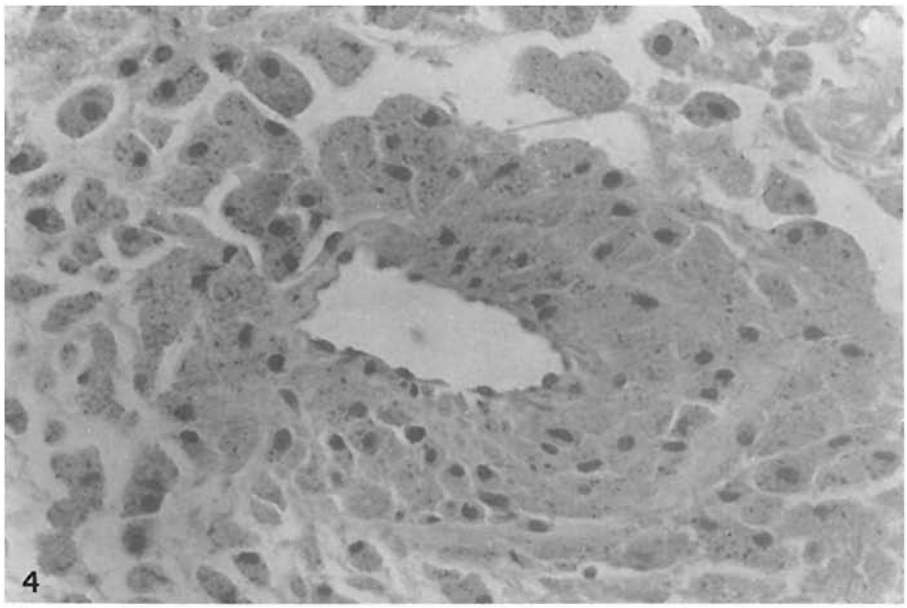

Fig. 4. Mononuclear histiocytes with many black particles surrounding a vessel. H & E; × 300

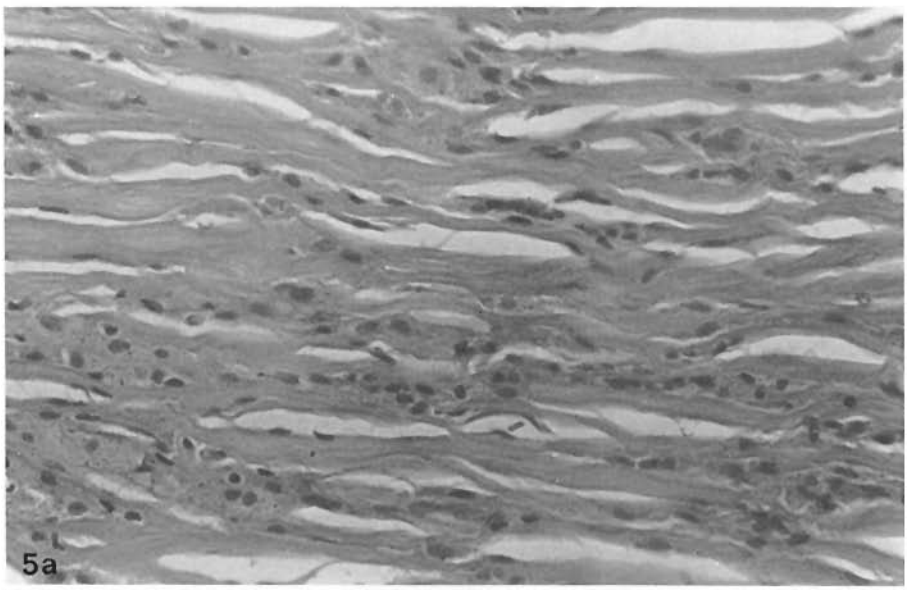



Fig. 5a, b. Tissue between bone and cement; H & E. **a** Mononuclear histiocytes with foamy cytoplasm and black particles between collagen fibers; × 187. **b** The same field in polarized light; black particles are faintly birefringent

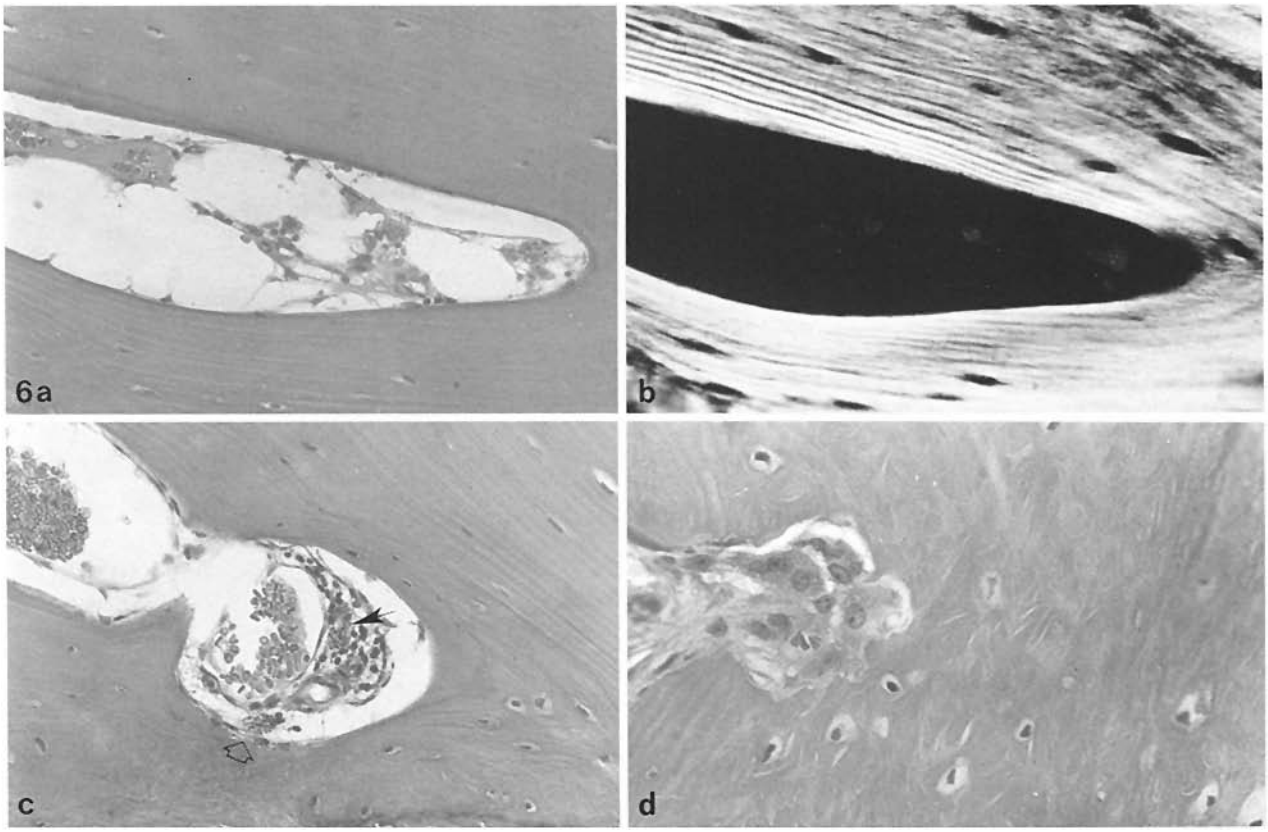

Fig. 6a–d. Relationships between mononuclear histiocytes and bone; H&E. **a** Mononuclear histiocytes with black inclusions inside vessels of bone; × 175. **b** The same field in polarized light; some particles are faintly birefringent; × 175. **c** A mononuclear histiocyte outside the vessel wall and in contact with bone (white arrow), another is observed inside the vessel (black arrow); × 175. **d** Direct bone resorption by macrophages; × 220



Fig. 7. Mononuclear histiocytes show a strongly positive reaction for acid phosphatase; × 74

ed. The result was good, pain was reduced significantly, and functional recovery was almost complete for the requirements of the patient. After 5 years he started to complain of pain in the right hip and was readmitted in October 1975. X-ray examination and scintigraphy showed loosening of the right prosthesis (Fig. 1). In November 1975 both the cup and the stem were removed and replaced.

2. *CW, male, aged 30.* In 1975 a Judet total-hip arthroplasty was performed for post-traumatic necrosis of the left hip. Because of pain the prosthesis was removed 1 year later and replaced with a Müller prosthesis. After 2 years the pain recurred. The patient was admitted for the first time to the Orthopedic Clinic of the University of Pavia in December 1978. X-ray examination and scintigraphy showed loosening of

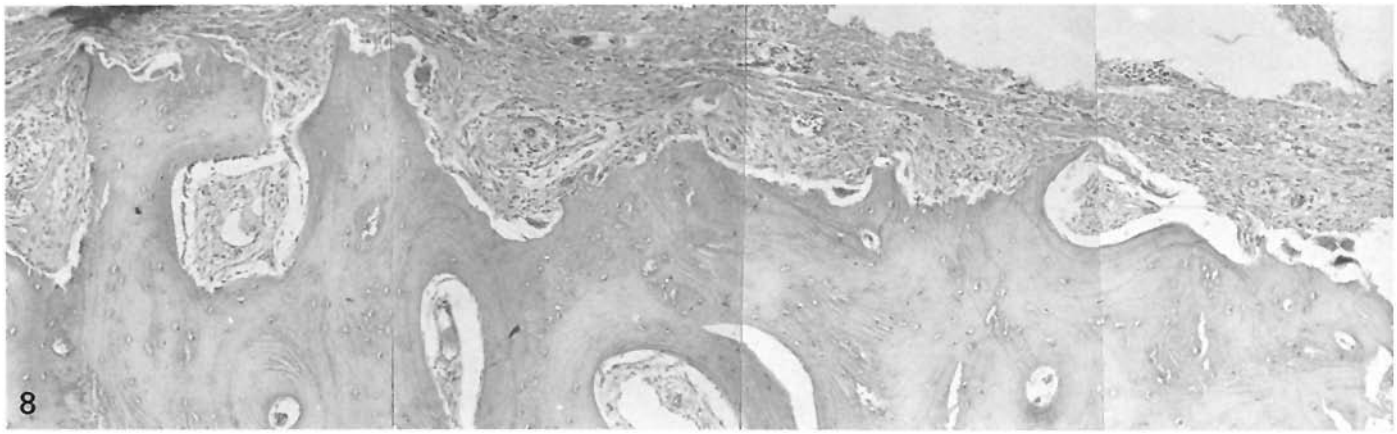

Fig. 8. Tissue between diaphyseal bone and cement (but not from the calcar) of prosthesis PM. Many osteoclasts are present on the surrounding bone surface; H&E; × 73

the stem (Fig. 1). The prosthesis was removed and not replaced.

3. *BR, female, aged 73.* IN 1977 a Co-Cr prosthesis (Rizzoli type) was inserted for osteoarthritis of the right hip. After 2 years the patient started to complain of pain. Resorption of bone around both the cup and the stem was observed. She was admitted for the first time to the Orthopedic Clinic of the University of Pavia in March 1980. X-ray examination and scintigraphy showed a complete loosening of both the cup and the stem (Fig. 1). They were removed and replaced.

4. *PM, female, aged 61.* In June 1971, a Charnley stainless-steel hip prosthesis was inserted for osteoarthritis of the right hip. The result was good, with a full functional recovery. After 9 years the patient started to complain of pain, and X-ray examination showed bone resorption of the calcar and loosening between metal and cement. In 1980 there was a progressive increase in pain and the patient was compelled to use a cane to walk. Progressive loosening and bending of the stem occurred, until it finally fractured (Fig. 2). In April 1981 the stem was removed and replaced.

Materials and Methods

Specimens of neosynovia and of the tissue between bone and cement were taken when prostheses were removed. Bacteriological cultures for aerobic organisms were performed on the neosynovial tissue. Formalin fixation, paraffin embedding (after 5% nitric acid decalcification, if required), and hematoxylin-eosin staining were used in preparing histology sections. Fresh-frozen sections were prepared for detection of acid phosphatase [6]. The sections were observed with a light microscope (Leitz Orthoplan). Coverslips were removed with xylene and a gold layer of approximately 4 nm was applied by sputter coating. The same sections that had been examined optically were then examined with a scanning electron microscope (JEOL JSM 35C), using the secondary and backscattered electron modes. X-ray microanalysis was performed using an energy-dispersive spectrometer. Samples for transmission electron microscopy were fixed in 4% glutaraldehyde, buffered at pH 7.4, and postfixed in 1% OsO_4. Stained thin sections were observed with a Philips 300 transmission electron microscope equipped for energy-dispersive X-ray analysis.

Observations

At operation, two prostheses exhibited loosening of both cup and stem. The cement was removed easily because contact between bone and cement had been lost. In two cases (CGB and BR) a soft gray tissue was present adjacent to the ball and socket. This tissue extended between bone and cement behind the socket and down the diaphysis. Its thickness was not uniform, but was never less than 1 mm. The adjacent bone had lost its cancellous architecture and the bone surface was smooth and sclerotic, with some recesses into which the tissue penetrated.

In one case (CW), only the stem was loose, with the same gray tissue extending down the diaphysis. In the fourth case, the broken prosthesis (PM), only the proximal part of the stem was loose. The distal portion was firmly anchored to the bone. A soft gray tissue was interposed between the ball and the socket, extending toward the calcar. Otherwise the tissue between bone and cement at the level of the proximal stem in this particular case was unpigmented, thin, and firmer in consistency compared with the others. Tissue from comparable sites was macroscopically similar in the first three prostheses. However, there were differences between the tissue from different sites, but only at the microscopical level, namely, those adjacent to the socket and the head and those from the bone-cement interface. All bacteriological cultures were negative.

The following microscopical observations were made in the first three cases: tissue adjacent to the socket and the head was mostly very cellular with little or no intercellular substance. Some cell-free material with amorphous, eosinophilic, fibrinous character was present (Figs. 3 and 4). Two cell types predominated:

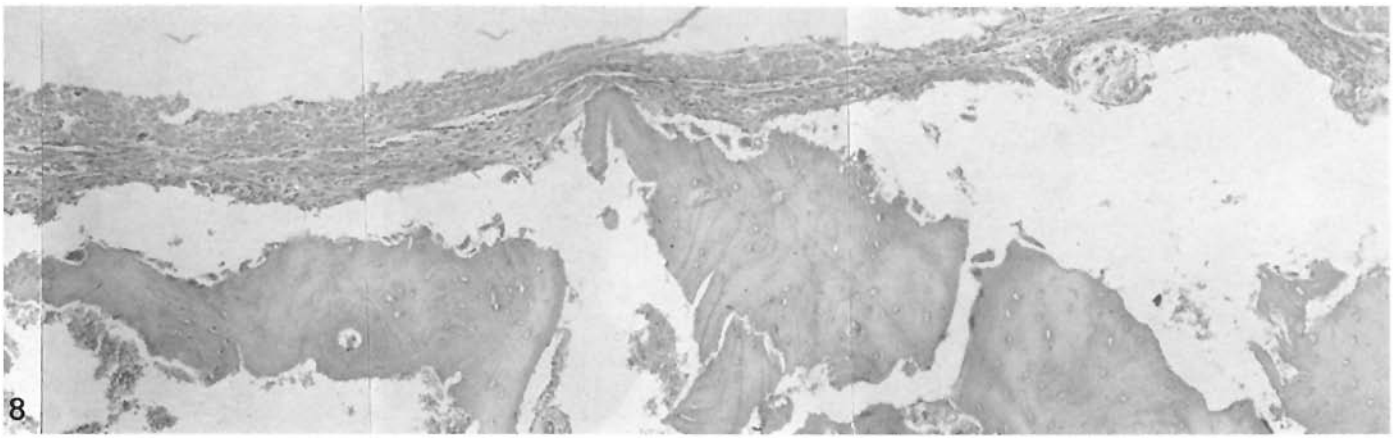

Fig. 8

1. Mononuclear histiocytes with a diameter of 20 to 40 μm; their cytoplasm was foamy with many faintly birefringent black particles of various shapes and sizes, but as a rule no larger than 1 μm. Some elongated, strongly birefringent polyethylene particles were visible.
2. Multinucleate giant cells, diameter 100–400 μm, which incorporated larger, strongly birefringent polyethylene fibers; similar cells also surrounded voids which had originally contained globules of bone cement. Neither granulocytes nor lymphocytes nor plasma cells were apparent.

The tissue between bone and cement was moderately fibrotic, with collagen fibers following a predominant orientation, mainly parallel to the bone surface. There were few fibroblasts and many mononuclear histiocytes with a foamy cytoplasm containing black particles under 1 μm in size (Fig. 5). Small polyethylene particles were rare, and no giant cells or large polyethylene fibers were found here. The adjacent bone surface was smooth and the bone was dense and viable. The mononuclear histiocytes formed recesses in the bone (Fig. 6). These cells had the same cytoplasmatic inclusions as those described above. The irregular surface which they presented to the bone suggests active resorption by them, and they proved strongly positive for acid phosphatase (Fig. 7).

The neosynovium and the neocapsule of the fourth prosthesis contained mononuclear histiocytes with black cytoplasmic inclusions extending exclusively in the medial part of the diaphyseal cortical bone, corresponding to the calcar. Elsewhere the tissue between bone and cement was poorly cellular and densely collagenous with fibers running parallel to the cement surface. No macrophages with inclu-

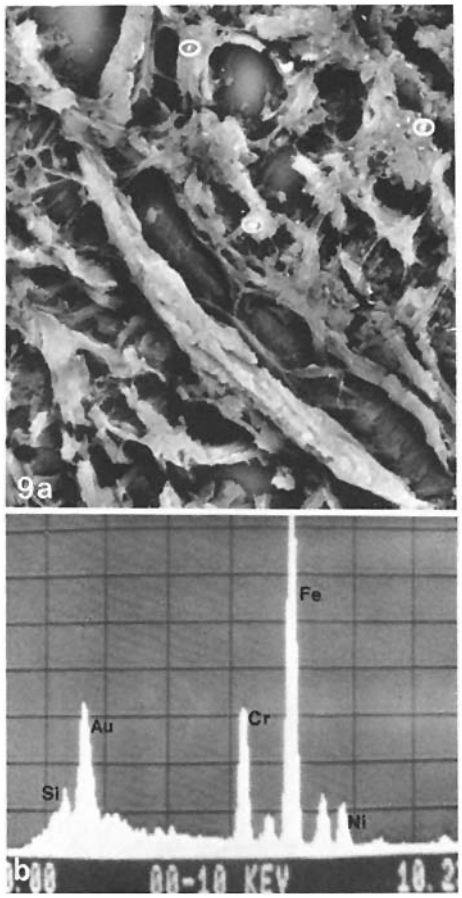

Fig. 9a, b. a Scanning electron micrograph (backscattered electron image) of a gold-coated histological section mounted on a glass slide (coverslip removed). Intracellular metal particles are revealed as bright spot *(circles)* against the darker background of the organic material; × 900. **b** Typical X-ray analysis spectrum of the particles encircled in **a** showing the *Fe, Cr,* and *Ni* composition of stainless steel. The gold *(Au)* peak results from the coating and the silicon *(Si)* peak from the glass substrate

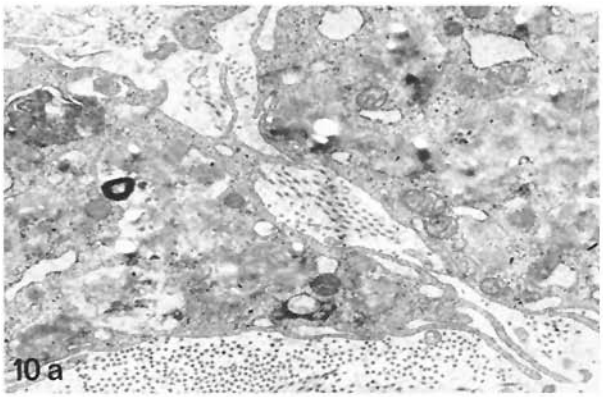

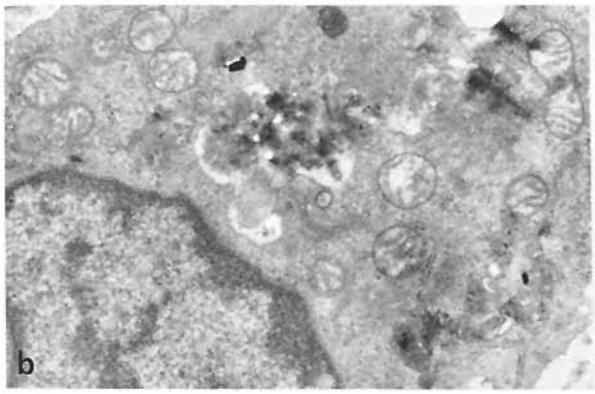

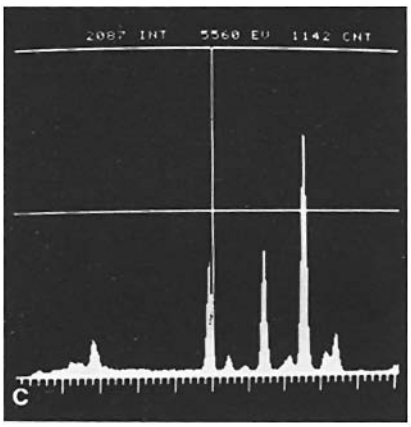

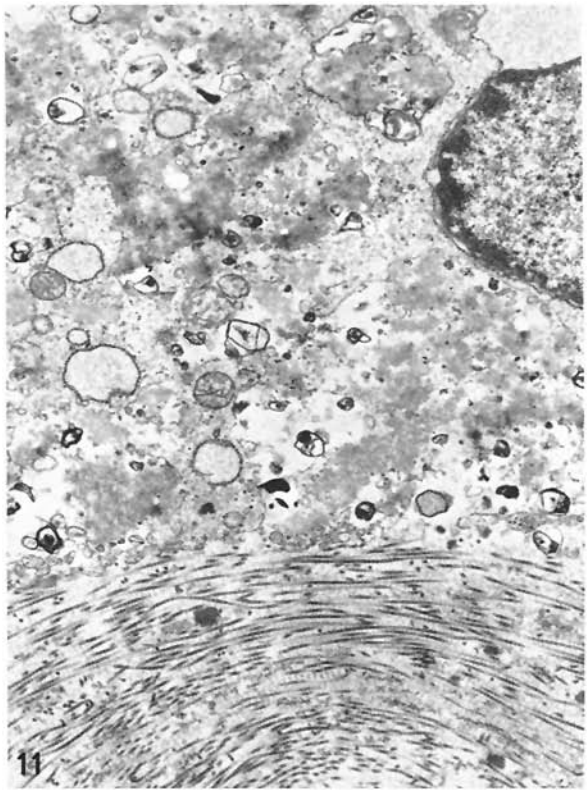

Fig. 10a–c. Transmission electron microscopy. **a** Mononuclear histiocytes with many lysosomal cisternae which contain highly electron-dense material. There are no electron-dense particles in the intercellular substance; × 12800. **b** Secondary lysosomes with electron-dense particles at higher magnification; × 34000. **c** X-ray analysis of electron-dense material indicates Co-Cr alloy

Fig. 11. Transmission electron microscopy. A mononuclear histiocyte in very poor condition with many large lysosomes, electron-dense particles, wide-spread myelinic figures, and a discontinuous plasma membrane; × 6400

sions were identified here. Many osteoclasts were present on the surrounding bone surface, suggesting active bone resorption (Fig. 8).

Scanning electron microscopy combined with X-ray microanalysis was used to identify the particles. The same macrophages observed by light microscopy appeared in the SEM (backscattered electron mode) to contain inclusions of high atomic number. X-ray analysis confirmed the Co-Cr-Mo composition of particles found within specimens of tissue close to Co-Cr alloy prostheses and the Fe-Cr-Ni spectrum for particles related to stainless-steel prostheses (Fig. 9).

The transmission electron microscope observations in all four cases showed the detailed character of the mononuclear cells. They exhibited many lysosomal cisternae containing highly opaque electron-dense material. Lanceolate spaces in lysosomes sometimes contained highly electron-opaque particles which varied in size up to 100 nm. Their appearance was not altered by staining with lead citrate or uranyl acetate. X-ray analysis confirmed the metallic nature of these particles. Many of the macrophages were in poor condition, with numerous large lysosomes, signs of cell necrosis, a discontinuous plasma membrane, and widespread myelinic figures (Figs. 10 and 11).

The surfaces of the removed prosthesis were examined. Both Co-Cr prostheses (CW and BR) showed marks of wear on the stem, characterized by a reg-



Fig. 12a, b. Müller Co-Cr alloy prosthesis of patient *CW*. Abrasion marks are evident on the stem; × 100

Fig. 13a, b. Rizzoli Co-Cr alloy prosthesis of patient *BR*. Abrasion has occurred on the distal part of the stem; × 75

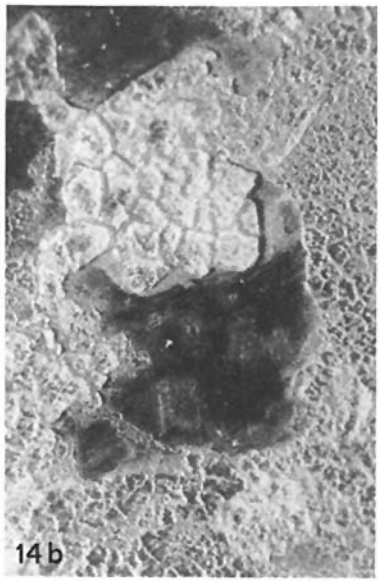

Fig. 14a, b. Charnley stainless-steel prosthesis of patient *CGB*. Areas of corrosion are evident on the stem; × 75

ular parallel pattern of scratches (Figs. 12 and 13). One stainless-steel prosthesis (CGB) exhibited a wide area of pitting corrosion across the stem surface in contact with the cement (Fig. 14). The other (PM) showed an area of pitting corrosion on the distal part of the stem (the part still firmly fixed), while the loose proximal part showed wear marks but no corrosion (Fig. 15).

Discussion

Histological studies of necropsy material led Charnley [9, 10, 11] to conclude that a successful hip prosthesis, even after 10 or more years, exhibits direct contact between bone and cement in the femoral diaphysis. A thin, ca. 1-mm layer of connective tissue divides the cement from the marrow. Such characteristics may be taken as proof of prosthetic stability. In contrast, loose prostheses are characterized by a thickened layer of connective tissue at the bone-cement interface. This thickened layer probably develops as a result of micro-movements of the cement and associated small lacerations of adjacent bone and soft tissue with consequent exudation and hemorrhage [27, 29].

A critical factor in prosthetic loosening is damage to the bone-cement interface. Such damage may arise from microfracture of the bone. This could be related to, for example, inadequate packing of cement with insufficient contact area, resulting in high stress at a few sites.

Bone may also be damaged by avascular necrosis following infiltration of marrow spaces by granula-

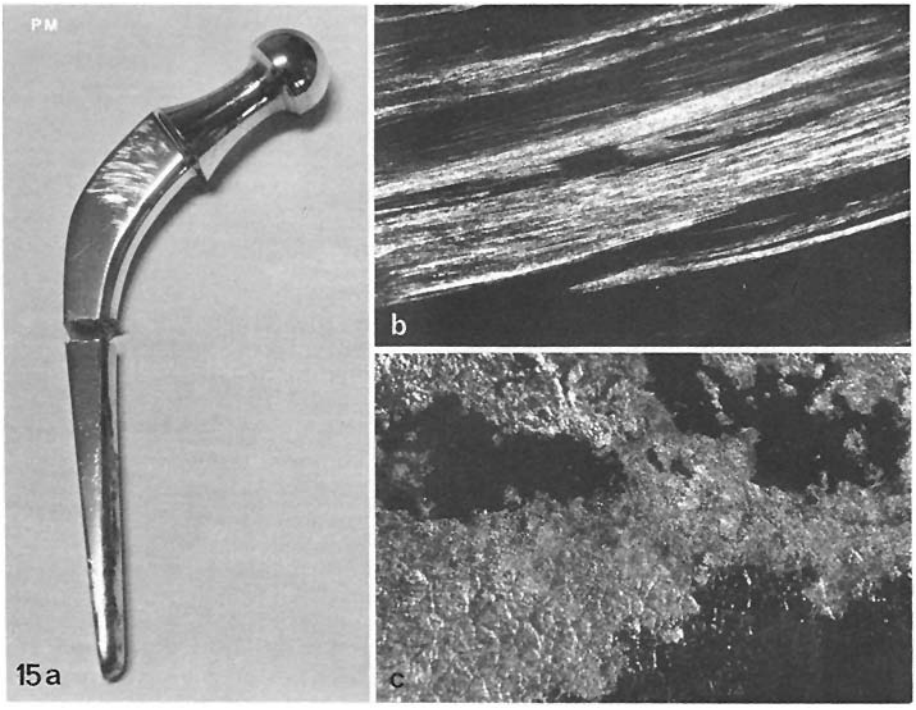

Fig. 15a–c. a Charnley stainless-steel prosthesis of patient *PM*. **b** Wear is evident on the proximal portion of the fractured stem; × 100. **c** An area of corrosion on the distal part of the stem; × 75

tion tissue containing excessive quantities of wear debris [22]. We did not observe this reaction in these four cases, all of which exhibited viable osteocytes.

Damage to the bone-cement interface could also result from bone resorption. This process is normally associated with osteoclasts. Our results strongly suggest, however, that in the first three cases presented bone resorption by macrophages of inflammatory tissue has occurred to a significant extent. We are led to this conclusion by the absence of osteoclasts from bone surfaces in contact with inflammatory tissue, by the extensive lysosomal development within macrophages suggesting their potential to generate large quantities of hydrolytic enzymes, and by the presence of these acid-phosphatase-rich, mononuclear, phagocytic cells within bone recesses.

These observations also support the suggestion made by Salthouse [23] that metal-particle uptake may induce increased lysosomal enzyme activity among macrophages associated with orthopedic implants.

Freeman et al. [15] recently hypothesized that progressive osteoclasis results when macrophages at the interface of bone and polymethylmethacrylate cement are provoked by foreign particulate matter, by bacteria, or by the products of cell death. Of the foreign debris observed in the present cases (polyethylene, acrylic cement, and metal), only metallic debris (stainless-steel, and Co-Cr-Mo particles) excited macrophages. Furthermore, only metallic debris was present almost exclusively in the critical areas around the stem and behind the cup. This debris was intracellular, associated with lysosomal vesicles, and characterized by dead and dying cells. As yet, we have no information concerning the effects of other types of metallic debris such as that liberated by wear of titanium prostheses on macrophage excitation in vivo. The particles of polyethylene and polymethylmethacrylate observed seemed to elicit comparatively little cellular response and were not associated with cell necrosis.

The four cases showed no evidence of infection, and it seems unlikely that bacteria were responsible for the macrophage response. On the other hand, cell necrosis certainly occurred, and the products of cell death presumably reinforced the effects of metal particles on macrophages by encouraging phagocytosis and lysosomal development.

It should not be assumed that the release of hydrolytic enzymes from macrophages depends entirely on cell death and disintegration. These cells may leak enzymes as well as secrete the contents of their lysosomal vesicles [7]. Macrophages at the bone-cement interface could therefore cause bone resorption by liberating hydrolytic enzymes in several ways, including passive leakage, active secretion, and ultimately cellular disintegration. A self-perpetuating cycle might become established where phagocytosed particles of stainless steel or Co-Cr-Mo alloy at first provoke benign macrophages to overproduce lyso-

somal vesicles and hydrolytic enzymes. This would result in cell damage and eventual deaths, together with associated bone resorption. Cell remains would be engulfed by yet more macrophages of the inflammatory tissue, along with re-released metal particles. These particles would retain their toxicity to provoke a further cycle, and so on.

Although the pattern of bone resorption seen in the first three cases indicates a distinct macrophage involvement, it cannot be concluded that resorption by osteoclasts has been bypassed entirely. Osteoclasts are highly motile. Their absence from sections of histology specimens fixed at one point in time does not exclude the possibility that they were once present and functional within the tissue.

Revell et al. [22] noted that resorption of both living and dead bone adjacent to macrophage-containing fibrous tissue appeared to be mediated by a mixture of mononuclear cells and osteoclasts. Unfortunately, when examining clinical specimens obtainable only at a late stage of loosening, it is not possible to establish fully the relative contributions that may have been made by each of these two cell types at different times during the overall process of bone resorption.

Metal-on-plastic total hip prostheses liberate metal particles by corrosion and/or wear of the femoral stem. When corrosion occurs particle production may precede loosening. Wear debris, however, results mainly from abrasive micromovements between stem and cement. A minimal degree of movement between stem and cement must therefore precede wear. This relative movement between two surfaces presumably aids the passage of metal particles from the cement-metal interface to the cement-tissue interface in the absence of direct contact via fissures in the cement. Metallic wear debris may also be shed from the femoral head articulating in the cup if the latter is contaminated with an abrasive, such as bone cement, although this was not noticed in these four cases.

Whatever the mechanism of their production and release, particles of stainless steel and Co-Cr-Mo alloy at the bone-cement interface encourage macrophage-related bone resorption. This, we suggest, represents a contributing, and in some cases not inconsiderable, factor in loosening of metal-plastic total hip prostheses.

Acknowledgements. The authors are grateful to Miss Giovanna Bodini and Mr. Giovanni Pesci for technical assistance. This work was supported by grant No. 82.02034.04 of the National Research Council of Italy.

References

1. Amstutz HC, Lurie L, Bullough P (1972) Skeletal fixation with self-curing polymethylmethacrylate. Clin Orthop 84: 163–178
2. Beneke G, Kuprosch R, Mohr W, Paulini K, Mohing W (1973) Die Reaktion der Gelenkkapsel nach Totalarthroplastik des Hüftgelenkes. Arch Orthop Unfall-Chir 75: 289–301
3. Benson MKD, Goodwin PG, Brostoff J (1975) Metal sensitivity in patients with joint replacement arthroplasties. Br Med J 4:374–375
4. Brinkmann KE, Heilmann K (1974) Klinische, röntgenologische und feingewebliche Untersuchungen an ausgelokkerten Hüftgelenksprothesen. Arch Orthop Unfall-Chir 80:333– 342
5. Buchhorn GH, Willert HG (1982) Effects of plastic wear particles on tissue. In: Williams DF (ed) Biocompatibility of orthopedic implants. CRC Press, Boca Raton, pp 249–267
6. Burstone MS (1962) Enzyme histochemistry. Academic Press, New York
7. Chambers TJ (1982) The response of the macrophage to foreign material. In: Williams DF (ed) Fundamental aspects of biocompatibility, vol 1, pp 145–158
8. Charosky CB, Bullough PG, Wilson PD (1973) Total hip replacement failures (a histological evaluation). J Bone Joint Surg [Am] 55:49–58
9. Charnley J (1970) The reaction of bone to self-curing acrylic cement (a long-term histological study in man). J Bone Joint Surg [Br] 52:340–353
10. Charnley J (1970) Acrylic cement in orthopaedic surgery. Livingstone, Edinburgh London
11. Charnley J (1979) Low-friction arthroplasty of the hip. Theory and practice. Springer, Berlin Heidelberg New York
12. Cohen J (1959) Assay of foreign-body reaction. J Bone Joint Surg [Am] 41:152
13. Cotta H, Schulitz KP (1970) Komplikationen der Hüftalloarthroplastik durch periartikuläre Gewebereaktionen. Arch Orthop Unfall-Chir 69:39–59
14. Evans EM, Freeman MAR, Miller AJ, Vernon-Roberts B (1974) Metal sensitivity as a cause of bone necrosis and loosening of the prosthesis in total hip replacement. J Bone Joint Surg [Br] 56:626–642
15. Freeman MAR, Bradley GW, Revell PA (1982) Observations upon the interface between bone and polymethylmethacrylate cement. J Bone Joint Surg [Br] 64: 489–493
16. Gui L, Pizzoferrato A, Ranieri L, Gualtieri I (1978) Reazione tissutale articolare e para-articolare negli impianti protesici. Giorn Ital Ortop Traum [Suppl] 4:215–227
17. Langlais F, Postel M, Berry JP, Le Charpentier Y, Weill BJ (1980) L'intolérance aux débris d'usure des prothèses. Bilan immunologique et anatomopathologique de 30 cas. Int Orthop 4:145–153
18. Masshoff W, Neuhaus-Vogel A (1974) Die Gelenkkapsel nach Alloplastik. Arch Orthop Unfall-Chir 78:175–198
19. Mendes DG, Walker PS, Figarola F, Bullough PH (1974) Total surface hip replacement in the dog. A preliminary study of local tissue reaction. Clin Orthop 100:256–264
20. Mirra JM, Amstutz HC, Matos M, Gold R (1976) The pathology of the joint tissue and its clinical relevance in prosthesis failure. Clin Orthop 117:221–240

21. Rae T (1975) A study on the effects of particulate metals of orthopedic interest on murine macrophage in vitro. J Bone Joint Surg [Br] 57:444–450
22. Revell PA, Weightman B, Freeman MAR, Roberts BV (1978) The production and biology of polyethylene wear debris. Arch Orthop Trauma Surg 91:167–181
23. Salthouse TN (1976) Cellular enzyme activity at the polymer-tissue interface: a review. J Biomed Mater Res 10:197–229
24. Stinson NE (1964) Tissue reaction induced in guinea-pigs by particulate polymethylmethacrylate, polythene and nylon of the same size range. Br J Exp Pathol 46:135–146
25. Stinson NE (1963) The tissue reaction induced in rats and guinea-pigs by polymethylmethacrylate (acrylic) and stainless steel. Br J Exp Pathol 45:21–29
26. Uchida S, Yoshino S, Doi M, Kudo H (1980) Side-effects of prosthetic materials on the human body. Int Orthop 3:285–291
27. Willert HG, Puls P (1972) Die Reaktion des Knochens auf Knochenzement bei der Allo-Arthroplastik der Hüfte. Arch Orthop Unfall-Chir 72:33–71
28. Willert HG (1973) Tissue reactions around joint implants and bone cement. In: Chapchal G (ed) Arthroplasty of the hip. Thieme, Stuttgart
29. Willert HG, Ludwig T, Semlitsch M (1974) Reaction of bone to methacrylate after hip arthroplasty (a long-term gross, light-microscopic and scanning electron-microscopic study). J Bone Joint Surg [Am] 56:1368–1382
30. Willert HG, Semlitsch M (1970) Tissue reactions to plastic and metallic wear products of joint endoprostheses. In: Gschwend N, Debrunner HV (eds) Total hip prosthesis. Huber, Bern
31. Winter GD (1974) Tissue reactions to metallic wear and corrosion products in human patients. J Biomed Mater Res 8:11–26

Received January 17, 1984