

Systematic Review

Treatment of Early Cesarean Scar Pregnancy with Double Balloon Catheter: A Systematic Review of the Literature

Irene Passerini¹, Francesco Marasciulo¹, Federico Prefumo², Anna Fichera¹, Nicola Fratelli³, Filippo Alberto Ferrari⁴, Federico Ferrari^{1,*}, Franco Odicino¹

¹Department of Clinical and Experimental Sciences, University of Brescia, 25121 Brescia, Italy

²Obstetrics Unit, IRCCS Istituto Giannina Gaslini, 16147 Genoa, Italy

³Department of Obstetrics and Gynecology, Spedali Civili di Brescia, 25123 Brescia, Italy

⁴Department of Obstetrics and Gynecology, AOUI-University of Verona, 37129 Verona, Italy

*Correspondence: federico.ferrari@unibs.it (Federico Ferrari)

Academic Editor: George Daskalakis

Submitted: 31 May 2023 Revised: 27 July 2023 Accepted: 14 August 2023 Published: 20 October 2023

Abstract

Background: Cesarean scar pregnancy (CSP) is a pregnancy in the scar area or “niche” from a prior hysterotomy, usually from a cesarean section. Currently, there is no consensus on the best management of CSP. A recent proposed treatment consists in placing a cervical ripening double-balloon catheter in the uterus under ultrasound guidance. **Methods:** In this systematic review on cervical ripening double-balloon catheter (CRDBC) treatment for CSP, we performed a literature search in electronic databases (Scopus, PubMed, MEDLINE, and Cochrane Library), from their inception until April 2023. The review was written following PRISMA guidelines for systematic reviews. **Results:** We identified 30 studies, and we finally analyzed 5 studies that met the inclusion criteria (one case report, two retrospective case series studies, a retrospective cohort study, and a retrospective multicentric case series). The total of pregnancies treated with CRDBC is 71, of which 8 (11%) were cervical pregnancies. The gestational age at treatment ranges from 5 + 0 to 10 + 1 gestational weeks, with variable human chorionic gonadotropin (hCG) levels (433–64.700 IU/mL). Most of the patients (73%) received adjuvant systemic methotrexate (MTX) and the catheter dwell time ranges from 1 to 5 days. Treatment was successful in all the patients. Maternal complications, defined as the need for transfusion, vaginal bleeding resulting in readmission, or requiring further treatment occurred in a small number of patients (4.2%). **Conclusions:** CRDBC was successful in the treatment of early CSPs. The effectiveness and safety of this minimally invasive method is testified to a small rate of maternal complications. Further prospective studies are warranted to explore this treatment modality. The study was registered on INPLASY (<https://inplasy.com/>), registration number: INPLASY202390070 (doi: 10.37766/inplasy2023.9.0070).

Keywords: cesarean scar pregnancy; double-balloon catheter; foley

1. Introduction

A cesarean scar pregnancy (CSP) is defined as the implant of a pregnancy in the scar area or in the “niche”, subsequent to a previous hysterotomy, and is considered a pathological iatrogenic condition, frequently derived from a previous cesarean section (CS) [1]. CSP is included in placenta accreta spectrum (PAS), with a potential abnormal placentation in the lower uterine segment and the development of placental accretism [2]. The disease was first described in the 1978 by Larsen and Solomon [3], and the prevalence is raising progressively due to the increase of CSs, and has been reported between 1 case in 1800–2500 pregnancies [4]. A CSP can lead to several complications, such as developing of placenta accreta, hemorrhage, uterine rupture, and even maternal death.

Several treatment options were suggested over the years, such as expectant management, medical, or surgical treatment. In literature, over thirty primary treatment options have been described so far [2], which included single intramuscular injection of methotrexate (MTX), combined

injection of MTX either in the gestational sac and intramuscular, potassium chloride (KCl) injection in the gestational sac, dilatation and curettage (D&C), operative hysteroscopy with transvaginal resection of CSP, uterine artery embolization (UAE) in combination with D&C without MTX, UAE with D&C and operative hysteroscopy, UAE in combination D&C with and without MTX, surgical transabdominal excision, and repeated high-intensity focused ultrasound ablation [5]. There is no agreement about how to manage CSP and furthermore, there are several risk factors such as age, parity, gestational week, human chorionic gonadotropin (hCG) levels, and number of CSs that can impact the choice of the treatment.

In 2016, Timor-Tritsch *et al.* [6] proposed a novel treatment consisting in placing a cervical ripening double-balloon catheter (CRDBC) in the uterus under ultrasound guidance. The same authors had previously described the adjuvant use of a single Foley balloon positioned soon after intragestational injection of MTX in a group of 18 patients [7]. However, the major complication reported with



Description of the double balloon catheter treatment technique

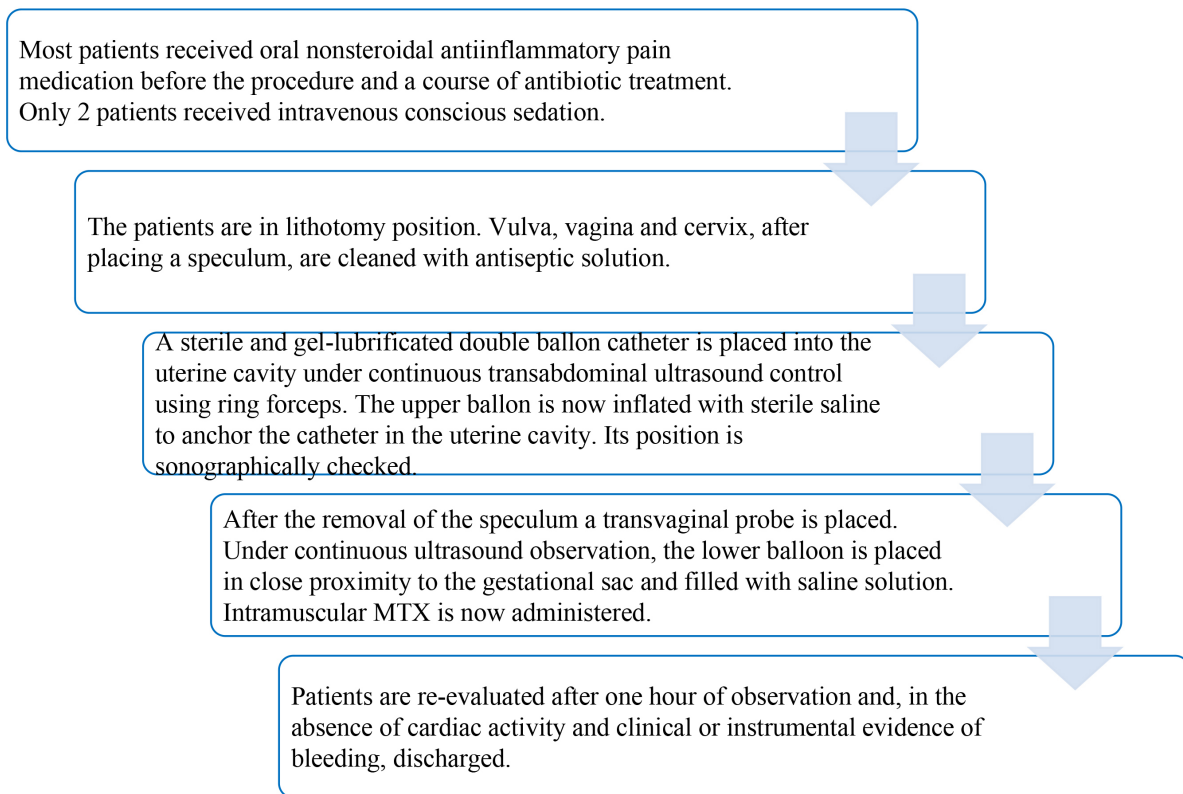


Fig. 1. Description of the double balloon catheter treatment technique. MTX, methotrexate.

this technique was that the expulsion of the catheter before its planned removal occurred in 3 patients. In the novel proposed approach, the superior balloon must be placed in the uterine cavity to anchor it for preventing displacement, and the inferior balloon must be placed adjacent to the gestational sac. The filling of the two balloons is related to the weeks of gestation. The catheter should remain in place for about two–three days, with antibiotics prophylaxis. In 2019, the authors revised the procedure, adding intramuscular injection of MTX immediately after the procedure [8]. Fig. 1 shows the design pipeline of the double balloon catheter treatment technique described by Timor-Tritsch and colleagues [6–8].

The aim of this systematic literature review is to analyze the success rate and the maternal complications of the CSPs treated with the placement of a CRDBC.

2. Materials and Methods

This study protocol was followed PRISMA guidelines and previously registered with INPLASY (<https://inplasy.com/>) on 7th September 2023, registration number: INPLASY202390070 (doi: 10.37766/inplasy2023.9.0070).

2.1 Sources

A literature search was performed in the electronic databases Scopus, PubMed, MEDLINE, and Cochrane Library, from their inception until April 2023. For the purpose of this study, the research included combinations of the following terms: double balloon catheter cesarean scar pregnancy, (double balloon catheter [Title] AND (cesarean scar pregnancy)), (double balloon catheter) AND (cesarean scar pregnancy [Title]), (cesarean scar pregnancy [MeSH Major Topic]) AND (double balloon catheter), (cook catheter cesarean scar pregnancy).

The research aimed to identify all articles published in English, French, Spanish, or German until April 2023, that reported the use of the aforementioned technique for the treatment of CSPs.

2.2 Eligibility Criteria

Given the rarity of the condition and the recent introduction of CRDBC as a treatment, we included case reports, case series, retrospective and prospective studies, describing the clinical features and the outcomes of women diagnosed with CSP and treated with double balloon catheter. Studies in which systemic MTX as adjuvant treatment was administered were included.

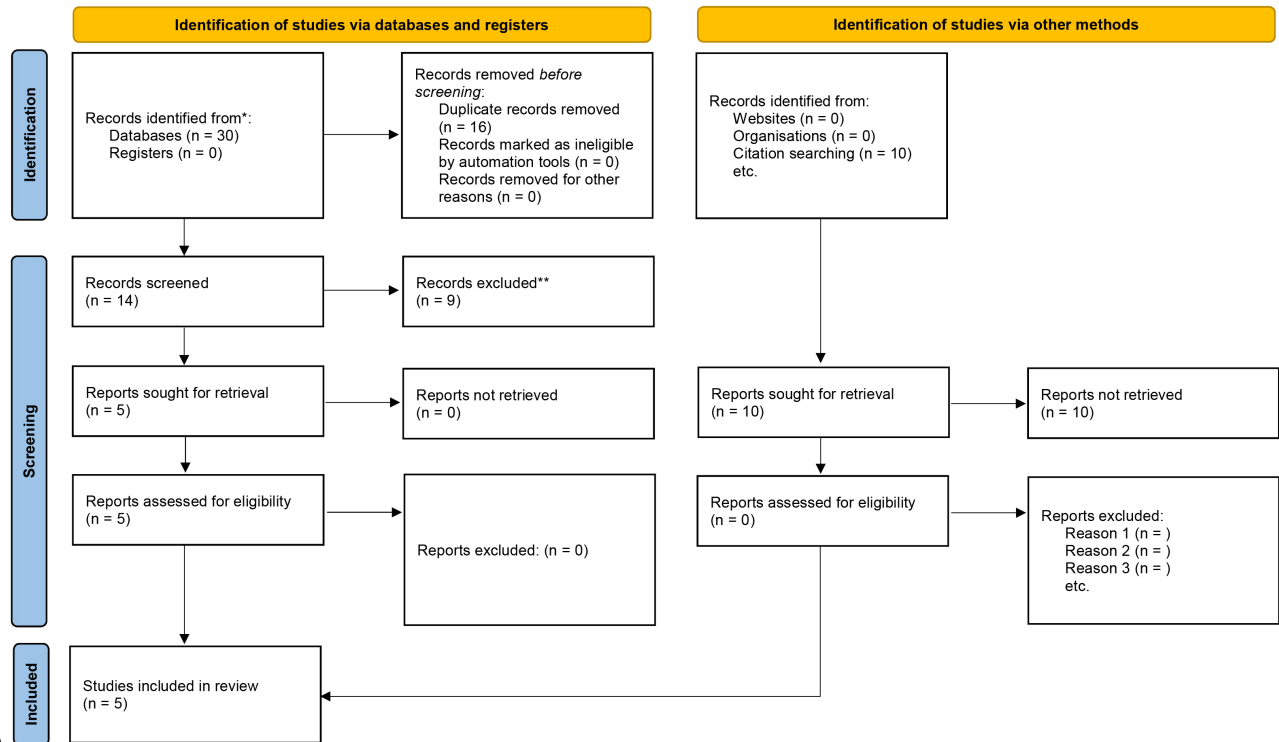


Fig. 2. Flowchart of the systematic review.

2.3 Collection and Analysis

The titles and/or abstracts of the identified studies were screened independently by two authors (IP and FM). Subsequently, the same authors recovered the entire text of screened papers and assessed its eligibility. We reviewed the references to find other eligible publications. For all unavailable articles or incomplete data, we contacted the corresponding authors. Every disagreement on the eligibility of the data was resolved by a third author (FP). The revision was written following PRISMA guidelines for systematic reviews. Data was extracted from each study, including sample size, gestational age at treatment, number of cesarean scar pregnancies, previous CS, mean time of treatment, hCG levels, and adjuvant treatment. All authors assessed the methodological quality of all the papers. For statistics, we used descriptive analysis. Comparative analyzes were not performed due to lack of raw data. We did not evaluate the quality of the studies because of their diversity and small sample size.

3. Results

3.1 General Characteristics of the Studies

We identified thirty studies and fourteen have been retrieved for evaluation. We excluded nine records, and we finally selected five studies that met our inclusion criteria. The selected articles span from 2016 to 2023, and include a case report, two case series studies, a cohort study,

and a multicentric case series. The total of pregnancies treated with CRDBC is 71, of which 8 (11%) were cervical pregnancies. Flowchart of selection process is available in Fig. 2.

3.2 Synthesis of the Results

From the articles reviewed, data of 71 pregnancies treated with CRDBC were extracted. Two records include in their series 8 cervical pregnancies, whose characteristics are analyzed together with the pregnancies implanted on the uterine scar [6,9]. The diagnostic criteria used for most of the studies (75%) are those developed by Timor-Tritsch in 2012 [2], the two other records used the updated diagnostic criteria published later by the same author [10,11].

In the retrospective study by Timor-Tritsch in 2016, the patients obstetric history is not known [6]. Two previous caesarean sections (CS) are reported for patients analyzed individually [11,12], an average of 1.8 CSs for the Monteagudo group, and a median of 2 CSs in the Kus series (with a similar range 1–5 vs. 0–5, respectively without or with cervical pregnancies) [8,9]. In 5 patients, we found a diagnosis of a recurrent CSP, and among them, 4 patients had a history of one previous CSP and 1 patient had two previous CSPs. Notably, the previous CSP was previously treated with other methods rather than CRDBC. Characteristics of the pregnancies treated with CRDBC are described in Table 1 (Ref. [8–10,12,13]).

Table 1. Characteristics of the pregnancies.

Article	Type of study	Cases	Previous CS	Previous CSP	Gestational age at treatment	Gestational sac volume or CRL	hCG IU/mL at treatment	Upper and lower balloon filling (volume in mL)	Days balloon kept in place	Adjuvant treatment	Days for hCG negative	Complications
Timor-Tritsch <i>et al.</i> , 2016 [10]	Retrospective case series study	10*	Not known	Not known	6 + 6 (6 + 3–7 + 4)	8.9 mL (2.5–25.8)	29.475 (2.488–64.700)	24 and 15	3 (1–5)	None	49 (2897)	None
Monteagudo <i>et al.</i> , 2019 [8]	Retrospective multicentric case series	36 (1 twin)	1 (1–5)	5	6 + 3 (5 + 0–10 + 1)	Not known	30.716	10 to 25 and 10 to 20	1 (1–3)	32 (intramuscular MTX)	48.5 (13–106)	1 patient underwent hysterectomy after 27 days
Spazzini <i>et al.</i> , 2020 [13]	Case report	1	2	0	7 + 0	4.6 mm	22.204	20 and 18	2	None	21	None
Kus <i>et al.</i> , 2022 [9]	Retrospective cohort study	23**	2 (0–5)	Not known	6 (5 + 0–8 + 0)	Not known	14.515 (1.409–136.746)	40 and 50	Not known	20 (systemic MTX)	Not known	1 patient underwent UAE
Wu <i>et al.</i> , 2023 [12]	Retrospective case series study	1***	2	0	8 + 1	Not known	Not known	10 and 10	Immediately removed	None	Not known	1 patient underwent UAE, hysterosuction and single balloon insertion with blood transfusion

Data are expressed as absolute count or measurement, or as median or mean (range).

* including 3 cervical pregnancies.

** including 5 cervical pregnancies.

*** only one patient treated with investigated technique.

CS, caesarean section; CSP, caesarean section pregnancy; CRL, crown-rump length; hCG, human chorionic gonadotropin; IU, international unit; mL, millilitres; MTX, methotrexate; UAE, uterine artery embolization.

The gestational age at treatment was 7 + 0 and 8 + 1 weeks for pregnancies reported individually, while a median of 6 + 0 weeks of gestation is described in the other groups, with a range of 5 + 0 to 10 + 1 gestational weeks. hCG levels at treatment were highly variable, with a minimum of 433 IU/mL, and a maximum of 64.700 IU/mL.

52 patients (73% of the total) received a dose of systemic MTX prior to catheter insertion or at the time of insertion. In the studies, adjuvant systemic treatment was prescribed to 20 patients in response to updated guidelines [2,8,9]. In the 71 patients analyzed herein, no other types of adjuvant treatments are reported. Catheter dwell time is reported in 48 patients (67.6%). In the group of patients described in 2016 by Timor-Tritsch, the catheter remained in place for a median of 3 days (range 1–5), while 36 patients reported in 2019 the mean dwell time was 1.2 days (median 1 days, range 1–3) [6–8]. In only 1 patient, the catheter was immediately removed because of sudden excessive bleeding [12].

Treatment outcomes have been described in terms of the time of a negative hCG and the occurrence of maternal complications. hCG follow-up data are available for 43 patients (60.5%). In the series of Montegudo and Timor-Tritsch (42 patients) similar medians number of days to a negative hCG are described (respectively, 48.5 and 49 days), with an overall range from 13 to 106 days [6–8]. Maternal complications, defined as the need for transfusion, bleeding resulting in hospital readmission, or requiring further treatment such as UAE, hysterosuction or hysterectomy, occurred in 3 patients (4.2%) and are described below. One patient underwent UAE, hysterosuction, transfusion and single balloon insertion because of the immediate onset of excessive bleeding [12]. The second patient underwent hysterectomy to control excessive bleeding, which occurred 27 days after primary treatment [8]. The third and last patient developed enhanced myometrial vascularity associated with bleeding and underwent UAE without reporting of the onset of the complication [9].

4. Discussion

CRDBC placement was found to be a feasible and relative safe treatment for CSP, leading to maternal complication in less than 5% of the cases. As a mainstay, to adopt this treatment strategy, a correct diagnosis of this condition is relevant, and it is possible during an early pregnancy ultrasound evaluation. The diagnostic criteria of CSP includes: (i) an empty uterine cavity, (ii) a gestational sac located in the anterior uterine wall “niche”, (iii) a peritrophoblastic or periplacental vascularization at color Doppler evaluation, and (iv) a negative “sliding organ sign” [4].

A review published in 2012, summarized the different therapeutic modalities of CSPs and included surgical interventions (D&C, operative hysteroscopy, laparoscopic and laparotomic excision, and hysterectomy), radiological interventions (UAE), medical interventions (administration

of local or systemic MTX), as well as a combination of these modalities. In this series, 98 patients (12%) required emergency secondary interventions (such as hysterectomy, laparotomy, and UAE) to control life-threatening massive bleeding [2]. Of course, the possibilities for CSP treatment are numerous and heterogeneous, and the clinical challenge is to choose the most appropriate treatment to ensure maternal health, and preserve fertility.

The introduction of CRDBC as a primary treatment of CSP is relatively recent and the rationale is based on the hypothesis to obtaining hemostasis and to stop eventual heart activity at the same time [6]. In this review we identified 71 pregnancies (8 cervical pregnancies and 63 cesarean scar pregnancy) treated with CRDBC from a case report, two retrospective case series studies, a retrospective cohort study and a retrospective multicentric case series. All the pregnancies presented at early gestational age at treatment (with median at 6 weeks) while no CSP was treated with CRDBC after 10 + 1 weeks. In 73% of the cases, adjuvant treatment such as systemic MTX was administered and hCG were undetectable after a median time of 49 days. Maternal complications, such as excessive bleeding that need secondary treatment, occurred in 4.2% of the cases, and in one case the patient underwent hysterectomy.

The strength of this study is the synthesis of a homogeneous group of patients with CSP, all diagnosed with overlapping criteria, in a relatively short period of time. The limitations of this review are numerous. In fact, not all studies provided raw data, so it was not possible to distinguish the specific outcomes of the eight cervical pregnancies from the CSPs; the rarity of the condition and the recent description of CRDBC treatment, which limited the sample size; the lack of complete clinical and outcomes data and of a standardized procedure, which results in a non-uniformity of catheter dwell time and balloon filling volume across the studies; and finally, the use of adjuvant therapy in 73% of pregnancies, which does not allow to evaluate the selective effect of the investigated treatment. Among the 71 patients analyzed, a low incidence of maternal complications and a 100% success rate were reported. This results may be partly explained by the fact that unsuccessful cases are less likely to be published, providing the elements for a selection bias.

Recent literature data describes a recurrence rate of CSP in 20.5% of the cases, however, no association was found between the type of primary treatment and the recurrence [14]. In our review, we included 5 patients with a recurrent CSP (7.9%), which had been previously treated with a combination of treatments, such as KCl intragastric injection, single Foley balloon, and intramuscular MTX [8]. These patients had a favorable outcome after CRDBC treatment, with a mean time to hCG negativization of 55 days, and none of them developed complications. Regardless of the limited small number of patients, this treatment has been shown to be effective and well-tolerated in

this subgroup of patients. Based on the well established diagnostic criteria and given the rarity of this condition, it is advisable to promote multicenter prospective case series to establish a standardized approach and outcome measurement, as happened for other rare cases of ectopic pregnancies [15].

5. Conclusions

The choice of the optimal treatment of CSP represents, considering the efficacy and invasiveness, a challenge for the clinician. CRDBC treatment has proved in this review, although on a small sample of early pregnancies, a relatively safe and minimally invasive method, compared to other methods described in the literature. More studies are required to evaluate the safety and effectiveness of this method. Surely an ever-increasing awareness of the condition must prompt the clinicians to diagnose this condition early.

Availability of Data and Materials

The datasets used and/or analyzed during the current study are available from the corresponding author on reasonable request.

Author Contributions

FP, AF and FF designed the research study. IP, FM, NF and FAF performed the research. FF and FO provided help and advice on methods. IP, FM and AF analyzed the data. IP and FM wrote the manuscript. All authors contributed to editorial changes in the manuscript. All authors read and approved the final manuscript.

Ethics Approval and Consent to Participate

Not applicable.

Acknowledgment

Not applicable.

Funding

This research received no external funding.

Conflict of Interest

The authors declare no conflict of interest. Filippo Alberto Ferrari and Federico Ferrari are serving as one of the Guest editors of this journal. We declare that Filippo Alberto Ferrari and Federico Ferrari had no involvement in the peer review of this article and has no access to information regarding its peer review. Full responsibility for the editorial process for this article was delegated to George Daskalakis.

Supplementary Material

Supplementary material associated with this article can be found, in the online version, at <https://doi.org/10.31083/j.ceog5010222>.

References

- [1] Cali G, Timor-Tritsch IE, Palacios-Jaraquemada J, Monteagudo A, Buca D, Forlani F, *et al.* Outcome of Cesarean scar pregnancy managed expectantly: systematic review and meta-analysis. *Ultrasound in Obstetrics & Gynecology: the official journal of the International Society of Ultrasound in Obstetrics and Gynecology.* 2018; 51: 169–175.
- [2] Timor-Tritsch IE, Monteagudo A. Unforeseen consequences of the increasing rate of cesarean deliveries: early placenta accreta and cesarean scar pregnancy. A review. *American Journal of Obstetrics and Gynecology.* 2012; 207: 14–29.
- [3] Larsen JV, Solomon MH. Pregnancy in a uterine scar sacculus—an unusual cause of postabortal haemorrhage. A case report. *South African Medical Journal.* 1978; 53: 142–143.
- [4] Jurkovic D, Hillaby K, Woelfer B, Lawrence A, Salim R, Elson CJ. First-trimester diagnosis and management of pregnancies implanted into the lower uterine segment Cesarean section scar. *Ultrasound in Obstetrics and Gynecology.* 2003; 21: 220–227.
- [5] Birch Petersen K, Hoffmann E, Rifbjerg Larsen C, Nielsen HS. Cesarean scar pregnancy: a systematic review of treatment studies. *Fertility and Sterility.* 2016; 105: 958–967.
- [6] Timor-Tritsch IE, Monteagudo A, Bennett T, Foley C, Ramos J, Kaelin Agten A. A new minimally invasive treatment for cesarean scar pregnancy and cervical pregnancy. *American Journal of Obstetrics and Gynecology.* 2016; 215: 351.e1–351.e3518.
- [7] Timor-Tritsch IE, Cali G, Monteagudo A, Khatib N, Berg RE, Forlani F, *et al.* Foley balloon catheter to prevent or manage bleeding during treatment for cervical and Cesarean scar pregnancy. *Ultrasound in Obstetrics & Gynecology.* 2015; 46: 118–123.
- [8] Monteagudo A, Cali G, Rebarber A, Cordoba M, Fox NS, Bornstein E, *et al.* Minimally Invasive Treatment of Cesarean Scar and Cervical Pregnancies Using a Cervical Ripening Double Balloon Catheter: Expanding the Clinical Series. *Journal of Ultrasound in Medicine.* 2019; 38: 785–793.
- [9] Kus LH, Veade AE, Eisenberg DL, Dicke JM, Kelly JC, Dickison SM. Maternal Morbidity after Double Balloon Catheter Management of Cesarean Scar and Cervical Pregnancies. *Obstetrics and Gynecology.* 2022; 140: 993–995.
- [10] Timor-Tritsch IE, Monteagudo A, Cali G, El Refaey H, Kaelin Agten A, Arslan AA. Easy sonographic differential diagnosis between intrauterine pregnancy and cesarean delivery scar pregnancy in the early first trimester. *American Journal of Obstetrics and Gynecology.* 2016; 215: 225.e1–225.e7.
- [11] Timor-Tritsch IE, Monteagudo A, Cali G, D’Antonio F, Kaelin Agten A. Cesarean Scar Pregnancy. *Obstetrics and Gynecology Clinics of North America.* 2019; 46: 797–811.
- [12] Wu BT, Feld Z, Creinin MD. Management of cesarean scar ectopic pregnancies at an academic referral center: a case series. *Contraception.* 2023; 123: 110021.
- [13] Spazzini MD, Villa A, Maffioletti C, Mariuzzo F, Cali G. First-trimester treatment of cesarean scar pregnancy using a cervical ripening—double-balloon catheter: a case report. *Journal of Clinical Ultrasound.* 2020; 48: 298–300.
- [14] Timor-Tritsch IE, Horwitz G, D’Antonio F, Monteagudo A, Bornstein E, Chervenak J, *et al.* Recurrent Cesarean scar pregnancy: case series and literature review. *Ultrasound in Obstetrics & Gynecology,* 58, 121–126.
- [15] Ferrari F, Ficarelli S, Cornelli B, Ferrari FA, Farulla A, Alboni C, *et al.* Management of Unusual Not Scar Ectopic Pregnancy: A Multicentre Retrospective Case Series. *Current Women’s Health Reviews.* 2022; 18: 86–94.