Neurosurgical Review (2026) 49:633
https://doi.org/10.1007/s10143-026-04532-2

REVIEW

Syringomyelia secondary to degenerative spinal canal stenosis: a systematic review

Luca Zanin[1] · Federico Tauro[1] · Pier Paolo Panciani[1] · Marco Maria Fontanella[1]

Received: 3 July 2026 / Revised: 31 August 2026 / Accepted: 9 October 2026
© The Author(s), under exclusive licence to Springer-Verlag GmbH Germany, part of Springer Nature 2026

Abstract

Syringomyelia is most often associated with Chiari malformation, post-traumatic cord injury, intramedullary tumours or arachnoiditis. Its occurrence with degenerative spinal canal stenosis is uncommon, and its natural history and outcomes remain poorly characterised. To synthesise patient-level evidence on syringomyelia secondary to degenerative spinal canal stenosis (mostly cervical spondylosis, with a few thoracic ossified ligamentum flavum cases), addressing presentation, radiology, management and outcomes, and examining the symptomatic and asymptomatic phenotypes separately. PRISMA 2020 systematic review of PubMed, Scopus, Embase and the Cochrane Library from inception to 31 January 2026. Methodological quality was appraised with the Joanna Briggs Institute checklists. Patient-level data were synthesised descriptively as proportions; no meta-analytic pooling was performed. The review was retrospectively registered with PROSPERO (CRD420261379566). Twelve studies contributed 28 patients (mean age 54.9 years, range 33–81; 18 men, 10 women); an institutional index case is presented separately and excluded from all denominators. Twelve patients (42.9%) were asymptomatic and managed conservatively; 16 (57.1%) were symptomatic, most often with motor weakness (75.0%), sensory deficits (50.0%) and pain (37.5%). Reported radiographic regression after extradural decompression alone was 7/12 (58%) — 2/3 anterior, 5/9 posterior; the single case with added intradural shunting was isolated from this figure. Syringomyelia secondary to degenerative spinal canal stenosis is rare and supported by a low-quality evidence base dominated by single-patient case reports. Extradural decompression of the causative stenosis — rather than primary cavity drainage — is the predominant reported strategy. In the only retrospective series large enough to address the question, incidental asymptomatic syrinxes remained stable or regressed on serial imaging; this observation requires independent confirmation.

Keywords Syringomyelia · Cervical spondylosis · Spinal canal stenosis · Cerebrospinal fluid hydrodynamics · Surgical decompression · Systematic review

Introduction

Syringomyelia is a chronic, progressive disorder defined by the development of a fluid-filled cavity — a syrinx — within the parenchyma of the spinal cord [1]. Expansion of this cavity produces a characteristic clinical syndrome that may include dissociated sensory loss, segmental lower-motor-neuron weakness and variable long-tract signs [2]. Milhorat [3] proposed a four-category nosological classification distinguishing communicating central-canal dilations, non-communicating central-canal dilations, extracanalicular cavities, and atrophic cavitations. The most frequent cause across all categories is a congenital malformation of the craniocervical junction, in particular the Chiari type I malformation, which accounts for the majority of cases in adult series [4, 5]. Other recognised aetiologies include post-traumatic cord injury, intramedullary tumours, arachnoiditis and dysraphism [6].

Degenerative cervical spondylosis is a common cause of compressive myelopathy in older adults [7], whereas associated syrinx formation is distinctly uncommon. The first clinical description is generally attributed to Lucci et

✉ Pier Paolo Panciani
pierpaolo.panciani@unibs.it

[1] Division of Neurosurgery, Department of Medical and Surgical Specialties, Radiological Sciences and Public Health, University of Brescia, Spedali Civili di Brescia, Spedali Civili di Brescia Piazzale Spedali Civili 1, Brescia 25123, Italy

Published online: 05 November 2026

al. [8], subsequently expanded by Rebai et al. [9] and by sporadic case reports through the following decades; only a handful of small case series have been published [10, 11]. The marked disparity between the prevalence of cervical spondylosis and the rarity of spondylotic syrinx implies that specific, but still incompletely characterised, pathophysiological conditions must be met for a cavity to develop in this setting [12].

Proposed mechanisms have been extrapolated largely from the Chiari-associated literature and emphasise disturbances of cerebrospinal fluid (CSF) hydrodynamics across a focal subarachnoid block [13–18]. The presyrinx state described by Fischbein et al. [19] — a reversible myelopathic condition characterised by cord oedema on T2-weighted imaging — has proved a useful conceptual framework, particularly for patients in whom decompression reverses the imaging abnormality.

Because the literature is dominated by isolated reports, there is no consensus on natural history, the threshold for surgical intervention or the optimal surgical strategy. Two questions are particularly unresolved: how should the clinician approach asymptomatic syrinxes detected incidentally on MRI of a spondylotic spine; and, when surgery is offered, are the outcomes as uniformly favourable as the individual reports suggest? We conducted a systematic review of the literature on syringomyelia secondary to degenerative spinal canal stenosis (predominantly cervical spondylosis, with a small subset of thoracic ossified ligamentum flavum cases), with two specific emphases: stratification by symptomatic versus asymptomatic status, and methodologically cautious patient-level extraction. An index case from the authors' institution is presented separately as an illustrative case, and is excluded from all pooled analyses; it is described in § 3.2.

Materials and methods

Protocol and reporting

The systematic review followed the PRISMA 2020 statement [20], and the completed checklist is provided as Supplementary Material. Inclusion and exclusion criteria, the data-extraction form, the quality-appraisal tool, the sensitivity-analysis plan and outcome definitions were fixed in writing before extraction began (protocol provided as Supplementary Material). The review was registered with PROSPERO (ID: CRD420261379566); registration occurred retrospectively, after data extraction had begun, which we acknowledge as a methodological limitation.

Search strategy

A structured search of PubMed, Scopus, Embase and the Cochrane Library was performed from inception to 31 January 2026. Two concept blocks — syringomyelia (MeSH and free-text variants including "syringomyelia", "syrinx" and "spinal cord cavitation") and degenerative spinal pathology (variants including "cervical spondylosis", "cervical spondylotic myelopathy", "spinal/canal stenosis" and ossification of the ligamentum flavum or posterior longitudinal ligament) — were combined with AND, adapting each strategy to the database's native syntax (Emtree-mapped for Embase). No date or language restriction was applied at initial screening; full-text translation was sought for eligible-appearing non-English abstracts. Reference lists of eligible studies and prior reviews were hand-searched. Complete database-specific strings, search dates and filters are provided as Supplementary Material.

Eligibility criteria

Inclusion criteria were: (1) clinical studies (case reports, case series, retrospective cohorts) of adults (≥18 years); (2) radiological diagnosis of syringomyelia on MRI; and (3) an attributed causal relationship between the syrinx and degenerative cervical spondylosis, cervical canal stenosis or thoracic ossification of the ligamentum flavum, absent other identifiable aetiologies. Exclusion criteria were: (1) concomitant Chiari malformation, spinal trauma, intramedullary tumour, arachnoiditis, dysraphism or other primary cause; (2) insufficient detail for patient-level extraction; and (3) reviews, letters, conference abstracts without full text, and duplicate publications.

Study selection and data extraction

Records were deduplicated in Zotero (v6) and screened independently by two reviewers (LZ, FT), first by title/abstract and then at full text; disagreements were resolved by consensus, with a third reviewer (PPP) arbitrating when necessary. Inter-rater agreement at full-text screening was calculated using Cohen's kappa. Patient-level data were extracted in duplicate using a pre-piloted standardised form (Supplementary Material) capturing study metadata, demographics, presentation, level of stenosis, syrinx location and extent, treatment and approach, and follow-up with clinical and radiological outcomes; verbatim outcome definitions are in Supplementary Table S2. An institutional index case, contributed using the same form and data items, is reported separately as an illustrative case and — not being identified through the predefined search — is excluded from the systematic-review cohort (n=28) and all pooled denominators (§ 3.2).

Risk-of-bias assessment

Methodological quality was appraised using the Joanna Briggs Institute (JBI) Critical Appraisal Checklist for Case Reports [21] and the corresponding checklist for Case Series. Each study was assessed independently by two reviewers (LZ and FT), with discrepancies resolved by consensus. The official JBI checklist items underlying each domain, together with the per-study domain-level ratings, are provided as Supplementary Table S1.

Data synthesis

Because of heterogeneous designs, follow-up and outcome definitions and a predominance of single-case reports, formal meta-analysis was not attempted. Patient-level data were synthesised descriptively as raw proportions (n/N) and percentages; continuous variables as mean (range). Primary outcomes were radiological regression and clinical improvement or stabilisation; secondary outcomes were operative approach and adverse events. Surgical and conservative cohorts were analysed separately; within the surgical cohort we distinguished a priori pre-existing syrinxes treated by decompression from those forming after prior surgery, and isolated the single case treated by combined decompression plus intradural shunting from the cumulative outcome analysis on account of its mechanistically distinct action.

Inferential statistics — including confidence intervals — were not applied to the aggregated cohort, because the included patients constitute a convenience sample of published reports rather than a probabilistically sampled population. No statistical comparison between approaches (anterior vs. posterior) was performed, given the small per-approach denominators and substantial confounding by indication. A pre-specified sensitivity analysis examining the impact of excluding the dominant retrospective series [11] is reported in § 3.7 and Table 5.

Results

Literature search and study characteristics

The database search retrieved 168 records; after removing 57 duplicates, 111 were screened by title and abstract and 87 excluded as clearly irrelevant. Of 24 full texts assessed, 12 were excluded — concomitant Chiari or other confounding aetiology (n = 5), insufficient clinical/radiological detail (n = 4), design incompatible with patient-level extraction (n = 2; including Yu and Moseley [22], a radiological case-control study of 88 syringomyelic patients addressing the syringomyelia–spondylosis relationship but not individual-level features), and duplicate publication (n = 1). Twelve studies — eight case reports, three case series and one retrospective cohort — met all criteria (Fig. 1; Cohen's $\kappa = 0.82$, almost perfect). The synthesis included 28 patients reported between 1987 and 2023 (Table 1); the institutional illustrative case (§ 3.2) is presented separately.

Illustrative case

A 63-year-old man presented with three months of progressive neck pain, right cervicobrachialgia and right-hand numbness. Examination showed bilateral reduced pain and temperature sensation in the C6–C7 dermatomes (dissociated sensory loss) with preserved strength (modified Japanese Orthopaedic Association score 17/18). Whole-neuraxis MRI showed a central/right-paracentral disc–osteophyte complex at C5–C6 with severe focal stenosis and a well-defined intramedullary T2-hyperintense cavity from C6 to C7 (–18 mm craniocaudal, 3 mm axial) (Fig. 2a, b); the craniocervical junction was normal, no other cord signal abnormality was seen, and post-gadolinium sequences excluded a tumour. Dynamic radiographs showed no instability. Single-level C5–C6 anterior cervical discectomy and fusion with posterior longitudinal ligament resection was performed, using a radiolucent polyetheretherketone (PEEK) cage that produces no MRI artefact. At four months the patient was neurologically intact with complete resolution of radicular pain, and MRI showed the syrinx stable without enlargement (Fig. 2c, d). Written informed consent for publication was obtained.

Patient demographics

Mean age at presentation was 54.9 years (range 33–81). There were 18 men (64.3%) and 10 women (35.7%). A single retrospective series [11] contributed 13 of the 28 patients and therefore substantially influenced the pooled demographic estimates.

Clinical presentation

The pooled data suggest two clinical phenotypes — symptomatic and asymptomatic — although this is heavily influenced by a single retrospective series and should not be read as a true epidemiological distribution. Twelve of the 28 patients (42.9%) were entirely asymptomatic, the syrinx identified incidentally on MRI for non-specific neck pain; all 12 derived from the Rahimizadeh et al. [11] series, so the asymptomatic phenotype rests entirely on that cohort and is best regarded as a clustering artefact of its inclusion criteria. The remaining 16 (57.1%) were symptomatic.

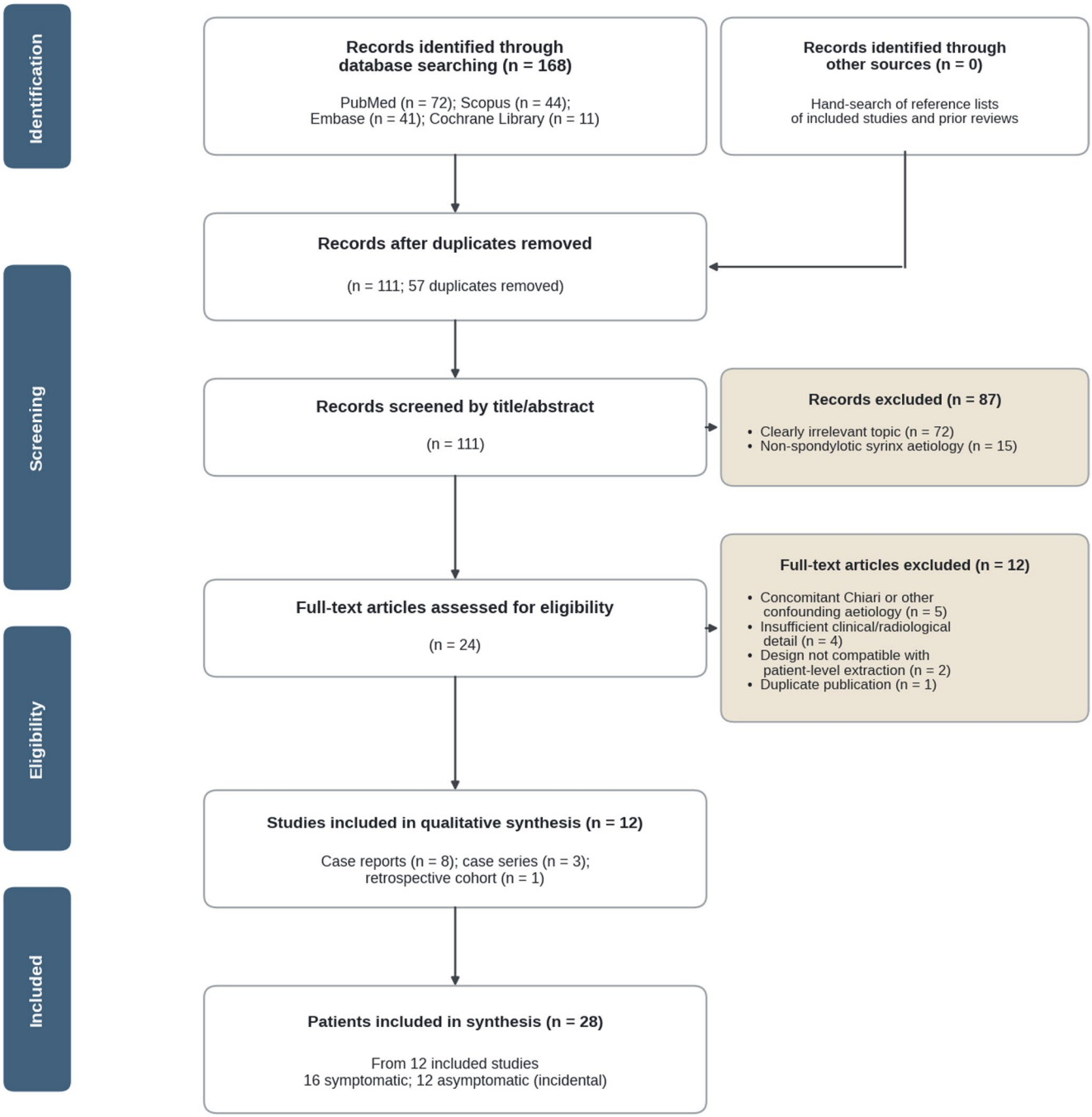

Fig. 1 PRISMA 2020 flow diagram for the systematic review

Among the 16 symptomatic patients, the most frequently reported features were motor weakness (paresis or tetraparesis) in 12 patients (75.0%), sensory deficits — including dissociated sensory loss of central-cord pattern — in 8 patients (50.0%), and axial neck or radicular upper-limb pain in 6 patients (37.5%). Less common findings included gait disturbance or ataxia and upper-motor-neuron signs (4 patients each, 25.0%) and sphincter dysfunction in 3 patients (18.8%) (Table 2).

Radiological findings

MRI was the primary diagnostic modality in all studies. Maximal canal stenosis was most commonly in the middle and lower cervical spine (C3–C7), attributable to disc–osteophyte complex, ligamentum flavum hypertrophy or combined anterior–posterior change; two reports described thoracic ossification of the ligamentum flavum as the causal lesion [23, 24]. No included report described a craniocervical-junction

Table 1 Characteristics of the included studies (12 studies, 28 patients). The institutional illustrative case (§ 3.2) is reported separately and is not part of the pooled cohort

First author (year)	Study design	Country	*N*	Age, mean (range)	Sex (M/F)
Middleton et al. [26]	Case report	USA	1	38	1/0
Kaar et al. [38]	Case report	UK	1	71	0/1
Kimura et al. [28]	Case report	Japan	1	64	0/1
Butteriss & Birchall [29]	Case report	UK	1	70	1/0
Arai et al. [23]	Case report	Japan	1	50	1/0
Landi et al. [30]	Case report	Italy	1	66	0/1
Bhagavathula Venkata et al. [25]	Case report	India	1	53	0/1
Badri et al. [37]	Case report	Tunisia	1	60	1/0
Pillich et al. [10]	Case series	Germany/Egypt	5	61.4 (50–81)	4/1
Athanasiou and Magras [27]	Case report	Greece	1	62	1/0
Rahimizadeh et al. [11]	Retrospective cohort	Iran	13	48.2 (33–68)	9/4
Punia et al. [24]	Case report	India	1	54	0/1
Total — systematic-review cohort (n=28)	—	—	28	54.9 (33–81)	18/10

abnormality meeting our exclusion criteria. Syrinx craniocaudal extent varied widely, from a focal one- or two-segment cavity to a holocord syrinx [24, 25]. In our patient-level extraction (Table 3), the syrinx lay adjacent to or cranial to the level of maximal compression in approximately three quarters of cases (11/15 with sufficient localisation detail).

Treatment strategies

Fourteen of the 28 patients (50.0%) underwent surgery; 14 (50.0%) were managed conservatively (Table 3). The choice of approach was determined by the location and nature of the compressive pathology. Posterior decompressive procedures were the most frequent, employed in 10 surgical patients (laminectomy ± instrumented fusion or laminoplasty in 9 cases plus the post-laminectomy syrinx case of Middleton et al. [26]), typically for multilevel or circumferential compression. An anterior approach (single- or multilevel ACDF, or anterior cervical corpectomy and fusion) was used in 3 surgical patients with predominantly anterior, focal compression [11, 27, 28]. One patient underwent extradural decompression combined with an intradural syringo-epiarachnoid shunt [23] on account of intraoperative findings of dense arachnoid adhesions (Table 3).

Reported follow-up was heterogeneous and often short: in the surgical cohort (n = 13), median approximately 12 months (range 1 month–5 years); in the conservatively managed asymptomatic cohort [11], serial imaging over 2 to 8 years. Of the conservative cohort (n = 14), 12 were asymptomatic incidental syrinxes [11] and 2 were symptomatic patients who declined surgery [10, 29].

Outcomes

Outcomes are reported for the 13 patients operated for an established syrinx; the post-laminectomy syrinx of Middleton et al. [26] is analysed separately. Because the evidence is predominantly single-case reports, no meta-analytic pooled estimate was calculated; patient-level outcomes are summarised as descriptive cumulative proportions stratified by approach (Fig. 3). Radiographic regression occurred in 2 of 3 patients after an anterior approach (67%) and 5 of 9 after a posterior approach (56%); the single patient treated by extradural decompression plus intradural syringo-epiarachnoid shunt [23] is considered separately. Overall, regression after extradural decompression alone occurred in 7 of 12 (58%), with no change in 4 and enlargement in 1 [30]. Clinically, 12 of 13 operated patients (92%) improved or stabilised at last follow-up; the one patient with documented deterioration [10, case 3] required salvage syringo-peritoneal shunting.

Among the 12 asymptomatic patients, the syrinx remained unchanged in 10 and resolved spontaneously in 2 over 3–8 years [11]. Of the 2 symptomatic patients who declined surgery, one was lost to follow-up [29] and one had slow tetraparesis progression [10, case 1]. Outcomes are summarised in Table 4; the pre-specified sensitivity analysis (Table 5) shows surgical proportions essentially unchanged when the dominant series [11] is excluded.

Risk-of-bias assessment

All included reports were case reports or small case series; no randomised or controlled study was identified. By the JBI tool, most studies adequately reported demographics, presentation, work-up and intervention, but outcome measurement was non-standardised, follow-up often short, and selective outcome reporting could not be excluded; a per-study, per-domain summary is provided in Table 6 (full appraisal in Supplementary Table S1). Overall confidence in the cumulative evidence is therefore low, and the descriptive proportions above should be read with this constraint in mind.

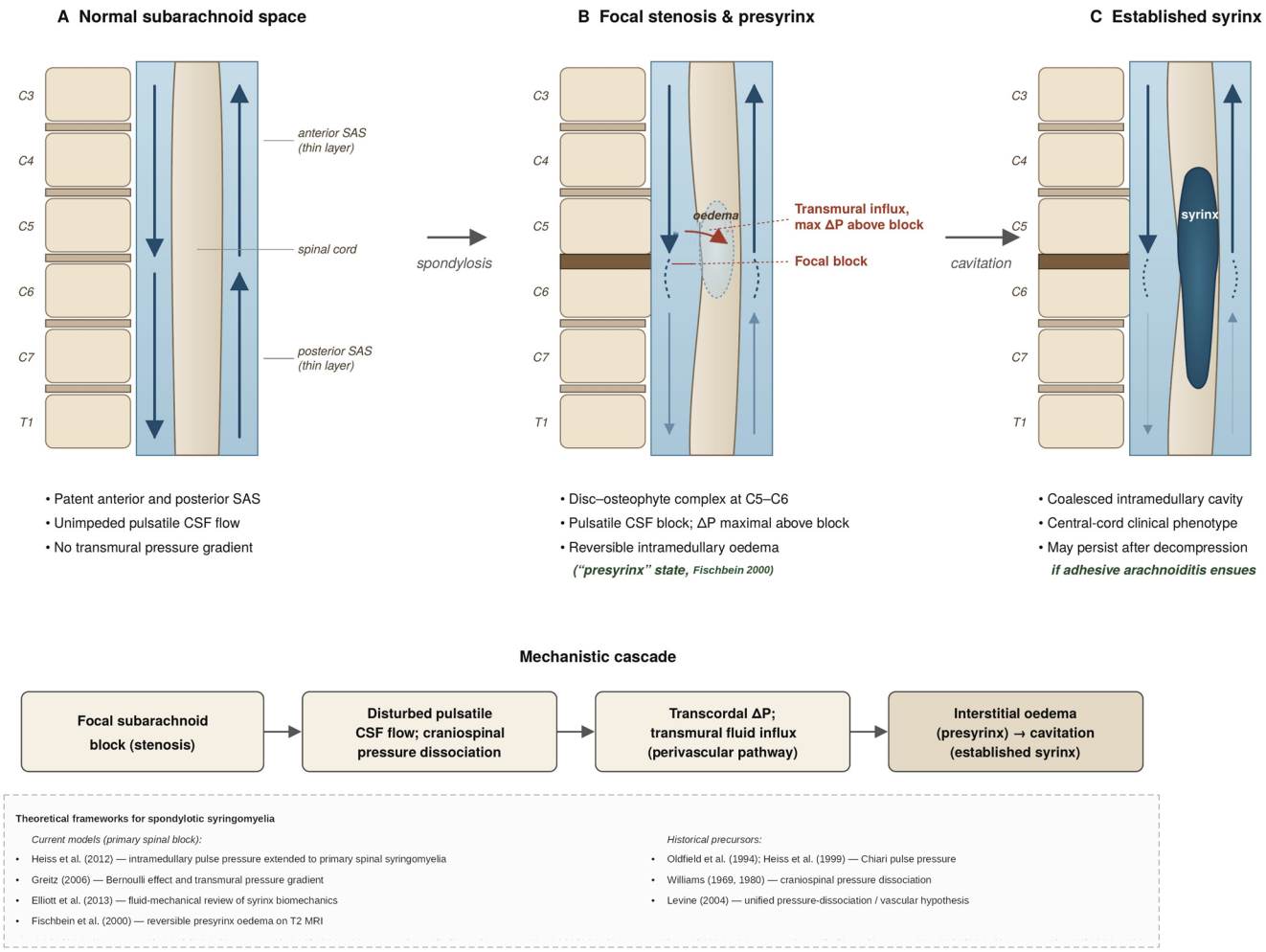

Fig. 2 Illustrative case. Pre-operative (**a**, sagittal T2; **b**, axial T2 at the level of the syrinx) and post-operative (**c**, sagittal T2; d, axial T2 at C6–C7) cervical MRI. (**a**) Multilevel cervical spondylosis with a C5–C6 disc–osteophyte complex and focal canal stenosis, and an intramedullary T2-hyperintense syrinx in the lower cervical cord; the craniocervical junction is normal, without tonsillar ectopia. (**b**) The syrinx as a well-defined central intramedullary cavity. (**c**, **d**) After single-level C5–C6 anterior cervical discectomy and fusion the syrinx remained stable in size; the interbody polyetheretherketone (PEEK) cage is radiolucent and produces no MRI susceptibility artefact. Orientation: anterior to the left in (**a**, **c**)

Table 2 Clinical presentation of the 16 symptomatic patients. Twelve additional patients from Rahimizadeh et al. [11] were asymptomatic at presentation and are not included in this table

Clinical feature	Patients (n = 16)	Proportion (%)
Motor weakness (paresis or tetraparesis)	12	75.0
Sensory deficit (including dissociated sensory loss)	8	50.0
Axial or radicular pain	6	37.5
Gait disturbance or ataxia	4	25.0
Upper-motor-neuron signs (hyperreflexia, Hoffmann, Babinski, spasticity)	4	25.0
Sphincter dysfunction	3	18.8

Proportions are descriptive, calculated as n/N (denominator: 16 symptomatic patients). No confidence intervals are reported because the included patients constitute a convenience sample of published cases rather than a probabilistically sampled population

Table 3 Radiological findings and management strategies

First author (year)	Level of stenosis	Syrinx extent	Management
Middleton et al. [26]	C3–C6 (spondylosis)	Cervical + upper thoracic	Posterior laminectomy C3–C6 (syrinx developed post-operatively)
Kaar et al. [38]	C3–C4 (spondylosis + instability)	C1–T2	Posterior decompression and fusion C3–C4
Kimura et al. [28]	C4–C5 and C6–C7	C2–T3	ACDF C4–C5 + C6–C7
Butteriss and Birchall [29]	C5–C6 and C6–C7	C6/7–T6	Conservative (surgery declined)
Arai et al. [23]	T9–T10 (OLF)	T8–T9	Laminectomy T9–T11 + syringo-epiarachnoid shunt
Landi et al. [30]	C3–C7/T1 (multilevel)	C3–T1	Laminectomy + posterior fusion (4-level)
Bhagavathula Venkata et al. [25]	C4–C6	Holocord	Laminectomy C3–C6
Badri et al. [37]	C3–C6 (circumferential)	C1–T3	Laminectomy C2–C6
Pillich et al. [10]	C2–C7 (variable)	Variable	2 laminectomy, 2 laminoplasty, 1 refused surgery
Athanasiou and Magras [27]	C5–C6	C5/6–T1	ACDF C5–C6
Rahimizadeh et al. [11]	C3–C7 (variable)	Mostly C5–C7; very small to large	12 conservative (asymptomatic); 1 ACDF (symptomatic radiculopathy)
Punia et al. [24]	T11–T12 (OLF)	Holocord (C3 to conus)	Laminectomy T11–T12

ACDF anterior cervical discectomy and fusion, *OLF* ossification of the ligamentum flavum

Discussion

Pathophysiological considerations

The mechanisms by which degenerative canal stenosis may produce a cord syrinx have been inferred largely from the Chiari-associated literature. Early theories invoked craniospinal pressure dissociation [18, 31], the systolic "water-hammer" effect of CSF [13, 32], and the piston-like action of descending cerebellar tonsils on the cervical subarachnoid space during systole [17]. Heiss et al. [15] formalised the "intramedullary pulse pressure" hypothesis, in which a transcordal pressure gradient drives interstitial fluid into the cord; this was later extended to primary spinal syringomyelia [33], showing that obstruction of the spinal subarachnoid space — of craniocervical or spinal origin — suffices to generate a syrinx-forming pressure environment. Greitz [14] proposed a Bernoulli-effect mechanism, Elliott et al. provided a comprehensive fluid-mechanical synthesis [34], and Levine [16] integrated these into a unifying model of craniospinal pressure dissociation and vascular dysfunction at the level of obstruction.

In cervical spondylosis, focal subarachnoid block from a disc–osteophyte complex, ligamentum flavum hypertrophy or congenital canal narrowing can plausibly substitute for the tonsillar obstruction of the Chiari patient; the central mechanistic element — disturbance of pulsatile CSF flow and of transcordal pressure equilibration — is preserved [35, 36]. That the syrinx most often lies immediately adjacent to, or cranial to, the site of maximal stenosis is consistent with this model (Table 3; Fig. 4). The "presyrinx" concept of Fischbein et al. [19] describes reversible intramedullary T2 hyperintensity that may resolve after decompression before a true cavity forms; cases with rapid post-operative regression [27, 28, 37] are consistent with such a substrate, whereas those in which the syrinx persists despite adequate decompression [10, 11, 30, 38] may represent organised cavitation, gliosis or adhesive arachnoiditis [39, 40]. As emphasised by Rahimizadeh et al. [11], chronic compression may produce local arachnoiditis that persists after extradural decompression and perpetuates the CSF-flow disturbance, potentially explaining some surgical failures.

The framework in Fig. 4 is inferential — extrapolated from the broader literature and not directly demonstrated in the included spondylotic cases, none of which provided dedicated mechanistic data (intraoperative pressure recordings or quantitative cine-MRI flow analysis). We therefore treat the relationship between degenerative stenosis and syrinx formation as a radiological and clinical association rather than an established causal mechanism, and present Fig. 4 as a hypothesis that has not been directly demonstrated in spondylotic cohorts.

Clinical and radiological correlation

The clinical phenotype of spondylotic syringomyelia is heterogeneous and almost always a composite of extrinsic compressive myelopathy and intrinsic syringomyelic symptomatology. A dissociated sensory loss of central-cord pattern, when present, is a useful pointer to an intramedullary component, but its absence in most cases means it is not sensitive. The insidious onset and overlap with uncomplicated cervical spondylotic myelopathy mean the syrinx is frequently identified only when MRI is performed for other reasons, mirroring the experience of Kaar et al. [38]. MRI remains the diagnostic gold standard [41], directly visualising both the compressive pathology and the intramedullary cavity and allowing exclusion of the principal differentials.

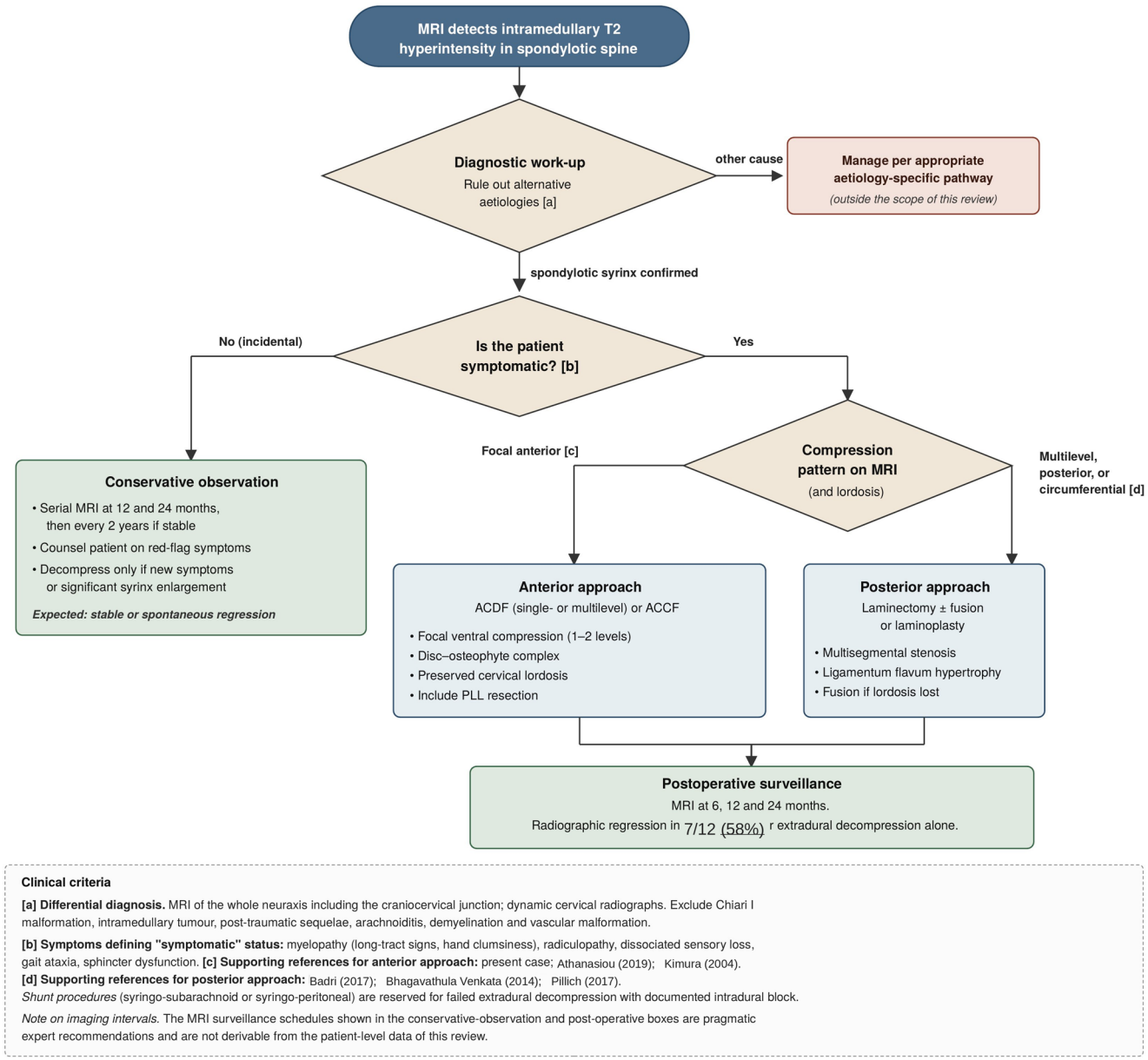

Fig. 3 Patient-level radiological outcome after surgery for spondylotic syringomyelia, stratified by surgical approach. Each bar represents one operated patient; colour denotes the radiological outcome at last follow-up (regression, no change, or enlargement). Cumulative regression rates are reported per approach; no formal meta-analytic pooled estimate was calculated because the evidence base consists predominantly of single-patient case reports. Middleton et al. [26] is excluded because the syrinx in that report developed as a sequela of laminectomy rather than being the target of surgery

Phase-contrast or cine MRI may disclose a focal CSF-flow block opposite the stenosis [25], although its prognostic value for post-operative regression is not established.

A specific diagnostic challenge is distinguishing a true syrinx from radiologically similar intramedullary changes, because it bears on prognosis and on the decision to operate. A true syrinx is a CSF-intensity, frequently eccentric or septated cavity that follows cerebrospinal-fluid signal on all sequences and tends to expand the cord. The presyrinx state of Fischbein et al. [19] is instead a reversible, non-cavitary T2 hyperintensity reflecting interstitial oedema, which may normalise once the subarachnoid block is relieved. Hydromyelia denotes a smooth, central-canal dilatation that, when small, may represent a persistent-central-canal variant of limited clinical significance. Myelomalacic (cystic) cavitation arises from chronic compressive and ischaemic cord injury: typically irregular and ill-defined, accompanying focal atrophy and gliosis, it reflects irreversible tissue loss rather than a pressure-driven cavity. The distinction is consequential, because presyrinx oedema and early hydromyelia

Table 4 Pre-specified sensitivity analysis: full dataset versus exclusion of the dominant retrospective series [11]

Outcome / cohort	Full dataset (n = 28)	Excluding Rahimizadeh (n = 15)
Total patients	28	15
Symptomatic patients	16	15
Asymptomatic patients	12	0
Patients undergoing surgery	14	13
Anterior approach: radiographic regression	2 / 3 (67%)	2 / 2 (100%)
Posterior approach: radiographic regression	5 / 9 (56%)	5 / 9 (56%)
Extradural decompression alone: radiographic regression	7 / 12 (58%)	7 / 11 (64%)
Extradural decompression + intradural shunt	1 / 1 (isolated)	1 / 1 (isolated)
Asymptomatic stable / regressed on serial imaging	12 / 12 (100%)	— (no data)

The surgical-cohort proportions are essentially unchanged after exclusion of the Rahimizadeh series; the conclusion that incidental, asymptomatic spondylotic syrinxes can be observed rests almost entirely on that single series and should be regarded as preliminary

Table 5 Clinical and radiological outcomes

Outcome	Patients (n)	Cumulative proportion
Operated patients stratified by surgical approach (n = 13)		
Anterior approach (ACDF / ACCF) — radiographic regression	2 / 3	67%
Posterior approach (laminectomy ± fusion or laminoplasty) — radiographic regression	5 / 9	56%
Extradural decompression alone (anterior + posterior) — radiographic regression	7 / 12	58%
Extradural decompression + intradural shunt (isolated: distinct mechanism)	1 / 1	—
Radiological no change (any approach)	4 / 13	31%
Radiological enlargement (any approach)	1 / 13	8%
Clinical improvement or stabilisation (any approach)	12 / 13	92%
Clinical deterioration (any approach)	1 / 13	8%
Post-laminectomy syrinx (n = 1)		
Middleton et al. [26]: syrinx formed after laminectomy for CSM; persisted on long-term MRI, with gradual partial clinical recovery	—	—
Conservatively managed patients (n = 14)		
Asymptomatic [11], no change over 3–8 y	10	—
Asymptomatic, spontaneous syrinx resolution	2	—
Symptomatic, declined surgery: lost to follow-up	1	—
Symptomatic, declined surgery: slow clinical progression	1	—

Cumulative proportions are descriptive patient-level summaries; because the evidence base consists predominantly of single-case reports, a formal meta-analytic pooled estimate (with inverse-variance weighting and a fixed- or random-effects model) was not calculated

Table 6 Compact per-study, per-domain summary of the JBI Critical Appraisal. Y = adequately addressed; U = unclear or partially addressed; N = not adequately addressed. Domain abbreviations: D1, demographic and clinical detail; D2, diagnostic workup; D3, intervention description; D4, outcome description; D5, follow-up adequacy; D6, adverse event reporting. The official JBI checklist items underlying each domain, together with the per-study domain-level ratings, are provided as Supplementary Table S1

Study	D1	D2	D3	D4	D5	D6
Middleton et al. [26]	Y	Y	Y	U	U	U
Kaar et al. [38]	Y	Y	Y	Y	Y	Y
Kimura et al. [28]	Y	Y	Y	Y	U	Y
Butteriss and Birchall [29]	Y	Y	Y	U	N	U
Arai et al. [23]	Y	Y	Y	Y	U	Y
Landi et al. [30]	Y	Y	Y	U	U	Y
Bhagavathula Venkata et al. [25]	Y	Y	Y	Y	U	Y
Badri et al. [37]	Y	Y	Y	Y	Y	Y
Pillich et al. [10]	Y	Y	Y	U	U	U
Athanasiou and Magras [27]	Y	Y	Y	Y	U	Y
Rahimizadeh et al. [11]	Y	Y	U	U	Y	U
Punia et al. [24]	Y	Y	Y	Y	U	Y



Fig. 4 Hypothesised pathophysiology of syringomyelia secondary to degenerative spinal canal stenosis. Three conceptual stages illustrated on sagittal schematics of the cervical spine: (**A**) normal subarachnoid space with unimpeded pulsatile CSF flow; (**B**) focal C5–C6 stenosis producing a pulsatile CSF block and a reversible intramedullary oedema (the "presyrinx" state, after Fischbein et al. [19]), with the transmural pressure gradient maximal above the block; (**C**) established spondylotic syrinx, which may persist after decompression if adhesive arachnoiditis ensues. Arrow thickness approximates CSF pulsatile amplitude. This figure represents an inferential mechanistic framework extrapolated from the broader Chiari and primary spinal syringomyelia literature; none of the included spondylotic case reports provided dedicated mechanistic data that would directly demonstrate this sequence in spondylotic patients. Abbreviations: CSF, cerebrospinal fluid; SAS, subarachnoid space; ΔP, transmural pressure gradient across the cord

frequently regress after decompression whereas established myelomalacic cavitation seldom does; heterogeneous inclusion of these entities across the primary studies may contribute to the variability of reported radiographic "regression" rates [12]. High-resolution T2-weighted imaging, supplemented where available by phase-contrast or cine and post-contrast sequences, aids this differentiation.

Accordingly, the diagnostic work-up should include MRI of the whole neuraxis with dedicated assessment of the craniocervical junction, together with dynamic cervical radiographs, to exclude an occult Chiari I malformation or tonsillar ectopia, an intramedullary tumour, arachnoiditis, a vascular malformation and demyelination before a syrinx is attributed to degenerative stenosis; post-gadolinium sequences are required to exclude an enhancing neoplasm. This staged exclusion was applied in our illustrative case (§ 3.2) and is reflected in the differential-diagnosis criteria of Fig. 5.

Asymptomatic incidental spondylotic syrinx

The Rahimizadeh series [11] is a qualitatively different contribution: a cohort of 13 patients, 12 asymptomatic, with prospective-like serial imaging over 2 to 7 years. Ten patients showed no radiological change, two had spontaneous

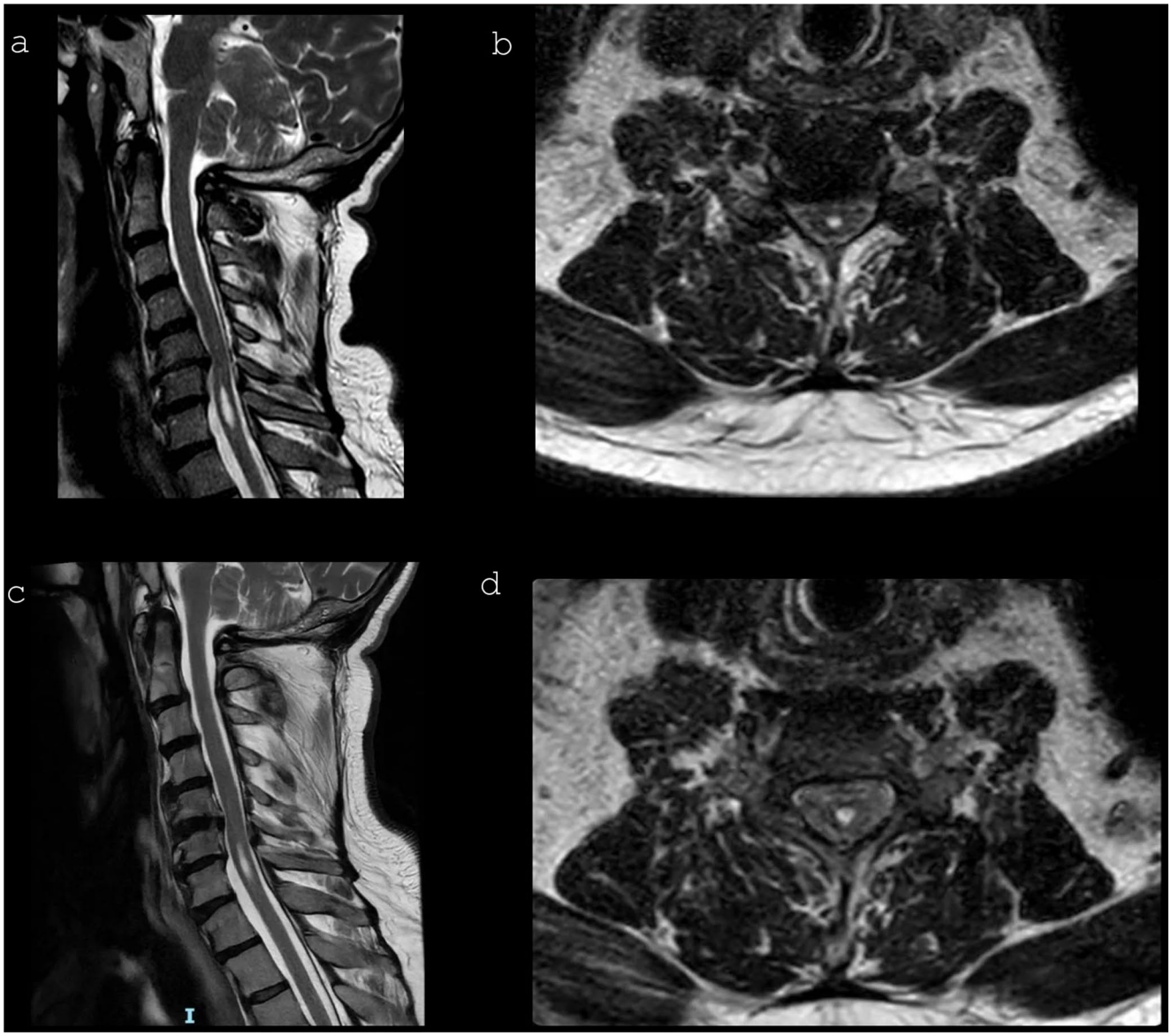

Fig. 5 Conceptual management paradigm for syringomyelia secondary to degenerative spinal canal stenosis, distilled descriptively from the patient-level data of the systematic review (12 studies, 28 patients). The flowchart is offered as an inferential framework summarising the clinical reasoning that emerges from the included reports; it does not constitute an evidence-based clinical algorithm in the formal sense, given the predominance of single-patient case reports and the absence of comparative data, and should be read consistently with the cautions stated in the Conclusion

resolution, and none deteriorated clinically. Selected incidental, asymptomatic cavities may therefore be suitable for surveillance, although this conclusion is dominated by a single retrospective series and warrants independent confirmation. As MRI is increasingly performed in older adults investigated for non-specific neck pain, incidental detection of small cord cavities is likely to become more frequent. A policy of serial imaging, with surgery reserved for patients who develop new symptoms, appears defensible on the available evidence; the data are insufficient to support routine prophylactic decompression.

Surgical management and outcomes

Spondylotic syringomyelia is a subset of cervical spondylotic disease, so the surgical decision must be framed within the broader evidence base on degenerative cervical myelopathy. The AOSpine North America guidelines [42, 43] identify decompression as the recommended treatment for moderate-to-severe cervical spondylotic myelopathy and as an option worth discussing for milder presentations with progressive deterioration; choice of approach is determined by sagittal alignment, levels of compression and the location of the compressive lesion. In syrinx-associated disease, radiographic syrinx behaviour is an additional, mechanistically informative endpoint beyond clinical outcome — but no uniform outcome instrument was applied in any included study (see § 4.5).

The choice of approach has been tailored to the site and geometry of the compressive lesion: an anterior approach (ACDF or ACCF) for focal anterior compression by a disc–osteophyte complex; a posterior approach (laminectomy ± instrumented fusion or laminoplasty) for multilevel stenosis, congenital canal narrowing or posterior compression by hypertrophied ligamentum flavum [44]. An expert-derived conceptual framework distilled from the patient-level data — not an evidence-based treatment algorithm — is summarised in Fig. 5.

Considered as cumulative descriptive proportions stratified by surgical approach, radiographic regression occurred in 2 of 3 patients after anterior decompression and in 5 of 9 after posterior decompression; overall, 7 of 12 patients treated by extradural decompression alone (58%) achieved regression, with a single additional cavity collapse after concomitant intradural shunting [23]. Approach-specific rates should not be read as comparative evidence: anterior procedures were chosen for focal, single-level disc–osteophyte disease (a more favourable substrate for regression), whereas posterior procedures addressed multilevel, congenitally narrow or posteriorly compressed canals. The stratified rates are therefore confounded by indication, anatomy of compression, multilevel disease and follow-up duration, and we deliberately avoid framing them as a meta-analytic pooled estimate.

Direct cavity drainage — syringo-subarachnoid, syringo-peritoneal or syringo-pleural shunting — is not a first-line option in compressive syringomyelia, in which the rational primary treatment is relief of the extradural block. In this review a shunt was used in a single patient [23], only as an intraoperative adjunct to laminectomy after dense arachnoid adhesions were encountered — to address a demonstrable intradural obstruction that decompression alone could not relieve. Reported indications for drainage or arachnoid procedures are correspondingly narrow: a syrinx that persists or enlarges with concordant clinical deterioration despite adequate decompression, or evidence of an intradural arachnoid block, for which arachnoidolysis with duraplasty is an alternative to shunt placement. Shunts are prone to obstruction, migration and late failure and carry a risk of catheter-related cord injury; the broader literature reports disappointing long-term outcomes of primary syrinx shunting [4], with a preference for restoring subarachnoid-space patency over direct cavity drainage in non-Chiari syringomyelia [45]. Even in the more extensively studied Chiari-associated syrinx, in which foramen-magnum decompression achieves regression in roughly four-fifths of adults [46], resolution may be incomplete or delayed and is not reliably predicted by baseline features [46, 47], and long-term series document a subset requiring reoperation [48] — reinforcing a decompression-first strategy with prolonged surveillance and reserving shunting for the minority with a demonstrated, decompression-refractory block. Radiological persistence does not universally preclude meaningful clinical recovery [10, 38]; conversely, progression after apparently adequate decompression [30] or de novo syrinx formation after decompressive laminectomy [26] are recognised, if uncommon, events warranting close postoperative surveillance.

Strengths and limitations

The principal strengths of this work are PRISMA 2020 compliance, pre-specified stratification by symptomatic status, and systematic re-extraction of patient-level data against the primary sources — to our knowledge, the first time this has been done for this topic.

Several limitations are important. First, the protocol was not prospectively registered; however, our criteria, extraction form and analytical plan were fixed in writing before extraction and are provided as Supplementary Material. Second, the evidence base is almost entirely case reports and small series, susceptible to publication bias, so descriptive regression rates should be considered an upper bound. Third, no standardised outcome score was reported consistently; definitions of “clinical improvement” and “radiographic regression” were heterogeneous and not directly comparable (Supplementary Table S2), precluding rigorous quantitative

assessment of efficacy. Fourth, a single retrospective series [11] contributes 13 of 28 patients and dominates the asymptomatic-cohort narrative; excluding it leaves 15 patients (all symptomatic) with surgical-cohort proportions essentially unchanged (Table 5), so the case for an indolent course of incidental syrinxes rests almost entirely on Rahimizadeh and should be regarded as preliminary. Fifth, the two thoracic OLF cases [23, 24] are biomechanically distinct from subaxial cervical spondylosis; we retained them on a shared pathophysiological basis, and the Arai case was already isolated from the cumulative outcome. Sixth, follow-up durations were variable and often short, particularly in the surgical cohort, limiting certainty about durability of regression. Finally, although no language restriction was applied, most included reports are in English and relevant non-English literature [9] is likely under-represented. A multicentre registry, or a collaborative individual-patient-data meta-analysis, is needed to refine natural-history and outcome estimates.

Conclusion

Syringomyelia secondary to degenerative spinal canal stenosis is rare and supported by a low-quality evidence base dominated by single-patient case reports. In symptomatic patients, extradural decompression directed at the causative stenosis — rather than primary cavity drainage — is the predominant strategy in the published literature and is associated with reported radiographic regression in 7 of 12 operated patients (58%); approach-stratified differences are confounded by indication and should not be read as comparative evidence. Selected asymptomatic incidental syrinxes were reported to remain radiologically stable on serial imaging in the only series large enough to address this question [11], but this observation derives almost entirely from that single retrospective series and warrants independent confirmation. Refining natural-history and outcome estimates will require a multicentre registry or collaborative individual-patient-data datasets using a standardised neurosurgical outcome instrument [49].

Supplementary Information The online version contains supplementary material available at https://doi.org/10.1007/s10143-026-04532-2.

Author contributions L.Z. and M.M.F. conceived and designed the study. L.Z., F.T., and P.P.P.designed the systematic review methodology. L.Z. and F.T. performed theliterature search, study screening, patient-level data extraction, andrisk-of-bias appraisal, with P.P.P. arbitrating disagreements. L.Z., F.T.,and P.P.P. performed the formal analysis and qualitative synthesis. L.Z.,M.M.F., and P.P.P. were responsible for the clinical management of theindex case described in §3.2. L.Z. prepared all figures and tables. L.Z.wrote the original draft of the manuscript. L.Z., F.T., P.P.P., and M.M.F.critically reviewed and edited the manuscript. P.P.P. and M.M.F. supervisedthe study. All authors read and approved the final version of the manuscript.

Funding The authors did not receive support from any organisation for the submitted work. No funds, grants or other support were received during the preparation of this manuscript.
Manuscript metrics (text only, excluding tables, figures, references and statements):

Data availability All data analysed during this systematic review are derived from previously published primary studies, fully cited in the reference list. The completed PRISMA 2020 checklist, the dated review protocol, the database-specific search strings, the patient-level data-extraction sheet, the full per-item JBI risk-of-bias appraisal (Supplementary Table S1) and the verbatim outcome definitions (Supplementary Table S2) are provided as Supplementary Material and are also available from the corresponding author upon reasonable request.

Declarations

Ethics approval This systematic review analysed only previously published, aggregate data and therefore did not require separate ethics approval. The clinical management of the index case described in § 3.2 was conducted in accordance with the principles of the Declaration of Helsinki. Ethical approval is not required at our institution for the publication of a single, de-identified clinical observation contributed to a systematic review.

Consent to participate Informed consent for participation in the clinical management was obtained from the patient described in § 3.2 in the standard manner of clinical care.

Consent to publish The authors affirm that the patient described as the index case in § 3.2 provided written informed consent for publication of the de-identified clinical data.

Clinical trial number Not applicable.

Competing interests The authors declare no competing interests.

References

1. Vandertop WP (2014) Syringomyelia Neuropediatrics 45:3–9. https://doi.org/10.1055/s-0033-1361921
2. Bogdanov EI, Heiss JD, Mendelevich EG, Mikhaylov IM, Haass A (2004) Clinical and neuroimaging features of idiopathic syringomyelia. Neurology 62:791–794. https://doi.org/10.1212/01.wnl.0000113746.47997.ce
3. Milhorat TH (2000) Classification of syringomyelia. Neurosurg Focus 8(3):E1. https://doi.org/10.3171/foc.2000.8.3.1
4. Klekamp J (2002) The pathophysiology of syringomyelia — historical overview and current concept. Acta Neurochir (Wien) 144:649–664. https://doi.org/10.1007/s00701-002-0944-3
5. Milhorat TH, Chou MW, Trinidad EM, Kula RW, Mandell M, Wolpert C, Speer MC (1999) Chiari I malformation redefined: clinical and radiographic findings for 364 symptomatic patients. Neurosurgery 44:1005–1017. https://doi.org/10.1097/00006123-199905000-00042
6. Brodbelt AR, Stoodley MA (2003) Post-traumatic syringomyelia: a review. J Clin Neurosci 10:401–408. https://doi.org/10.1016/s0967-5868(02)00326-0
7. Tavee JO, Levin KH (2015) Myelopathy due to degenerative and structural spine diseases. Continuum (Minneap Minn) 21(1 Spinal Cord Disorders. 52–66. https://doi.org/10.1212/01.CON.0000461084.71618.35

8. Lucci B, Reverberi S, Greco G (1981) Syringomyelia and syringomyelic syndrome by cervical spondylosis. Report on three cases presenting with neurogenic osteoarthropathies. J Neurosurg Sci 25:169–172
9. Rebai R, Boudawara MZ, Ben Yahia M, Mhiri C, Ben Mansour H (2002) Syringomyelobulbia associated with cervical spondylosis: pathophysiology and therapeutic implications. Neurochirurgie 48:120–123
10. Pillich D, El Refaee E, Mueller JU, Safwat A, Schroeder HWS, Baldauf J (2017) Syringomyelia associated with cervical spondylotic myelopathy causing canal stenosis. A rare association. Neurol Neurochir Pol 51:471–475. https://doi.org/10.1016/j.pjnns.2017.08.002
11. Rahimizadeh A, Amirzadeh M, Azadeh A (2022) Syrinx associated with cervical spondylosis: a report of 13 cases. Surg Neurol Int 13:315. https://doi.org/10.25259/SNI_504_2022
12. Giner J, Pérez López C, Hernández B, de la Gómez Á, Isla A, Roda JM (2019) Update on the pathophysiology and management of syringomyelia unrelated to Chiari malformation. Neurologia (Engl Ed) 34:318–325. https://doi.org/10.1016/j.nrleng.2018.10.004
13. Gardner WJ, Angel J (1958) The mechanism of syringomyelia and its surgical correction. Clin Neurosurg 6:131–140
14. Greitz D (2006) Unraveling the riddle of syringomyelia. Neurosurg Rev 29:251–263. https://doi.org/10.1007/s10143-006-0029-5
15. Heiss JD, Patronas N, DeVroom HL, Shawker T, Ennis R, Kammerer W, Eidsath A, Talbot T, Morris J, Eskioglu E, Oldfield EH (1999) Elucidating the pathophysiology of syringomyelia. J Neurosurg 91:553–562. https://doi.org/10.3171/jns.1999.91.4.0553
16. Levine DN (2004) The pathogenesis of syringomyelia associated with lesions at the foramen magnum: a critical review of existing theories and proposal of a new hypothesis. J Neurol Sci 220:3–21. https://doi.org/10.1016/j.jns.2004.01.014
17. Oldfield EH, Muraszko K, Shawker TH, Patronas NJ (1994) Pathophysiology of syringomyelia associated with Chiari I malformation of the cerebellar tonsils: implications for diagnosis and treatment. J Neurosurg 80:3–15. https://doi.org/10.3171/jns.1994.80.1.0003
18. Williams B (1980) On the pathogenesis of syringomyelia: a review. J R Soc Med 73:798–806. https://doi.org/10.1177/014107688007301109
19. Fischbein NJ, Dillon WP, Cobbs C, Weinstein PR (2000) The presyrinx state: is there a reversible myelopathic condition that may precede syringomyelia? Neurosurg Focus 8(3):E4. https://doi.org/10.3171/foc.2000.8.3.4
20. Page MJ, McKenzie JE, Bossuyt PM, Boutron I, Hoffmann TC, Mulrow CD, Shamseer L, Tetzlaff JM, Akl EA, Brennan SE, Chou R, Glanville J, Grimshaw JM, Hróbjartsson A, Lalu MM, Li T, Loder EW, Mayo-Wilson E, McDonald S, McGuinness LA, Stewart LA, Thomas J, Tricco AC, Welch VA, Whiting P, Moher D (2021) The PRISMA 2020 statement: an updated guideline for reporting systematic reviews. BMJ 372:n71. https://doi.org/10.1136/bmj.n71
21. Moola S, Munn Z, Tufanaru C, Aromataris E, Sears K, Sfetcu R, Currie M, Qureshi R, Mattis P, Lisy K, Mu P-F (2020) Chap. 7: Systematic reviews of etiology and risk. In: Aromataris E, Munn Z (eds) JBI Manual for Evidence Synthesis. Joanna Briggs Institute. https://doi.org/10.46658/JBIMES-20-08
22. Yu YL, Moseley IF (1987) Syringomyelia and cervical spondylosis: a clinicoradiological investigation. Neuroradiology 29:143–151. https://doi.org/10.1007/BF00327539
23. Arai A, Aihara H, Miyake S, Hanada Y, Kohmura E (2011) Syringomyelia due to thoracic spinal stenosis with ossified ligamentum flavum — case report. Neurol Med Chir (Tokyo) 51:157–159. https://doi.org/10.2176/nmc.51.157
24. Punia P, Chugh A, Gotecha S, Lachake A (2023) Single-level ossified ligamentum flavum causing a holocord syrinx: illustrative case. J Neurosurg Case Lessons 6(10):CASE23340. https://doi.org/10.3171/CASE23340
25. Bhagavathula Venkata SS, Arimappamagan A, Lafazanos S, Pruthi N (2014) Syringomyelia secondary to cervical spondylosis: case report and review of literature. J Neurosci Rural Pract 5(Suppl 1):S78–S82. https://doi.org/10.4103/0976-3147.145215
26. Middleton TH, Al-Mefty O, Harkey LH, Parent AD, Fox JL (1987) Syringomyelia after decompressive laminectomy for cervical spondylosis. Surg Neurol 28:458–462. https://doi.org/10.1016/0090-3019(87)90230-8
27. Athanasiou A, Magras I (2019) Syringomyelia resolution after anterior cervical discectomy: a case report and literature review. Surg Neurol Int 10:42. https://doi.org/10.25259/SNI-91-2019
28. Kimura R, Park YS, Nakase H, Sakaki T (2004) Syringomyelia caused by cervical spondylosis. Acta Neurochir (Wien) 146:175–178. https://doi.org/10.1007/s00701-003-0172-5
29. Butteriss DJ, Birchall D (2006) A case of syringomyelia associated with cervical spondylosis. Br J Radiol 79:e123–e125. https://doi.org/10.1259/bjr/27982692
30. Landi A, Nigro L, Marotta N, Mancarella C, Donnarumma P, Delfini R (2013) Syringomyelia associated with cervical spondylosis: a rare condition. World J Clin Cases 1:111–115. https://doi.org/10.12998/wjcc.v1.i3.111
31. Williams B (1969) The distending force in the production of communicating syringomyelia. Lancet 2(7613):189–193. https://doi.org/10.1016/s0140-6736(69)91427-5
32. Du Boulay G, Shah SH, Currie JC, Logue V (1974) The mechanism of hydromyelia in Chiari type 1 malformations. Br J Radiol 47:579–587. https://doi.org/10.1259/0007-1285-47-561-579
33. Heiss JD, Snyder K, Peterson MM, Patronas NJ, Butman JA, Smith RK, DeVroom HL, Sansur CA, Eskioglu E, Kammerer WA, Oldfield EH (2012) Pathophysiology of primary spinal syringomyelia. J Neurosurg Spine 17:367–380. https://doi.org/10.3171/2012.8.SPINE111059
34. Elliott NSJ, Bertram CD, Martin BA, Brodbelt AR (2013) Syringomyelia: a review of the biomechanics. J Fluids Struct 40:1–24. https://doi.org/10.1016/j.jfluidstructs.2013.01.010
35. Heidari Pahlavian S, Bunck AC, Loth F, Shane Tubbs R, Yiallourou T, Kroeger JR, Heindel W, Martin BA (2015) Characterization of the discrepancies between four-dimensional phase-contrast magnetic resonance imaging and in-silico simulations of cerebrospinal fluid dynamics. J Biomech Eng 137:051002. https://doi.org/10.1115/1.4029699
36. Martin BA, Yiallourou TI, Pahlavian SH, Thyagaraj S, Bunck AC, Loth F, Sheffer DB, Kröger JR, Stergiopulos N (2016) Inter-operator reliability of magnetic resonance image-based computational fluid dynamics prediction of cerebrospinal fluid motion in the cervical spine. Ann Biomed Eng 44:1524–1537. https://doi.org/10.1007/s10439-015-1449-6
37. Badri M, Gader G, Bahri K, Zammel I (2017) Cervicothoracic syringomyelia caused by cervical spinal stenosis: case report and literature review. Surg Neurol Int 8:288. https://doi.org/10.4103/sni.sni_350_17
38. Kaar GF, N'Dow JM, Bashir SH (1996) Cervical spondylotic myelopathy with syringomyelia. Br J Neurosurg 10:413–415
39. Bilston LE, Stoodley MA, Fletcher DF (2010) The influence of the relative timing of arterial and subarachnoid space pulse waves on spinal perivascular cerebrospinal fluid flow as a possible factor in syrinx development. J Neurosurg 112:808–813. https://doi.org/10.3171/2009.5.JNS08945
40. Stoodley MA, Brown SA, Brown CJ, Jones NR (1997) Arterial pulsation-dependent perivascular cerebrospinal fluid flow into the central canal in the sheep spinal cord. J Neurosurg 86:686–693. https://doi.org/10.3171/jns.1997.86.4.0686
41. Al-Mefty O, Harkey LH, Middleton TH, Smith RR, Fox JL (1988) Myelopathic cervical spondylotic lesions demonstrated by

magnetic resonance imaging. J Neurosurg 68:217–222. https://doi.org/10.3171/jns.1988.68.2.0217
42. Fehlings MG, Wilson JR, Kopjar B, Yoon ST, Arnold PM, Massicotte EM, Vaccaro AR, Brodke DS, Shaffrey CI, Smith JS, Woodard EJ, Banco RJ, Chapman JR, Janssen ME, Bono CM, Sasso RC, Dekutoski MB, Gokaslan ZL (2013) Efficacy and safety of surgical decompression in patients with cervical spondylotic myelopathy: results of the AOSpine North America prospective multi-center study. J Bone Joint Surg Am 95:1651–1658. https://doi.org/10.2106/JBJS.L.00589
43. Fehlings MG, Tetreault LA, Riew KD, Middleton JW, Aarabi B, Arnold PM, Brodke DS, Burns AS, Carette S, Chen R, Chiba K, Dettori JR, Furlan JC, Harrop JS, Holly LT, Kalsi-Ryan S, Kotter M, Kwon BK, Martin AR, Milligan J, Nakashima H, Nagoshi N, Rhee J, Singh A, Skelly AC, Sodhi S, Wilson JR, Yee A, Wang JC (2017) A clinical practice guideline for the management of patients with degenerative cervical myelopathy. Glob Spine J 7(3 Suppl):70S–83S. https://doi.org/10.1177/2192568217701914
44. Klekamp J (2017) Surgical treatment of multilevel cervical spondylosis in patients with or without a history of syringomyelia. Eur Spine J 26:948–957. https://doi.org/10.1007/s00586-017-4977-y
45. Lee JH, Chung CK, Kim HJ (2002) Decompression of the spinal subarachnoid space as a solution for syringomyelia without Chiari malformation. Spinal Cord 40:501–506. https://doi.org/10.1038/sj.sc.3101322
46. Perrini P, Anania Y, Cagnazzo F, Benedetto N, Morganti R, Di Carlo DT (2021) Radiological outcome after surgical treatment of syringomyelia-Chiari I complex in adults: a systematic review and meta-analysis. Neurosurg Rev 44:177–187. https://doi.org/10.1007/s10143-020-01239-w
47. Jain A, MacElroy D, Malhotra A, Thomas Z, Bienenstock R, Carpenter A, Zeller S, Muh CR, Kinon MD (2025) Predictive potential of radiographic characteristics on outcomes after Chiari decompression surgery: a meta-analysis of the literature. Clin Neurol Neurosurg 259:109204. https://doi.org/10.1016/j.clineuro.2025.109204
48. Alfieri A, Pinna G (2012) Long-term results after posterior fossa decompression in syringomyelia with adult Chiari Type I malformation. J Neurosurg Spine 17:381–387. https://doi.org/10.3171/2012.7.SPINE12272
49. Davies BM, Khan DZ, Mowforth OD, McNair AGK, Gronlund T, Kolias AG, Tetreault L, Starkey ML, Sadler I, Sarewitz E, Houlton D, Carter J, Kalsi-Ryan S, Aarabi B, Kwon BK, Kurpad SN, Harrop J, Wilson JR, Grossman R, Curt A, Fehlings MG, Kotter MRN (2019) RE-CODE DCM (REsearch Objectives and Common Data Elements for Degenerative Cervical Myelopathy): a consensus process to improve research efficiency in DCM. Glob Spine J 9(1 Suppl):65S–76S. https://doi.org/10.1177/2192568219832855

Publisher's note Springer Nature remains neutral with regard to jurisdictional claims in published maps and institutional affiliations.

Springer Nature or its licensor (e.g. a society or other partner) holds exclusive rights to this article under a publishing agreement with the author(s) or other rightsholder(s); author self-archiving of the accepted manuscript version of this article is solely governed by the terms of such publishing agreement and applicable law.