

Combined endovascular and open treatment to prevent increase in afterload in anastomotic pseudoaneurysm and aortobronchial fistula after surgery for aortic coarctation

Franco Nodari, MD,^a Apollonia Verrengia, MD,^a Ernesto Di Betta, MD,^a Giulia Bonera, MD,^b and Stefano Bonardelli, MD,^a *Brescia, Italy*

ABSTRACT

We report the treatment of a patient who had presented with hemoptysis due to an aortobronchial fistula from an anastomotic pseudoaneurysm after extra-anatomic bypass for aortic coarctation. An aortobronchial fistula can often result from an aortic pseudoaneurysm and is associated with high mortality if not treated. We decided to use combined endovascular and open surgical treatment and obtained a satisfactory intraoperative result. The perioperative outcome and first follow-up visit were favorable. In recent years, endovascular repair of pathologic aortic conditions has increased; thus, we have placed the present case within the context of the relevant medical literature. (*J Vasc Surg Cases Innov Tech* 2021;7:621-4.)

Keywords: Anastomotic pseudoaneurysm; Aortic coarctation; Aortic endoprosthesis; Aortobronchial fistula; Axillofemoral bypass

The open repair of aortic coarctation (AC) is a valid therapeutic approach; however, as in the present case, some late complications can occur, including anastomotic pseudoaneurysm and aortobronchial fistula. Some series have demonstrated the safety of endovascular treatment in the case of late complications after open surgical treatment of AC. In the present case, the satisfactory perioperative and postoperative outcomes seem to suggest the success of a combined open and endovascular approach. The patient gave her written consent for the report of her case and imaging studies.

CASE REPORT

In July 2020, a 78-year-old woman presented at our institution because of episodes of hemoptysis for 3 days. In 1983, she had undergone surgical treatment of an AC at a different vascular surgical institute, which included an extra-anatomic prosthetic bypass from the left subclavian artery to the descending

thoracic aorta (DTA). The Dacron graft was connected to the left subclavian artery shortly after its origin and, running along the aortic course, ended in the DTA immediately after the AC (Fig 1). On arrival, her clinical examination showed normal vital signs, no fever, and no nausea or vomiting. Hematologic investigations did not find any anemia or leukocytosis. A computed tomography (CT) scan was performed and showed the presence of the aorta coarctation with a short residual isthmus of an 8-mm caliber at the lower part of the aortic arch and patency of the previous bypass, with a distal anastomotic pseudoaneurysm partially thrombosed that extended by 3 cm (Fig 1). The CT scan also showed suspicious signs of a distal perianastomotic aortobronchial fistula.

Because of the CT evidence and the episodes of hemoptysis, urgent treatment was indicated. A combined endovascular and open approach with the patient under general anesthesia was agreed on. Antibiotic prophylaxis was initiated and was continued into the postoperative period. First, the left axillary and left common femoral artery (CFA) were surgically isolated, allowing for creation of an axillofemoral prosthetic polytetrafluoroethylene 8-mm bypass. Second, the right CFA was dissected and checked, and a diagnostic angiogram was performed after selective catheterization of the previous bypass to confirm the presence of the distal anastomotic aneurysm. Via the right CFA, a 22-mm Amplatzer plug (Abbott Laboratories, Chicago, Ill), was deployed into the middle distal segment of the previous bypass (Fig 2). Third, an endoprosthesis (31 × 31 × 100 mm; Gore conformable TAG stent-graft; W.L. Gore & Associates, Newark, Del) was placed into DTA, distal to the coarctation and excluding the bypass and, therefore, the anastomotic pseudoaneurysm. Finally, at the completion arteriogram, late perfusion of the pseudoaneurysm remained. Therefore, two Penumbra packing coils (Penumbra, Inc,

From the Division of Vascular Surgery, Department of Clinical and Experimental Sciences,^a and Division of Radiology, Department of Surgical Specialties, Radiological Sciences and Public Health,^b University of Brescia and Spedali Civili Hospital.

Author conflict of interest: none.

Correspondence: Apollonia Verrengia, MD, Division of Vascular Surgery, Department of Clinical and Experimental Sciences, University of Brescia and Spedali Civili Hospital, Via Adda, 4 – Brusaporto, Brescia, Bergamo 24060, Italy (e-mail: ap.verrengia@gmail.com).

The editors and reviewers of this article have no relevant financial relationships to disclose per the Journal policy that requires reviewers to decline review of any manuscript for which they may have a conflict of interest.

2468-4287

© 2021 Published by Elsevier Inc. on behalf of Society for Vascular Surgery. This is an open access article under the CC BY-NC-ND license (<http://creativecommons.org/licenses/by-nc-nd/4.0/>).

<https://doi.org/10.1016/j.jvscit.2021.08.001>

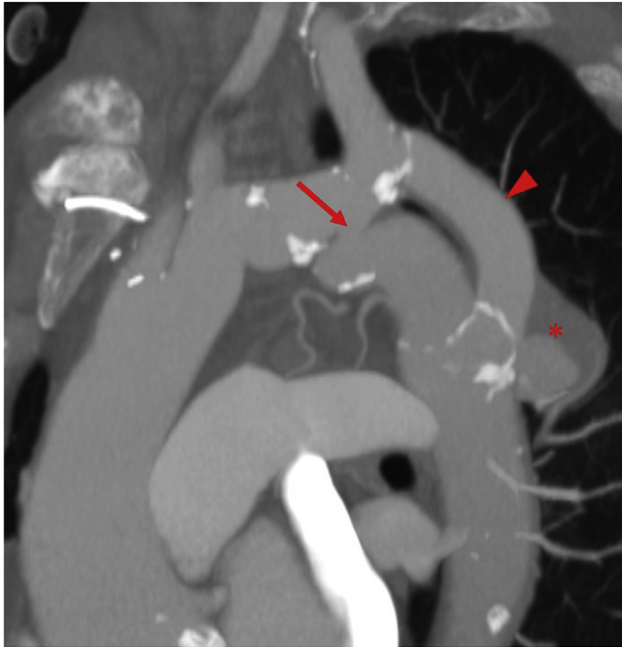


Fig 1. Preoperative computed tomography (CT) reconstruction showing coarctation of the aorta (AC) with a short residual isthmus (arrow) at the lower part of the aortic arch, the previous bypass (arrowhead) with a distal anastomotic pseudoaneurysm (asterisk).

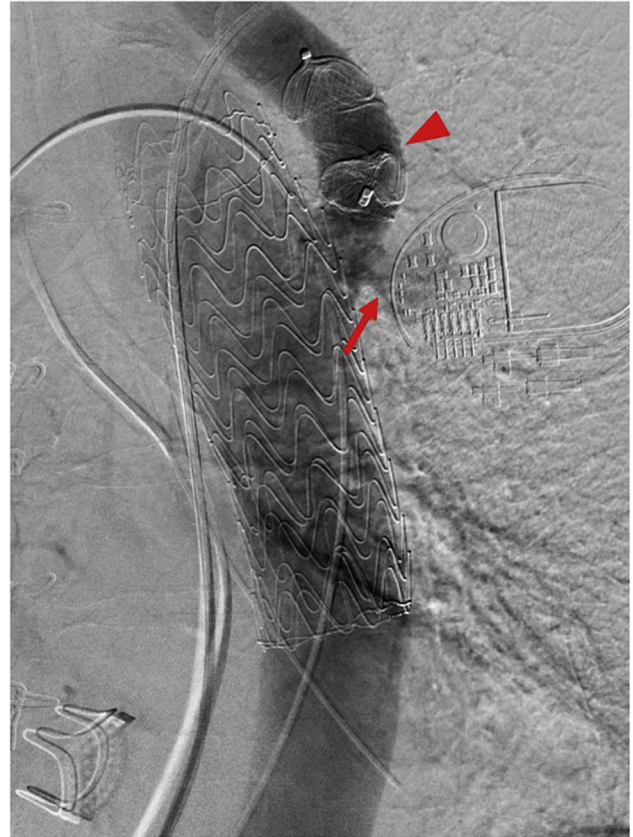


Fig 2. Intraoperative angiogram via the right common femoral artery (CFA) showing a 22-mm Amplatzer plug (Abbott Laboratories) deployed into the middle distal segment of the previous bypass (arrowhead). Late perfusion of the pseudoaneurysm remained (arrow).

Alameda, Calif) were positioned at the origin of the subclavian–aortic bypass, upstream from the previously placed plug (Fig 3).

A CT scan was performed on the fifth postoperative day and confirmed good stent positions and the total exclusion of the anastomotic aneurysm. The postoperative course was uneventful, and the patient was discharged from the hospital on the eighth postoperative day. At the 4-month follow-up visit, the patient reported good health, no asthenia, dyspnea, or claudication, and no further episodes of hemoptysis. Also, the differential artery pressure in the four limbs was not significantly different. The CT scans performed 4 months after surgery showed a reduction in the diameter of the pseudoaneurysm sac, total exclusion of the subclavian–aortic bypass, no signs of endoleak, and a regular axillofemoral left bypass (Figs 4 and 5).

DISCUSSION

Although AC accounts for 5% to 8% of congenital heart defects, its presentation varies and ~15% to 20% of patients will remain asymptomatic into adulthood, which was case for our patient.^{1,2} Open repair of an AC is a valid therapeutic approach with excellent results. However, some late complications have been described, including aneurysm, pseudoaneurysm, aortobronchial and aorto-esophageal fistulas, dissection, and recurrent AC.³ The formation of an anastomotic pseudoaneurysm and aortic aneurysm is one of the most frequent late complications after open surgical treatment of AC, with a rate of 3% to 38%.^{4,5} The complication has been described without

any significant differences after various surgical techniques, including resection and end-to-end anastomosis, subclavian patch repair, synthetic patch repair, and bypass. Aorto-esophageal and aortobronchial fistulas can appear from 3 weeks to 25 years after bypass for AC.^{6,7} The main causes have been infection or related to mechanical failure of the anastomosis. For our patient, all the blood indexes of inflammation were normal on her admission to the hospital (white blood cell count, C-reactive protein, procalcitonin). She had not experienced fever, and the results of all culture tests (peripheral and central blood cultures, real-time polymerase chain reaction testing for *Candida*) performed were negative. We attributed the cause of the pseudoaneurysm and consequent fistula to mechanical anastomotic failure. Therefore, in agreement with the infectious disease specialists, it was not considered necessary to prescribe long-term antibiotic treatment. We gave the patient preoperative antibiotic prophylaxis that was extended for 72 hours after surgery, the same as for all our endovascular surgical procedures or in the case of prosthetic graft placement.

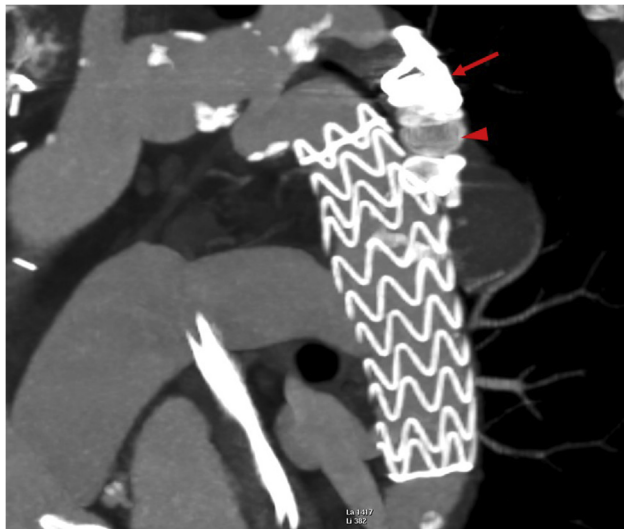


Fig 3. Postoperative computed tomography (CT) reconstruction showing Penumbra packing coils (Penumbra, Inc; arrow) positioned in the subclavian–aortic bypass upstream from the previously placed plug (arrowhead) with complete exclusion of the anastomotic aneurysm.

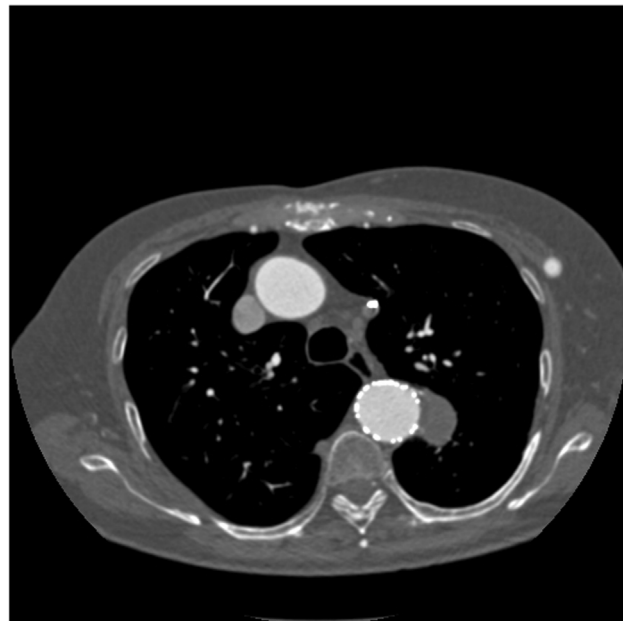


Fig 5. Axial reconstruction of 4-month follow-up computed tomography (CT) scan.

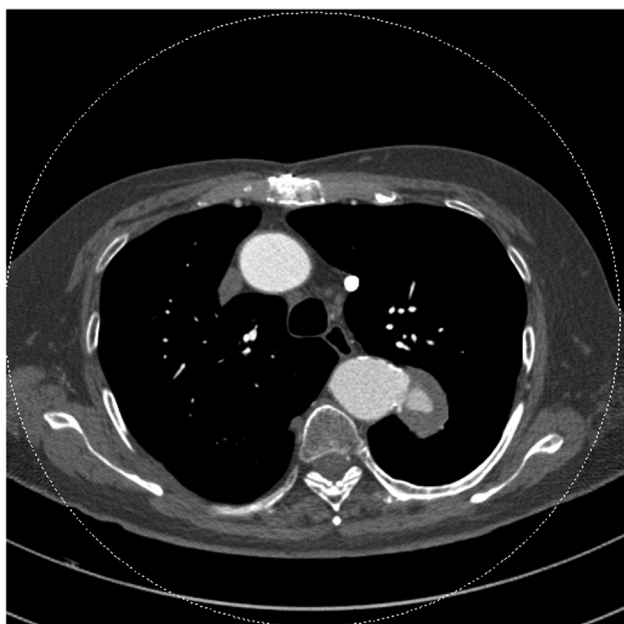


Fig 4. Axial reconstruction of preoperative computed tomography (CT) scan.

Some series have demonstrated the safety of endovascular treatment of late complications after open surgery for AC. However, a multidisciplinary decision should always be made before proceeding. Recently reported studies on the use of thoracic endovascular aortic repair in adult patients with an aneurysm after surgery of AC have shown excellent technical success rates of 91% to 100% and no 30-day mortality.^{3,8} In the past decade, several case reports have shown the initial success of

using thoracic stents to treat aortobronchial fistulas. A literature review of thoracic endovascular aortic repair for aortobronchial fistulas reported a recurrence fistula rate of 11.2% and stent-graft infection in 1.7% of patients.⁹ Moreover, the perioperative outcomes with this approach appear to be characterized by low 30-day mortality (6.4%).⁹ In contrast, the reported operative mortality of open repair has ranged from 15% to 41%.¹⁰ With this evidence and the anatomic features in our patient, we decided to use a combined open and endovascular approach. To reduce the risk of creating overly high blood pressure in the pre-coarctation aortic tract, left axillofemoral bypass was performed before closing the previous bypass with an Amplatzer plug (Abbott Laboratories), excluding the pseudoaneurysm and aortobronchial fistula.

The perioperative outcomes and postoperative follow-up findings for our patient seem to suggest the success of this therapeutic approach. Although many recent reviews have indicated the endovascular approach as the most valid, we believe that, because severe complications can occur after this treatment, patients will require continued close monitoring. Also, studies of a greater number of patients with long-term follow-up are warranted to further define the role of endovascular treatment for adult patients with late complications after open surgery for AC.

We thank Mr Kris Hagan, Language School, Milan, Italy.

REFERENCES

1. Warnes CA, Williams RG, Bashore TM, Child JS, Connolly HM, Dearani JA, et al. ACC/AHA 2008 guidelines for the management of adults with congenital heart disease: executive summary: a report of

- the American College Of Cardiology/American Heart Association Task Force on Practice Guidelines (writing committee to develop guidelines for the management of adults with congenital heart disease). *Circulation* 2008;118:2395-451.
- Turner DR, Gaines PA. Endovascular management of coarctation of the aorta. *Semin Intervent Radiol* 2007;24:153-66.
 - Lala S, Scali ST, Feezor RJ, Chandrekashar S, Giles KA, Fatima J, et al. Outcomes of thoracic endovascular aortic repair in adult coarctation patients. *J Vasc Surg* 2018;67:369-81.e2.
 - Von Kodolitsch Y, Aydin MA, Koschyk DH, Loose R, Schalwat I, Karck M, et al. Predictors of aneurysmal formation after surgical correction of aortic coarctation. *J Am Coll Cardiol* 2002;39:617-24.
 - Knyshov GC, Sitar LL, Glagola MD, Atamanyuk MY. Aortic aneurysm at the site of repair of coarctation of the aorta: a review of 48 patients. *Ann Thorac Surg* 1996;61:935-9.
 - Myers PO, Gemayel G, Mugnai D, Murith N, Kalangos A. Endovascular exclusion of aorto-esophageal fistula after coarctation extra-anatomical bypass. *Ann Thorac Surg* 2014;98:314-6.
 - Bozzani A, Arici V, Rodolico G, Brunetto MB, Argentero A. Endovascular exclusion of aortobronchial fistula and distal anastomotic aneurysm after extra-anatomic bypass for aortic coarctation. *Tex Heart Inst J* 2017;44:55-7.
 - Kotelis D, Bischoff MS, Rengier F, Ruhparwar A, Gorenflo M, Böckler D. Endovascular repair of pseudoaneurysms after open surgery for aortic coarctation. *Interact Cardiovasc Thorac Surg* 2016;22:26-31.
 - Canaud L, Ozdemir BA, Bahia S, Hinchliffe R, Loftus I, Thompson M. Thoracic endovascular aortic repair for aortobronchial fistula. *Ann Thorac Surg* 2013;96:1117-21.
 - Piciche M, De Paulis R, Fabbri A, Chiariello L. Postoperative aortic fistulas into the airways: etiology, pathogenesis, presentation, diagnosis, and management. *Ann Thorac Surg* 2003;75:1998-2006.

Submitted Apr 23, 2021; accepted Aug 5, 2021.