





## ORIGINAL RESEARCH ARTICLE

# Obliterated cavum septi pellucidi: Clinical significance and role of fetal magnetic resonance

Ilaria Fantasia<sup>1</sup>  | Claudia Ciardo<sup>2</sup> | Gabriella Bracalente<sup>3</sup> | Elisa Filippi<sup>3</sup> |  
 Flora Maria Murru<sup>4</sup> | Anita Spezzacatene<sup>4</sup> | Maura Bin<sup>5</sup> | Olivia Mendez Quintero<sup>6</sup> |  
 Elisa Montaguti<sup>7</sup> | Christoph Lees<sup>8</sup>  | Katherine Papanikolaou<sup>8</sup> | Gianluigi Pilu<sup>7</sup> |  
 Federico Prefumo<sup>9</sup>  | Baskaran Thilaganathan<sup>6</sup> | Tamara Stampalija<sup>1,10</sup> 

<sup>1</sup>Unit of Fetal Medicine, Institute for Maternal and Child Health, IRCCS "Burlo Garofolo", Trieste, Italy

<sup>2</sup>Department of Gynecology and Obstetrics, Ospedale Fracastoro, San Bonifacio, Italy

<sup>3</sup>UOC Gynecology and Obstetrics, Ospedale Cà Foncello Treviso, Treviso, Italy

<sup>4</sup>Radiology Service, Institute for Maternal and Child Health, IRCCS "Burlo Garofolo", Trieste, Italy

<sup>5</sup>Division of Child Neurology and Psychiatry, Institute for Maternal and Child Health, IRCCS "Burlo Garofolo", Trieste, Italy

<sup>6</sup>Fetal Medicine Unit, Saint George's Hospital, London, UK

<sup>7</sup>Obstetric Unit, IRCCS Azienda Ospedaliero Universitaria di Bologna, Bologna, Italy

<sup>8</sup>Centre for Fetal Care, Queen Charlotte's & Chelsea Hospital, Imperial College Healthcare NHS Trust, London, UK

<sup>9</sup>Obstetrics and Gynecology Unit, IRCCS Istituto Giannina Gaslini, Genoa, Italy

<sup>10</sup>Department of Medical, Surgical and Health Sciences, University of Trieste, Trieste, Italy

## Correspondence

Ilaria Fantasia, Unit of Fetal Medicine and Prenatal Diagnosis, Institute for Maternal and Child Health, IRCCS "Burlo Garofolo", Via dell'Istria 65/1, 34137 Trieste, Italy. Email: [ilaria.fantasia@burlo.trieste.it](mailto:ilaria.fantasia@burlo.trieste.it)

## Abstract

**Introduction:** The objective of this study was to describe a cohort of fetuses with an ultrasound prenatal diagnosis of obliterated cavum septi pellucidi (oCSP) with the aim to explore the rate of associated malformations, the progression during pregnancy and the role of fetal magnetic resonance imaging (MRI).

**Material and methods:** This was a retrospective multicenter international study of fetuses diagnosed with oCSP in the second trimester with available fetal MRI and subsequent ultrasound and/or fetal MRI follow-up in the third trimester. Where available, postnatal data were collected to obtain information on neurodevelopment.

**Results:** We identified 45 fetuses with oCSP at 20.5 weeks (interquartile range 20.1–21.1). oCSP was apparently isolated at ultrasound in 89% (40/45) and fetal MRI found additional findings in 5% (2/40) of cases, including polymicrogyria and microcephaly. In the remaining 38 fetuses, fetal MRI found a variable amount of fluid in CSP in 74% (28/38) and no fluid in 26% (10/38). Ultrasound follow-up at or after 30 weeks confirmed the diagnosis of oCSP in 32% (12/38) while fluid was visible in 68% (26/38). At follow-up MRI, performed in eight pregnancies, there were periventricular cysts and delayed sulcation with persistent oCSP in one case. Among the remaining cases with normal follow-up ultrasound and fetal MRI findings, the postnatal outcome was normal in 89% of cases (33/37) and abnormal in 11% (4/37): two with isolated speech delay, and two with neurodevelopmental delay secondary to postnatal diagnosis of Noonan syndrome at 5 years in one case and microcephaly with delayed cortical maturation at 5 months in the other.

**Conclusions:** Apparently isolated oCSP at mid-pregnancy is a transient finding with the visualization of the fluid later in pregnancy in up to 70% of cases. At referral, associated defects can be found in around 11% of cases at ultrasound and 8% at fetal

**Abbreviations:** CC, corpus callosum; CGH, comparative genomic hybridization; CNS, central nervous system; CSP, cavum septi pellucidi; oCSP, obliterated cavum septi pellucidi; SP, septum pellucidum.

This is an open access article under the terms of the [Creative Commons Attribution-NonCommercial-NoDerivs](https://creativecommons.org/licenses/by-nc-nd/4.0/) License, which permits use and distribution in any medium, provided the original work is properly cited, the use is non-commercial and no modifications or adaptations are made.

© 2023 The Authors. *Acta Obstetrica et Gynecologica Scandinavica* published by John Wiley & Sons Ltd on behalf of Nordic Federation of Societies of Obstetrics and Gynecology (NFOG).

MRI indicating the need for a detailed evaluation by expert physicians when oCSP is suspected.

#### KEYWORDS

cavum septi pellucidi, fetal brain, fetal magnetic resonance, neurosonography, postnatal neurodevelopmental outcome

## 1 | INTRODUCTION

The cavum septi pellucidi (CSP) is a midline structure of the fetal brain formed by fluid separating the two leaves of the septum pellucidum (SP), usually visible from 18 weeks until term gestation, that constitutes an important landmark in the evaluation of fetal brain anatomy.<sup>1-5</sup> Absence of the CSP and SP is typically associated with malformations such as agenesis of the corpus callosum (CC), holoprosencephaly and septo-optic dysplasia.<sup>6,7</sup> However, some studies, mainly case-series and case reports, reported on the presence of a different entity in which the CSP is present but appears obliterated: in this case, the two leaves of the septum pellucidum are seen but there is no recognizable anechoic fluid inside forming the cavum, resulting in an obliterated and hyperechoic aspect of the CSP.<sup>8-11</sup> The prognosis of the obliterated CSP (oCSP) associated with other central nervous system (CNS) abnormalities depends on the type of the defect found, however little is known regarding the significance and the management of oCSP with an otherwise normally developed brain structures, and this finding is not addressed by current guidelines.<sup>2,12</sup> Moreover, despite fetal magnetic resonance imaging (MRI) having been introduced as a complementary examination to ultrasound following the diagnosis of CNS defects, its clinical utility in case of oCSP has not been addressed.

The aim of this study was to describe the evolution of oCSP from the initial diagnosis at the anomaly scan to the third trimester, to evaluate the rate of additional anomalies, and to explore the clinical utility of performing the fetal MRI with oCSP.

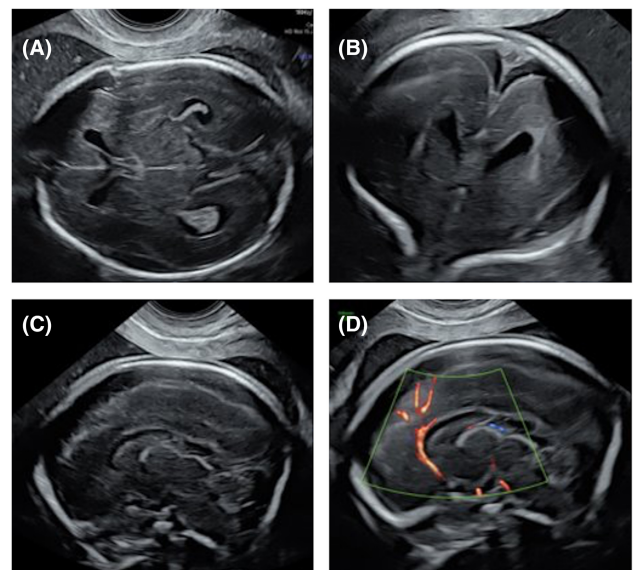
## 2 | MATERIAL AND METHODS

### 2.1 | Study design

This was a multicenter retrospective cohort study that involved five tertiary referral centers for prenatal diagnosis. The institutional imaging database was reviewed in order to identify all women with a diagnosis of oCSP following a referral for the suspicion of a CNS defect (either suspected oCSP or different indications) over a period of 5 years (from 2017 to 2021 inclusive). As part of standard protocol in case of suspected CNS anomaly, the examination included a detailed anomaly scan performed by experienced fetal medicine physicians: a multiplanar assessment of the fetal head in the axial, coronal and sagittal planes was used to visualize the midline

#### Key messages

An obliterated cavum septi pellucidi is a transitory finding in up to 70% of cases. Associated fetal brain defects are detected in 11% of cases at ultrasound and in 7.5% cases with magnetic resonance imaging. The neurodevelopmental outcome is overall good.



**FIGURE 1** Fetal ultrasound showing an obliterated cavum septi pellucidi (oCSP) in the axial (A), coronal (B) and sagittal (C) planes, with pericallosal artery in (D).

structures, lateral ventricles, CC, cerebellar body and vermis, third and fourth ventricles.<sup>1,2,12</sup> The transvaginal approach was chosen for the 2D/3D evaluation of the fetal brain in case of cephalic presentation, where transabdominal imaging provided inadequate assessment. The diagnosis of oCSP was made when the two leaves of the septum pellucidi were seen as a single non-disrupted line without an interposed anechoic cavity (Figure 1). An invasive test was offered and, if accepted, the genetic evaluation included QF-PCR, standard karyotype and comparative genomic hybridization (CGH) array analysis according to local protocols (array comparative genomic hybridization (a-CGH) or high-density single nucleotide polymorphism array (HD-SNP array) techniques).

The rationale of performing fetal MRI and its safety in pregnancy were explained to the couple. Fetal MRI was performed according to local protocols. The evaluation of the CSP was performed according to previous published studies.<sup>13,14</sup> Follow-up scans and fetal MRI were scheduled as per local protocols.

The third trimester fetal MRI was offered following the diagnosis of associated findings at ultrasound in some cases or as part of an internal protocol in others.

## 2.2 | Participants

Inclusion criteria were the following: diagnosis of oCSP either isolated or in association with other CNS and non-CNS defects; at least one fetal MRI evaluation; detailed anomaly scan performed by a specialist in fetal medicine; at least one follow-up scan and/or fetal MRI after 30 weeks' gestation. Exclusion criteria were the following: the performance of a single anomaly scan without fetal MRI; termination of pregnancy.

## 2.3 | Data collection

Prenatal and neonatal findings were recorded in protected databases. Postnatal telephone calls and reviewed of charts stored in electronic database were performed to evaluate long-term adverse outcomes, with a minimum follow-up of 1 year, which included genetic and neurological evaluations performed by a neurologist or developmental pediatrician where clinically indicated.

## 2.4 | Statistical analyses

A descriptive analysis was used to analyze the data by Microsoft Excel software (Microsoft Excel 2020, version 16.37). Variables are expressed as numbers and percentages or medians and interquartile ranges (IQR) as appropriate.

## 2.5 | Ethics statement

The study was approved by the Internal Review Board (RC 12/21) on January 14, 2021.

## 3 | RESULTS

A total number of 45 cases of oCSP were identified, of which one from a monochorionic/diamniotic pregnancy with both fetuses affected. The median maternal age was 33 years (IQR 29–36). The median gestational age at diagnosis was 20.5 weeks (IQR 20.1–21.1).

Indications for referral were abnormal appearance of the CSP in 60% (27/45); suspected oCSP in 11% (5/45); suspected CC agenesis

TABLE 1 Indications for referral.

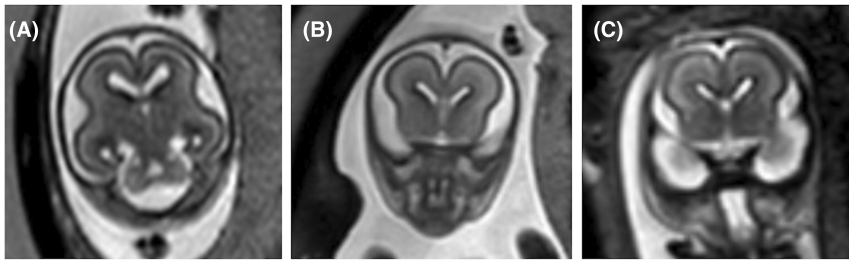Indication for referral	Number (%)
Abnormal appearance of CSP	27 (60)
Obliterated CSP	5 (11)
Agenesis of CC	3 (7)
Absent CSP	2 (4)
Others	8 (18)
Monochorionic/diamniotic pregnancy	2
High risk pregnancy	1
Lipoma of the CSP	1
Short long bones	1
HC <5th centile	1
NT 95–99th centile	1
Increased NF	1

Abbreviations: CSP, cavum septi pellucidi; HC, head circumference; NF, nuchal fold; NT, nuchal translucency.

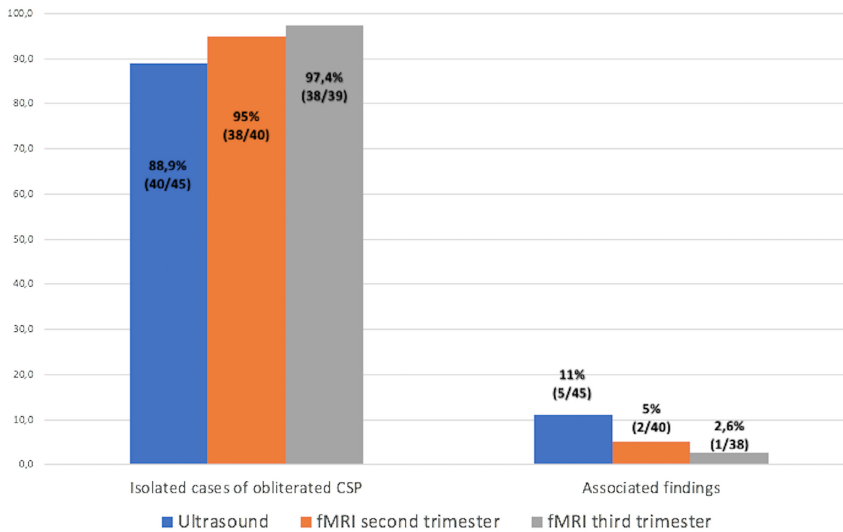
in 7% (3/45); absent CSP in 4% (2/45); and other indications in 18% (8/45) (Table 1).

A prenatal invasive diagnostic test was performed in 53% (24/45) of cases, four were chorionic villous sampling for maternal request (4/24; 17%) and 20 were amniocentesis (20/24; 83%) due to ultrasound findings (four cases of oCSP and associated CNS abnormalities and 10 cases for oCSP only). The analysis did not show any genetic abnormality at either standard karyotype and/or CGH array analysis conducted prenatally.

At neurosonography, oCSP was associated with other defects in 11% (5/45), of which one case of vermian hypoplasia, three cases of CC dysplasia, and one case of multiple abnormalities (hypoplastic CC, microcephaly and shortened long bones), all with an abnormal neurodevelopmental outcome postnatally. In the remaining 89% (40/45) of cases the oCSP was apparently isolated at ultrasound examination. Within this group, fetal MRI was performed at a median gestational age of 21 weeks (IQR 20.6–21.6) and confirmed the absence of associated anomalies in 95% (38/40). In the remaining two cases (2/40, 5%) fetal MRI detected the presence of polymicrogyria of the left parietal lobe in one and microcephaly, and microencephaly with prominent subarachnoid space in the other (initially referred for head circumference <5th percentile). Both cases had a poor postnatal outcome with neonatal death in the former and severe neurodevelopmental delay in the latter. Among the 38 fetuses with an apparently isolated oCSP at ultrasound, fetal MRI found a variable amount of fluid in the CSP in 74% (28/38) and no fluid in 26% (10/38) (Figure 2). Ultrasound follow-up at 30 weeks confirmed the diagnosis of oCSP in 32% (12/38) while some fluid was visible in 68% (26/38) of cases (Figure S1). A follow-up fetal MRI was performed in 21% of cases (8/38) at a median gestational age of 30 weeks (IQR 29.8–31.0). In two cases of the total cohort (2/38; 5%), the CSP had a cystic appearance with an otherwise normal CNS anatomy (Figure S2). Periventricular cysts and delayed sulcation with persistently oCSP



**FIGURE 2** Prenatal fetal magnetic resonance imaging (MRI) showing variable amount of fluid in the cavum septi pellucidi (coronal view): absent in (A); partially present in (B); normal in (C).



**FIGURE 3** Distribution of isolated and non-isolated cases of obliterated cavum septi pellucidi (oCSP) according to type of diagnostic investigations and gestational age.

were shown in one case of the total cohort (2.6%; 1/38), and the couple decided for termination of pregnancy (Figure 3).

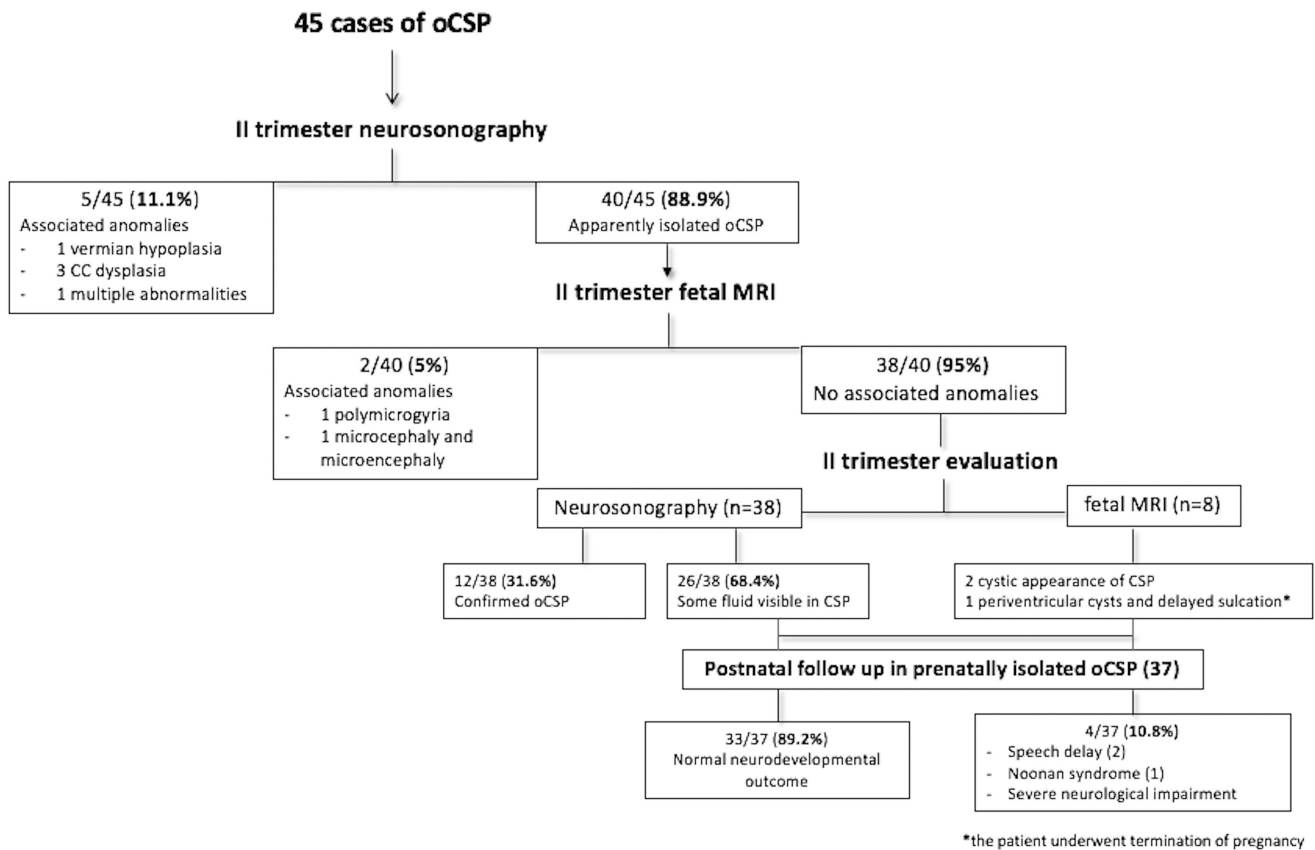
Regarding the postnatal outcome, among 37 cases with prenatally isolated oCSP a normal neurodevelopmental outcome was observed in 89% of cases (33/37) while an abnormal postnatal outcome was reported in 11% (4/37). Among these, in two cases there was a mild impairment as the children were followed-up for an isolated speech delay and an otherwise normal development (5%; 2/37). In two cases, more severe forms of neurodevelopmental delay were diagnosed (5%; 2/37) following the diagnosis of Noonan syndrome at 5 years in one, and microcephaly with dysgenesis of the CC and delayed myelination associated to major epilepsy and mild delay developed at 5 months after birth in the other. In this latter case the findings were confirmed at subsequent MRI and the exome sequencing analysis was requested and still ongoing. A flow-chart summarizing these findings is demonstrated in Figure 4.

## 4 | DISCUSSION

The results of this study show that the presence of an oCSP at the 20 weeks' scan may constitute a transient and benign finding, and variable amounts of fluid will be detected at subsequent scans or at fetal MRI in around 70% of cases. These findings are in contrast with the two seminal papers that first described the appearance and evolution of the CSP, reporting that it should always be visible between 17–20 and 37 weeks and for biparietal diameter of 44–88 mm.<sup>4,5</sup>

Since the first steps of neurosonography the visualization of the CSP has been a key landmark for the normal development of cerebral midline structures.<sup>15</sup> If initially it was defined as a rectangular-shaped anechoic structure, the introduction of high-resolution ultrasound machines and transvaginal probes allowed to recognize different patterns of its morphology, such as a triangular shaped or a double-line appearance, defining the most comprehensive area of the “anterior complex”.<sup>16–18</sup> Careful evaluation of this area can lead to the diagnosis of CNS defects, such as complete or partial agenesis of the CC among others.<sup>17,19,20</sup> Therefore, the anatomical criteria for the definition of a normal CSP have changed over time, also because of the higher spatial resolution of the new ultrasound probes.

The CSP is a cystic transitory structure typical of the mammalian brain and is a component of the limbic system.<sup>20,21</sup> Postnatally it becomes a virtual cavity and the prenatal meaning of the presence of fluid within it is not well understood, as it does not seem to communicate with the ventricular system, but probably results from the filtration of cerebrospinal fluid through the laminae of the SP.<sup>22,23</sup> The use of electron microscopy, performed on the brain of rodents, found that the walls of the CSP are not covered with ependymal cells but with amoeboid cells of the microglia, also present in the CC.<sup>20</sup> These cells, resulting from the migration of callosal microglia or from extravasation and differentiation of monocytes present in the neighboring blood vessels, seem to play an active role within the CSP, contributing to a process of clearance of the nervous system in progress. In particular, they seem to play a role in removing cellular debris and degenerating axons.<sup>20</sup> Therefore, the prenatal presence



**FIGURE 4** Flow-chart showing the findings of prenatal outcome and evolution of the obliterated cavum septi pellucidi (oCSP) and the postnatal outcomes.

of fluid in the CSP may represent the active role of this structure in the process of fetal brain remodeling and maturation. From an embryological point of view, the CSP is strictly related to the development of the CC. Different theories postulate that the CSP is a pocket resulting from the fusion of interhemispheric vesicles within the commissural plate that is later closed and stretched by the CC, assuming its characteristic shape.<sup>24,25</sup> Therefore, CSP anomalies are a major flag for CC defects.

The presence of an oCSP with an otherwise normal CC has been firstly reported by Malinger et al. and subsequently others.<sup>8-11</sup> According to Malinger,<sup>8</sup> an oCSP might have resulted from a delay in cavitation or formation rather than in an early obliteration with subsequent remodeling. This is in line with our findings since in over half of cases variable amount of fluid will appear later in gestation supporting the hypothesis of a delay in the cavitation process. However, the question that needs to be answered is in what proportion of cases oCSP is the sign of abnormal development of the fetal brain.

Based on our series, a detailed ultrasound evaluation will diagnose the presence of associated CNS anomalies in 11% of cases and fetal MRI will reveal anomalies in 7%–8% of the remaining, of which two thirds in the second trimester and one third in the third trimester. In our experience, the overall rate of associated findings diagnosed at ultrasound and/or fetal MRI in fetuses with oCSP throughout gestation is 19%. To date, only one case series of 23

fetuses described associated findings and postnatal outcome of oCSP: the rate of associated defects was 26% while the rate of adverse postnatal neurodevelopmental outcome for the isolated forms was 6%.<sup>8</sup> These findings are in line with our results and prove that the presence of an oCSP at the mid-trimester scan is an indication for referring the patient to a center with expertise in fetal neurosonography. The question whether there is an indication for fetal MRI is still debatable. According to the latest guidelines on neurosonography, oCSP is not a clear indication for fetal MRI.<sup>12</sup> Conversely, our data support the role of fetal MRI since that in these cases the overall diagnostic yield (8%) is comparable to that reported for other defects which constitute an indication for fetal MRI, for example, mild ventriculomegaly.<sup>26,27</sup>

One aspect that remains controversial is the risk of postnatal neurodevelopmental delay. The CSP is part of the limbic system and works as an important relay station for the hippocampal fibers. Since its obliteration is a physiological process in the neonatal brain, there are some reports regarding a postnatal persistent CSP with neurological and behavioral problems such as schizophrenia and psychopathic traits.<sup>28</sup> In our case series, the rate of abnormal neurodevelopmental outcome at referral can be estimated to be 10%, half of which in the spectrum of severe neurodevelopmental delay, a figure comparable to the 6% reported by Malinger et al.<sup>8</sup> However, the number of cases in both series is relatively small and the postnatal



neurodevelopmental assessment was not standardized among all centers, calling the need for prospective study to confirm these data.

The major strength of this study is that all cases underwent fetal neurosonography performed by experienced fetal medicine physicians, follow-up scans and at least one fetal MRI in order to describe the evolution of oCSP appearance through gestation and the rate of associated findings. Moreover, a postnatal follow-up to at least 1 year was available. Besides the small study sample, this cohort represents the largest reported series of oCSP. The retrospective nature of the study and the absence of a standardized protocol for fetal MRI and postnatal follow-up may have hindered a proper evaluation of associated findings. Thus, prospective studies should be encouraged.

## 5 | CONCLUSION

The diagnosis of oCSP at the mid-trimester scan may be a transient finding in more than two-thirds of cases, with variable amounts of fluid detectable later in gestation. A thorough assessment of fetal cerebral anatomy will find associated defects in 11% of cases at ultrasound and in 8% of cases at fetal MRI, in either the second or third trimester. In isolated cases, the neurodevelopmental outcome is overall good with a risk of abnormal neurodevelopmental outcome of around 10%, with a 5% incidence of severe neurodevelopmental delay.

### AUTHOR CONTRIBUTIONS

IF and TS have made a substantial contribution to the concept and design of the study; CC, EF, OMQ, AS, KP, MB, EF and FP collected the data; IF and GZ analyzed the data; IF and TSa wrote the manuscript; GB, CL, FMM, GP and BT contributed to the scientific contents and revised the manuscript.

### FUNDING INFORMATION

This work was supported by the Italian Ministry of Health, through the contribution given to the Institute for Maternal and Child Health IRCCS Burlo Garofolo, Trieste, Italy (RC 12/21).

### CONFLICT OF INTEREST STATEMENT

None.

### ORCID

Ilaria Fantasia  <https://orcid.org/0000-0003-4340-7225>

Christoph Lees  <https://orcid.org/0000-0002-2104-5561>

Federico Prefumo  <https://orcid.org/0000-0001-7793-714X>

Tamara Stampalija  <https://orcid.org/0000-0002-9080-3848>

### REFERENCES

- Malinger G, Paladini D, Haratz KK, Monteagudo A, Pilu GL, Timor-Tritsch IE. ISUOG practice guidelines (updated): sonographic examination of the fetal central nervous system. Part 1: performance of screening examination and indications for targeted neurosonography. *Ultrasound Obstet Gynecol.* 2020;56:476-484.
- Society for Maternal-Fetal Medicine (SMFM), Ward A, Monteagudo A. Absent Cavum Septi Pellucidi. *Am J Obstet Gynecol.* 2020;223:23-26.
- Salomon LJ, Alfirevic Z, Berghella V, et al. ISUOG practice guidelines (updated): performance of the routine mid-trimester fetal ultrasound scan. *Ultrasound Obstet Gynecol.* 2022;59:840-856.
- Jou HJ, Shyu MK, Wu SC, Chen SM, Su CH, Hsieh FJ. Ultrasound measurement of the fetal cavum septi pellucidi. *Ultrasound Obstet Gynecol.* 1998;12:419-421.
- Falco P, Gabrielli S, Visentin A, Perolo A, Pilu G, Bovicelli L. Transabdominal sonography of the cavum septum pellucidum in normal fetuses in the second and third trimesters of pregnancy. *Ultrasound Obstet Gynecol.* 2000;16:549-553.
- Santo S, D'Antonio F, Homfray T, et al. Counseling in fetal medicine: agenesis of the corpus callosum. *Ultrasound Obstet Gynecol.* 2012;40:513-521.
- Shinar S, Blaser S, Chitayat D, et al. Long-term postnatal outcome of fetuses with prenatally suspected septo-optic dysplasia. *Ultrasound Obstet Gynecol.* 2020;56:371-377.
- Malinger G, Lev D, Oren M, Lerman-Sagie T. Non-visualization of the cavum septi pellucidi is not synonymous with agenesis of the corpus callosum. *Ultrasound Obstet Gynecol.* 2012;40:165-170.
- Pugash D, Langlois S, Power P, Demos M. Absent cavum with intact septum pellucidum and corpus callosum may indicate midline brain abnormalities. *Ultrasound Obstet Gynecol.* 2013;41:343-344.
- Zorila GL, Tudorache S, Barbu EM, et al. Outcome of fetuses with abnormal cavum septi pellucidi: experience of a tertiary center. *J Clin Gynecol Obstet.* 2016;5:112-116.
- Stanislavsky A, Goergen S. Echogenic cavum septi pellucidi is associated with mild callosal dysgenesis on postnatal MRI. *Australas J Ultrasound Med.* 2019;28(2):214-216.
- Paladini D, Malinger G, Birnbaum R, et al. ISUOG practice guidelines (updated): sonographic examination of the fetal central nervous system. Part 2: performance of targeted neurosonography. *Ultrasound Obstet Gynecol.* 2021;57:661-671.
- Prayer D, Malinger G, Brugger PC, et al. ISUOG practice guidelines: performance of fetal magnetic resonance imaging. *Ultrasound Obstet Gynecol.* 2017;49:671-680.
- Griffiths PD, Jarvis D. Analysis of 270 fetuses with non-visualization of cavum septi pellucidi and vergae on in-utero magnetic resonance imaging. *Ultrasound Obstet Gynecol.* 2020;56:732-739.
- Sonographic examination of the fetal central nervous system: Guidelines for performing the 'basic examination' and the 'fetal neurosonogram'. *Ultrasound Obstet Gynecol.* 2007;29:109-116.
- Cagneaux M, Guibaud L. From cavum septi pellucidi to anterior complex: how to improve detection of midline cerebral abnormalities. *Ultrasound Obstet Gynecol.* 2013;42:485-486.
- Viñals F, Correa F, Gonçalves-Pereira PM. Anterior and posterior complexes: a step towards improving neurosonographic screening of midline and cortical anomalies. *Ultrasound Obstet Gynecol.* 2015;46:585-594.
- Green S, Pretorius DH, Crouch A, et al. What are the double lines of the fetal cavum Septi Pellucidi on ultrasound? *J Ultrasound Med.* 2022;41:1907-1914.
- Shen O, Gelot AB, Moutard ML, Jouannic JM, Sela HY, Garel C. Abnormal shape of the cavum septi pellucidi: an indirect sign of partial agenesis of the corpus callosum. *Ultrasound Obstet Gynecol.* 2015;46:595-599.
- Kaur C, Ling EA. Transitory cystic cavities in the developing mammalian brain—normal or anomalous? *J Anat.* 2017;230:197-202.
- Barkovich AJ, Norman D. Absence of the septum pellucidum: a useful sign in the diagnosis of congenital brain malformations. *Am J Roentgenol.* 1989;152:353-360.
- Li ST, Chiu NC, Hsu CH, Chiang MF. Empyema of the cavum septum pellucidum. *Pediatr Neurol.* 2002;26:391-393.

23. Oteruelo FT. On the cavum septi pellucidi and the cavum Vergae. *Anat Anz.* 1986;162:271-278.
24. Rakic P, Yakovlev P. Development of the corpus callosum and cavum septi pellucidi in man. *J Comp Neurol.* 1968;132:45-72.
25. Raybaud C. The corpus callosum, the other great forebrain commissures, and the septum pellucidum: anatomy, development, and malformation. *Neuroradiology.* 2010;52:447-477.
26. ENSO Working Group. Role of prenatal magnetic resonance imaging in fetuses with isolated mild or moderate ventriculomegaly in the era of neurosonography: international multicenter study. *Ultrasound Obstet Gynecol.* 2020;56:340-347.
27. Fantasia I, Bussani R, Gregori M, et al. Intrauterine versus post-mortem magnetic resonance in second trimester termination of pregnancy for central nervous system abnormalities. *Eur J Obstet Gynecol Reprod Biol.* 2020;250:31-35.
28. Crooks D, Anderson NE, Widdows M, et al. The relationship between cavum septum pellucidum and psychopathic traits in female offenders. *Behav Brain Res.* 2019;359:967-972.

## SUPPORTING INFORMATION

Additional supporting information can be found online in the Supporting Information section at the end of this article.

**How to cite this article:** Fantasia I, Ciardo C, Bracalente G, et al. Obliterated cavum septi pellucidi: Clinical significance and role of fetal magnetic resonance. *Acta Obstet Gynecol Scand.* 2023;00:1-7. doi:[10.1111/aogs.14575](https://doi.org/10.1111/aogs.14575)