

COVID-19 AdenoviralVector Vaccine and Central Retinal Vein Occlusion

Davide Romano, Francesco Morescalchi, Vito Romano & Francesco Semeraro

To cite this article: Davide Romano, Francesco Morescalchi, Vito Romano & Francesco Semeraro (2022): COVID-19 AdenoviralVector Vaccine and Central Retinal Vein Occlusion, Ocular Immunology and Inflammation, DOI: [10.1080/09273948.2022.2079534](https://doi.org/10.1080/09273948.2022.2079534)

To link to this article: <https://doi.org/10.1080/09273948.2022.2079534>



Published online: 02 Jun 2022.



Submit your article to this journal [↗](#)



View related articles [↗](#)



View Crossmark data [↗](#)

COVID-19 Adenoviral Vector Vaccine and Central Retinal Vein Occlusion

Davide Romano, MD, Francesco Morescalchi, MD, Vito Romano, MD, and Francesco Semeraro, MD

Eye Clinic, Department of Medical and Surgical Specialties, Radiological Sciences and Public Health, University of Brescia, Brescia, Italy

ABSTRACT

Purpose: The purpose of this article is to report a case of sudden onset ischemic retinal central vein occlusion after a second dose of COVID-19 adenoviral vector vaccine.

Case report/observations: A 54-year-old woman with systemic arterial hypertension developed ischemic central retinal vein occlusion in her right eye on day 2 after the second dose of COVID-19 adenoviral vector vaccine ChAdOx1 nCoV-19/ AZD1222, Oxford-AstraZeneca.

Conclusion: Adenoviral vector vaccine promotes both cellular and humoral immune responses, increasing the level of inflammatory cytokines. These cytokines are the same implied in the possible pathogenesis of central retinal vein occlusion. Subsequently, we recommend informing patients at risk of possible ocular adverse events, which require urgent evaluation.

ARTICLE HISTORY

Received 16 December 2021

Revised 06 May 2022

Accepted 13 May 2022

KEYWORDS

Central retinal vein occlusion; COVID-19; COVID-19 vaccine; CRVO; retina

Dear Editor,

COVID-19 vaccines have unquestionably represented the turning point of the pandemic, with excellent short-term efficacy and a solid safety profile.¹ However, rare and severe systemic adverse events have been reported in the literature, with possible inflammatory and/or immune mechanisms, particularly after AstraZeneca vaccine, such as the vaccine-induced immune thrombotic thrombocytopenia (VITT).²

The relationship between COVID-19 vaccines and ocular adverse events is still limited, but growing, in view of the ongoing increased number of vaccine doses administered.³

To date, only five cases are reported in the literature of central retinal vein occlusion (CRVO) and one case of branch retinal vein occlusion (BRVO), possible associated with mRNA vaccine (Pfizer-BioNTech) and adenoviral vector vaccine (Gam-COVID-Vac/Sputnik V, and AZD1222/Covishield).⁴⁻⁸

We report a middle-aged woman, presenting with a typical acute pattern of sudden onset ischemic CRVO on day 2 after her second dose of adenoviral vector vaccine (Oxford-AstraZeneca). Our case differs from the other case reports in onset and type of vaccine received.

A 54-year-old woman presented with a 15-day history of unilateral, painless loss of vision in her right eye (RE). This symptom had started suddenly 2 days after her second dose of COVID-19 adenoviral vector vaccine (ChAdOx1 nCoV-19/ AZD1222, Oxford-AstraZeneca), while the first dose of the same type of vaccine was administered 3 months earlier.

Her past medical history was positive only for arterial hypertension, for which she was on furosemide 25 mg once daily. At the time of the episode, her blood pressure was well controlled by her therapy, and it was within the normal values, with a BP of 121/83 mmHg.

On examination, the best-corrected visual acuity (BCVA) was 20/400 in the RE and 20/20 in the left eye (LE), while the intraocular pressure was 12 mmHg in RE and 10 mmHg in LE.

The slit lamp examination was positive for mild RAPD in RE, with slow constriction of the pupil, compared with the LE. Other anterior segment findings were unremarkable in both eyes.

The fundus examination was suggestive in her RE for CRVO, with optic disc swelling, retinal hemorrhages in all the retinal quadrants, dilated and tortuous retinal veins and alteration of macular reflex (Figure 1). The LE fundus was positive for stage 2 hypertensive retinopathy, with narrower retinal arteries and arterio-venous crossing, and no other abnormalities were present.

Subsequently, fundus retinography, fluorescein angiography (FA) and OCT were performed, using the scanning laser ophthalmoscope (HRA2; Heidelberg Engineering, Heidelberg, Germany).

Fluorescein was injected in the right arm vein, and the first eye examined was the right.

RE FA findings were compatible with ischemic CRVO: delay in arteriovenous transit time, staining of vein vessels wall, retinal hemorrhages, and diffuse peripheral retinal areas of ischemia.

The OCT revealed thickening of the retina, with diffuse macular oedema and foveal subretinal fluid (Figure 2). FA and OCT of LE were unremarkable, apart from stage 2 hypertensive retinopathy.

In addition, blood diagnostic tests, inflammatory tests and cardiovascular tests were requested to better determine the presence of any other risk factors. The results were within the normal values (platelet count was 328,000 cells per microliter; prothrombin time was 11.6 seconds; prothrombin activity was

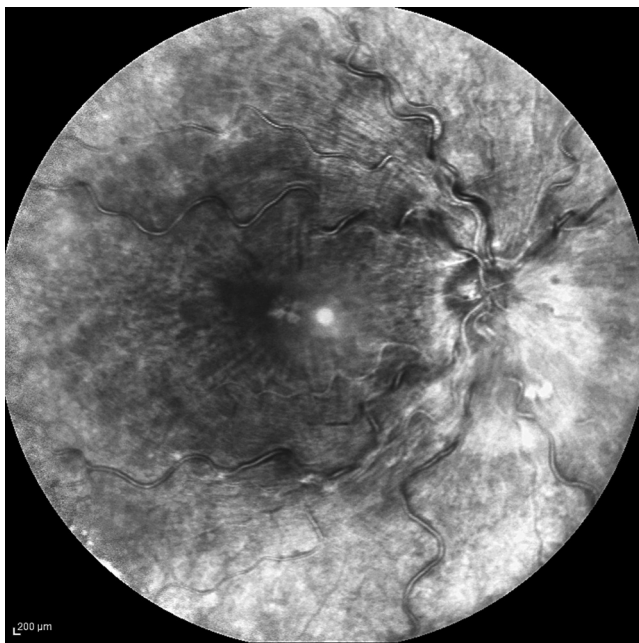


Figure 1. Right eye infrared image of the fundus.

98%; international normalized ratio was 0.99; antithrombin III and factor V activities were 100% and 154%, respectively); in addition no abnormalities were detected on electrocardiogram, doppler echocardiography and bilateral carotid doppler ultrasonography.

In view of the eye examination, a diagnosis of ischemic CRVO was made and the patient was listed for RE 0.7 mg dexamethasone intravitreal implant (Ozurdex, Allergan, Inc., Irvine, USA) and argon laser pan retinal photocoagulation (PRP).

Despite the absence of iris neovascularization (NVI) or neovascularization of angle (NVA), the decision to perform the PRP was based on the type of CRVO, which was ischemic, and by the total area of retinal non-perfusion, greater than 10-disc area, to reduce the risk of NVI.⁹

At follow-up, the macular edema in RE was reduced (Figure 3) and the BCVA improved to 20/200.

The exact pathogenesis of CRVO is not known; however, a major role in its etiology seems to be played by systemic and local inflammation.¹⁰ Considering whether vaccinations may promote an inflammation status and have a role in triggering the CRVO in the receiving host, it is known that increased levels of inflammatory cytokines with subsequent local and systemic manifestations are normally reported after vaccine administration, as a normal consequence of the host immune response, cellular and humoral.¹¹ COVID-19 vaccines, regardless of the type of vaccine (mRNA or adenoviral vector vaccine), are not exempt from promoting this inflammatory status.¹²

With mRNA vaccines, the humoral immune response is better recognised, whereas the cellular immune response is less well characterized. Instead, evidence suggests that adenoviral vector vaccines stimulate both responses.¹²

Between the two types of response, cellular and humoral immune, it is the cellular which is more associated with systemic inflammation, stimulating the release of chemokines and cytokines including interferon γ and λ , tumor necrosis factor (TNF)- α , interleukin-12 (IL-12), interleukin-8 (IL-8), and interleukin-6 (IL-6).^{11,13} These cytokines are among those that have been hypothesized to promote or trigger retinal vein occlusion.¹⁰ This could explain why cases of CRVO post adenoviral vector vaccine are higher than with the mRNA vaccine.¹⁰

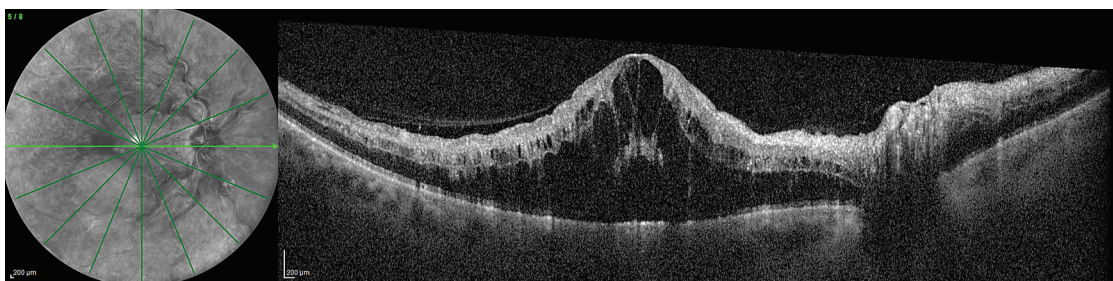


Figure 2. Right eye macular OCT with diffuse oedema and foveal subretinal fluid.

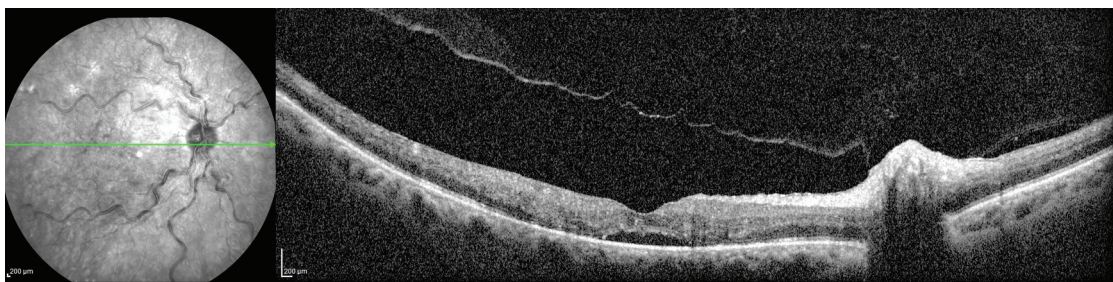


Figure 3. Right eye macular OCT at 4 weeks after the dexamethasone intravitreal implant.

Reviewing our case and the literature, it is interesting to note that in six of the seven cases, the onset of CRVO and BRVO after COVID-19 vaccines has occurred following the second dose, which can suggest a few things. First, CRVO and BRVO may not be a manifestation of VITT. VITT has been reported to occur after the first dose rather than the second, along with thrombocytopenia and alteration of haemostatis.² In our case, the event occurred after the second dose, and the platelet count was within the normal value, with no abnormalities in blood sample laboratory tests. Secondly, the inflammatory response in the host generated by vaccines is generally stronger in cases of multiple administrations, possibly due to related pre-existing immunity.¹⁴ Subsequently, it is possible to speculate that inflammatory cytokines may act as triggering factors at two levels, on the preexisting inflammatory status of a patient at risk, as was seen in our patient, considering her positivity for systemic arterial hypertension and stage 2 hypertensive retinopathy in the left eye,^{15,16} and/or extending pathological damage initiated by immune/coagulation cascade post first dose.¹⁷

In conclusion, we are conscious that defining a sure causal relationship between the second dose of vaccine Oxford-AstraZeneca COVID-19 vaccine and disease is not feasible, but we suggest to be aware of patients potentially at risk, focusing on their medical and therapy history.

Planning an ophthalmological evaluation before vaccine administration is not feasible, due to time and cost required. A positive history of systemic hypertension would not be diriment to choose if a patient is fit or not for adenoviral vector vaccines or mRNA vaccines, in view of the very few cases reported in the literature of CRVO and BRVO possibly vaccine related. Our advice is instead to inform patients of possible ocular adverse events, which require urgent evaluation and to not wait if they occur, as the patient did in our case.

This recommendation may be useful not only as the third doses of COVID-19 vaccines are being administered in many countries but also those countries in which the rate of vaccination is still low and the use of adenoviral vector vaccine may be preferred, in view of no strict requirement of their storage, compared to mRNA vaccines.

Disclosure statement

No potential conflict of interest was reported by the author(s).

Funding

The author(s) reported there is no funding associated with the work featured in this article.

Informed Consent

Written informed consent for publication of this case report was obtained from the patient.

Contributors

Authors contributed to the writing of the article DR, FM, VR, FS. DR and VR were responsible for conception of the article content, intellectual content and drafting of the manuscript. FM, FS, and VR contributed to revision of the initial draft. VR and FM contributed to preparation of the final manuscript. DR participated in data collection. DR was involved with the patient's care. All authors read and approved the final manuscript.

References

- Pormohammad A, Zarei M, Ghorbani S, et al. Efficacy and safety of COVID-19 vaccines: a systematic review and meta-analysis of randomized clinical trials. *Vaccines (Basel)*. 2021. 9(5):467. doi:10.3390/vaccines9050467.
- Greinacher A, Thiele T, Warkentin TE, Weisser K, Kyrle PA, Eichinger S. Thrombotic thrombocytopenia after ChAdOx1 nCov-19 vaccination. *N Engl J Med*. 2021;384(22):2092–2101. doi:10.1056/NEJMoa2104840.
- le Ng X, Betzler BK, Testi I, et al. Ocular adverse events after COVID-19 vaccination. *Ocul Immunol Inflamm*. 2021. doi:10.1080/09273948.2021.1976221.
- Endo B, Bahamon S, Martínez-Pulgarín D. Central retinal vein occlusion after mRNA SARS-CoV-2 vaccination: a case report. *Indian J Ophthalmol*. 2021;69(10):2865. doi:10.4103/ijo.IJO_1477_21.
- Bialasiewicz AA, Farah-Diab MS, Mebarki HT. Central retinal vein occlusion occurring immediately after 2nd dose of mRNA SARS-CoV-2 vaccine. *Int Ophthalmol*. 2021;41(12):3889–3892. doi:10.1007/S10792-021-01971-2/FIGURES/2.
- Goyal M, Murthy S, Srinivas Y. Unilateral retinal vein occlusion in a young, healthy male following Sputnik V vaccination. *Indian J Ophthalmol*. 2021;69(12):3793. doi:10.4103/ijo.IJO_2412_21.
- Sonawane N, Yadav D, Kota A, Singh H. Central retinal vein occlusion post-COVID-19 vaccination. *Indian J Ophthalmol*. 2022;70(1):308. doi:10.4103/ijo.IJO_1757_21.
- Sugihara K, Kono M, Tanito M. Branch retinal vein occlusion after messenger RNA-Based COVID-19 vaccine. *Case Rep Ophthalmol*. 2022;13(1):28–32. doi:10.1159/000521838.
- Li C, Wang R, Liu G, et al. Efficacy of panretinal laser in ischemic central retinal vein occlusion: a systematic review. *Exp Ther Med*. November 29, 2018. Published online. doi:10.3892/etm.2018.7034.
- Deobhakta A, Chang LK. Inflammation in retinal vein occlusion. *Int J Inflammation*. 2013;2013. doi:10.1155/2013/438412.
- Commins SP, Borish L, Steinke JW. Immunologic messenger molecules: cytokines, interferons, and chemokines. *J Allergy Clin Immunol*. 2010;125(2):2. doi:10.1016/j.jaci.2009.07.008.
- Teijaro JR, Farber DL. COVID-19 vaccines: modes of immune activation and future challenges. *Nat Rev Immunol*. 2021;21(4):195–197. doi:10.1038/s41577-021-00526-x.
- Mendonça SA, Lorincz R, Boucher P, Curiel DT. Adenoviral vector vaccine platforms in the SARS-CoV-2 pandemic. *Npj Vaccines*. 2021;6(1):1. doi:10.1038/s41541-021-00356-x.
- Hervé C, Laupèze B, Del Giudice G, Didierlaurent AM, da Silva FT. The how's and what's of vaccine reactogenicity. *Npj Vaccines*. 2019;4(1):1. doi:10.1038/s41541-019-0132-6.
- Stem MS, Talwar N, Comer GM, Stein JD. A longitudinal analysis of risk factors associated with central retinal vein occlusion. *Ophthalmology*. 2013;120(2):362–370. doi:10.1016/j.ophtha.2012.07.080.
- de Miguel C, Rudemiller NP, Abais JM, Mattson DL. Inflammation and hypertension: new understandings and potential therapeutic targets. *Curr Hypertens Rep*. 2015;17(1):507. doi:10.1007/s11906-014-0507-z.
- Kircheis R. Coagulopathies after vaccination against SARS-CoV-2 may be derived from a combined effect of SARS-CoV-2 spike protein and adenovirus vector-triggered signaling pathways. *Int J Mol Sci*. 2021;22(19):10791. doi:10.3390/ijms221910791.