

~0.1% sodium hypochlorite can be made by a roughly 1:50 dilution of household bleach (~5.25% to 6% sodium hypochlorite) in tap water. Although the Kampf et al analysis is a combination of non-COVID-19 studies, we expect the proposed formulation to similarly also disinfect surfaces of the novel coronavirus. The Centers for Disease Control and Prevention (CDC) also recommends an approximately 1:50 dilution to disinfect COVID-19, explicitly noting 5 tablespoons (one-third cup) bleach per gallon of water or 4 teaspoons bleach per quart of water.⁴

Different dilutions of sodium hypochlorite can vary in their in vivo fibroblast and keratinocyte cytotoxicity; however, dilutions of ~0.1% sodium hypochlorite are clinically effective with minimal irritation or sensitization.⁵ One should be mindful that corrosive injury on mucous membrane/skin contact is possible with excess volumes or mishandling, so appropriate caution and moderation is necessary.⁶ This solution should ideally be used within 1 month of preparation and stored in a closed, opaque container at room temperature.⁷

While the exact viral load on inanimate surfaces is unknown during an outbreak, it is critical to disinfect frequently touched surfaces.¹ With rapidly diminishing availability of commercial cleaning supplies, simple diluted bleach, which is readily available, can effectively disinfect our clinics, homes, and environment to prevent sustained transmission from inanimate objects. As with many disinfectants, minimizing long-term skin contact and ensuring good ventilation can minimize clinical toxicity. In Henry Dakin's spirit, we should strive to share with our colleagues the cost-effective, accessible, and relatively safe power of diluted bleach.

Parth Patel, MD,^a Sanjna Sanghvi, BS,^b Kunal Malik, MD,^c and Amor Khachemoune, MD^{d,e}

From the Division of Dermatology, Department of Medicine, Montefiore Medical Center, Albert Einstein College of Medicine, Bronx, New York^a; the New York College of Podiatric Medicine, New York, New York^b; the Department of Dermatology, Icahn School of Medicine at Mount Sinai, New York, New York^c; the Veterans Affairs Medical Center, Brooklyn, New York^d; and the Department of Dermatology, State University of New York Downstate, Brooklyn, New York.^e

Funding sources: None.

Conflicts of interest: None disclosed.

IRB approval status: Not applicable.

Correspondence to: Amor Khachemoune, MD, Veterans Affairs Hospital and SUNY Downstate, Dermatology Service, 800 Poly Pl, Brooklyn, NY 11209

E-mail: amorkb@gmail.com

REFERENCES

1. Kampf G, Todt D, Pfaender S, Steinmann E. Persistence of coronaviruses on inanimate surfaces and their inactivation with biocidal agents. *J Hosp Infect.* 2020;104:246-251.
2. van Doremalen N, Bushmaker T, Morris DH, et al. Aerosol and surface stability of SARS-CoV-2 as compared with SARS-CoV-1. *N Engl J Med.* 2020.
3. United States Environmental Protection Agency. Pesticide Registration. List N: disinfectants for Use Against SARS-CoV-2. Available at: <https://www.epa.gov/pesticide-registration/list-n-disinfectants-use-against-sars-cov-2>; 2020. Accessed March 20, 2020.
4. Centers for Disease Control and Prevention. Clean & Disinfect-Coronavirus Disease 2019: interim Recommendations for U.S. Households with Suspected or Confirmed Coronavirus Disease 2019 (COVID-19). March 2020. Available at: <https://www.cdc.gov/coronavirus/2019-ncov/prepare/cleaning-disinfection.html>. Accessed March 20, 2020.
5. Ronco C, Mishkin GJ. *Disinfection by Sodium Hypochlorite: Dialysis Applications.* Basel, Switzerland: Karger; 2007.
6. Slaughter RJ, Watts M, Vale JA, Grieve JR, Schep LJ. The clinical toxicology of sodium hypochlorite. *Clin Toxicol (Phila).* 2019; 57:303-311.
7. National Research Council (US) and Institute of Medicine (US). Panel on Needle Exchange and Bleach Distribution Programs. In: Normand J, Vlahov D, Moses LE, eds. *Preventing HIV Transmission: The Role of Sterile Needles and Bleach.* Washington, DC: National Academies Press (US); 1995.

<https://doi.org/10.1016/j.jaad.2020.04.033>

Varicella-like exanthem as a specific COVID-19-associated skin manifestation: Multicenter case series of 22 patients



To the Editor: COVID-19, an infection due to the severe acute respiratory syndrome coronavirus 2 (SARS-CoV-2) that may cause interstitial pneumonia and respiratory failure, has currently taken on pandemic proportions.¹ The COVID-19 outbreak emerged in Wuhan, China, and rapidly spread to Europe, particularly to Italy,² where, as of April 27, 2020, a total of 199,414 people have tested positive.³

Two recent publications have brought attention to COVID-19-associated cutaneous manifestations.^{4,5} Joob and Wiwanitkit⁴ reported on a dengue-like petechial rash in a patient with COVID-19 from Thailand. Recalcati⁵ described 18 out of 88 patients with COVID-19 hospitalized in Lecco Hospital (Lombardy region, Italy) who developed erythematous rash (n = 14), widespread urticaria (n = 3), or varicella-like vesicles (n = 1).

Table I. Demographic and clinical data of patients with varicella-like exanthem associated with COVID-19

ID	Sex	Age, years	Hometown	Systemic symptoms' onset	Positive result on nasopharyngeal swab	Skin lesions	Skin symptoms	Latency time, days	Duration, days	Localization	Systemic symptoms	Negative result on nasopharyngeal swab	Course
1	M	75	Rome	February 19, 2020	March 4, 2020	Diffuse papulovesicular lesions (predominance of papules)	No itching	12	5	Trunk	Fever, asthenia, hypogeusia, hyposmia	Yes	Resolution
2	M	57	Milan	February 20, 2020	February 22, 2020	Diffuse papulovesicular lesions (predominance of vesicles)	Mild itching	5	4	Trunk	Fever, cough, coryza, headache, hyposmia, hypogeusia, weakness	Yes	Resolution
3	M	59	Milan	February 28, 2020	March 2, 2020	Scattered papulovesicular lesions (predominance of papules)	Mild itching	7	15	Trunk	Fever, cough, pharyngodynia, headache, weakness	Yes	Resolution
4	F	56	Brescia	February 28, 2020	March 2, 2020	Scattered papulovesicular lesions (predominance of vesicles)	Pain	3	15	Trunk	Fever, cough, coryza, headache, weakness	Yes	Resolution
5	M	28	Bologna	March 1, 2020	March 10, 2020	Diffuse papulovesicular lesions started (predominance of papules)	Itching	4	7	Trunk	Fever, cough	Yes	Resolution
6	M	45	Biella	March 1, 2020	March 6, 2020	Scattered papulovesicular lesions (predominance of papules)	No itching	6	10	Trunk	Fever, diarrhea, nausea	Yes	Resolution
7	M	72	Brescia	March 1, 2020	March 14, 2020	Scattered papulovesicular lesions (predominance of vesicles)	No itching	Unknown	NA	Trunk, limbs	Fever, cough, coryza, headache, dyspnea	No	Active disease

Continued

Table I. Cont'd

ID	Sex	Age, years	Hometown	Systemic symptoms' onset	Positive result on nasopharyngeal swab	Skin lesions	Skin symptoms	Latency time, days	Duration, days	Localization	Systemic symptoms	Negative result on nasopharyngeal swab	Course
8	M	83	Cremona	March 2, 2020	March 10, 2020	Scattered papulovesicular lesions (predominance of vesicles)	No itching	2	5	Trunk	Fever, dyspnea	No	Active disease*
9	M	61	Milan	March 2, 2020	March 5, 2020	Diffuse papulovesicular lesions (predominance of vesicles)	Mild itching	2	4	Trunk	Fever, cough, dyspnea, coryza, headache, weakness	//	Death
10	M	29	Brescia	March 3, 2020	March 10, 2020	Scattered papulovesicular lesions (predominance of vesicles)	Mild itching	1	12	Trunk	Fever, cough, weakness	Yes	Resolution
11	M	65	Brescia	March 3, 2020	March 16, 2020	Scattered papulovesicular lesions (predominance of papules)	Burning	2	13	Trunk	Fever, cough, dyspnea, coryza, headache, weakness	No	Active disease
12	M	44	Brescia	March 8, 2020	March 16, 2020	Scattered papulovesicular lesions (predominance of vesicles)	Burning, itching	3	8	Trunk	Fever, cough, coryza, headache, weakness	No	Resolution
13	M	75	Cremona	March 8, 2020	March 16, 2020	Scattered vesicular lesions (predominance of vesicles)	No itching	0	8	Trunk, limbs	Fever, dyspnea	//	Death
14	F	51	Brescia	March 8, 2020	March 17, 2020	Scattered papulovesicular lesions (predominance of vesicles)	Pain	4	8	Trunk	Fever, cough, dyspnea, coryza, headache, weakness	No	Active disease
15	F	62	Brescia	March 9, 2020	March 18, 2020	Scattered papulovesicular lesions (predominance of papules)	Burning	2	11	Trunk	Fever, cough, coryza, headache, weakness	No	Improvement

16	M	25	Siena	March 10, 2020	March 17, 2020	Diffuse papulovesicular lesions (predominance of vesicles)	Itching	5	6	Trunk, limbs	Cough, hyposmia, hypogeusia	No	Resolution
17	F	90	Cremona	March 12, 2020	March 20, 2020	Scattered papulovesicular lesions (predominance of vesicles)	No itching	1	6	Trunk	Fever, cough, dyspnea, coryza, headache, weakness	No	Active disease
18	F	69	Brescia	March 12, 2020	March 20, 2020	Scattered papulovesicular lesions (predominance of papules)	No itching	Unknown	NA	Trunk	Fever, cough, dyspnea, coryza, hyposmia, hypogeusia, headache, weakness	No	Active disease
19	M	65	Naples	March 13, 2020	March 20, 2020	Diffuse papulovesicular lesions (predominance of papules)	Mild itching	-2	9	Trunk	Fever, cough	No	Improvement
20	M	80	Brescia	March 14, 2020	March 22, 2020	Scattered papulovesicular lesions (predominance of vesicles)	No itching	Unknown	NA	Trunk, limbs	Fever, dyspnea	//	Death
21	M	43	Milan	March 15, 2020	March 23, 2020	Scattered papulovesicular lesions (predominance of vesicles)	Mild itching	0	11	Trunk	Fever, myalgia	No	Active disease
22	F	8	Milan	March 15, 2020	March 24, 2020	Scattered papulovesicular lesions (predominance of papules)	No itching	3	7	Trunk	Fever, cough	No	Resolution

F, Female; ID, identification; M, male; NA, not available; //, not applicable.

*Patient with acute respiratory distress symptoms in intensive care unit.

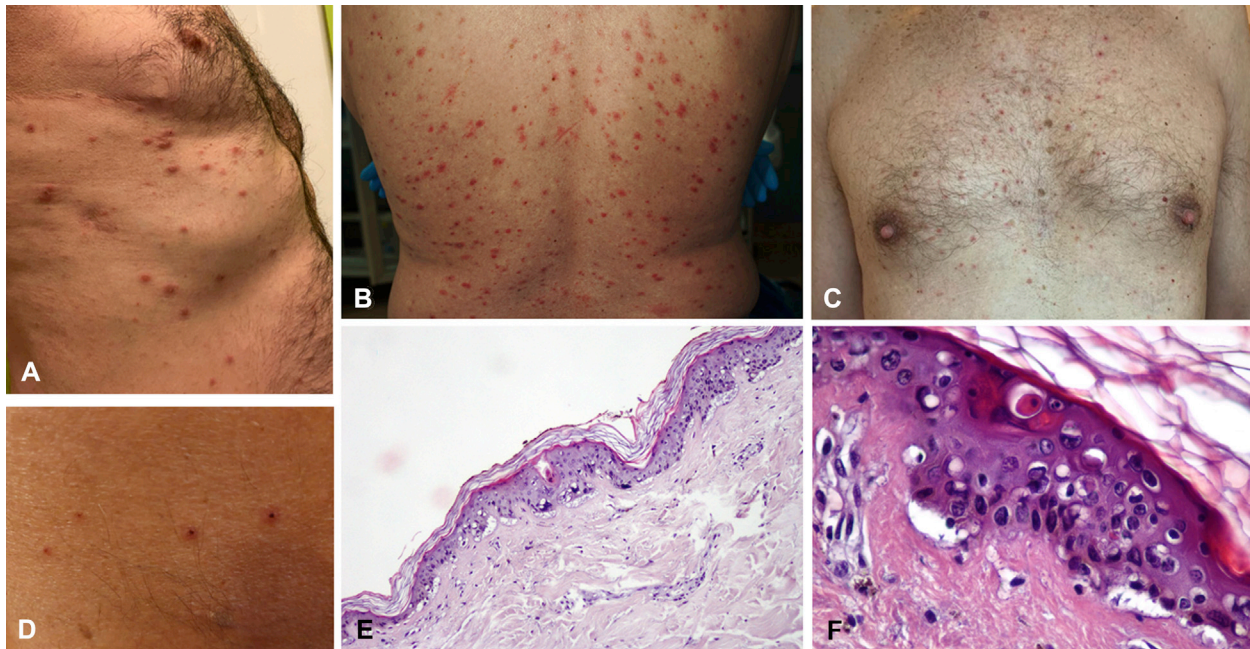


Fig 1. **A-D**, Papulovesicular exanthem on the trunk in 4 patients with COVID-19. **A-C**, In 3 patients, predominance of papules is seen. **D**, In another patient mainly presenting with vesicles, exanthem resolution with crusts is evident; **E**, Basket-wave hyperkeratosis; slightly atrophic epidermis; and vacuolar degeneration of the basal layer with multinucleate, hyperchromatic keratinocytes and dyskeratotic cells. Note the absence of inflammatory infiltrate. (Hematoxylin-eosin stain; original magnification: $\times 4$.) **F**, Close-up image with atrophic epidermis, vacuolar alteration with disorganized keratinocytes lacking orderly maturation, and enlarged and multinucleate keratinocytes with dyskeratotic (apoptotic) cells. (Hematoxylin-eosin stain; original magnification: $\times 20$).

During the Italian outbreak, we have observed a varicella-like papulovesicular exanthem as a rare but specific COVID-19-associated skin manifestation. Eight Italian dermatology units collected clinical data from patients with COVID-19 (microbiologically proven by nasopharyngeal swab) and no history of new medications in the previous 15 days who developed varicella-like lesions.

Demographic and clinical features of the 22 patients are summarized in [Table I](#). The median age was 60 years, and 72.7% of patients ($n = 16/22$) were male. Most patients ($n = 17/22$; 77.3%) came from Lombardy, currently the worst-hit region in Italy, and the remaining patients came from Piedmont ($n = 1$), Emilia-Romagna ($n = 1$), Toscana ($n = 1$), Lazio ($n = 1$), and Campania ($n = 1$). The median latency time from systemic symptoms to exanthem was 3 days (range, -2 to 12 days). The median duration of skin manifestations was 8 days (range, 4-15 days). Lesions were scattered in most patients ($n = 16$; 72.7%), and they were diffuse in 6 (27.3%) patients. Predominance of vesicles was observed in 12 (54.5%) patients. No variations in the papulovesicular presentation

were observed in our case series. The trunk was always involved, in some cases in association with the limbs ($n = 4$; 18.2%) ([Fig 1, A-D](#)). No facial or mucosal involvements were scored. Itching, which was generally mild, was reported in 9 (40.9%) patients. In all patients who underwent skin biopsy ($n = 7$), histologic findings were consistent with viral infection ([Fig 1, E and F](#)).

The most common systemic symptom was fever ($n = 21/22$; 95.5%), followed by cough ($n = 16$; 72.7%), headache ($n = 11$; 50%), weakness ($n = 11$; 50%), coryza ($n = 10$; 45.5%), dyspnea ($n = 9$; 40.9%), hyposmia ($n = 4$; 18.2%), hypogeusia ($n = 4$; 18.2%), pharyngodynia ($n = 1$; 4.5%), diarrhea ($n = 1$; 4.5%), and myalgia ($n = 1$; 4.5%). Death occurred in 3 (13.6%) patients.

Ours is the first series on this varicella-like exanthem as a specific COVID-19-associated cutaneous picture, unlike the nonspecific cutaneous manifestations such as erythematous rash or urticaria reported by Recalcati.⁵ Its typical features are frequent trunk involvement, usually scattered distribution, and mild/absent pruritus, the latter being in line with most viral exanthems but unlike true

varicella. Lesions generally appear 3 days after systemic symptoms and disappear by 8 days, without leaving scarring. A limitation of our study was missing histologic evaluation in some cases. Moreover, demonstration of SARS-CoV-2 presence by polymerase chain reaction in lesional skin was not possible because of specific primer unavailability. If further studies validate our findings, this early skin manifestation will represent a useful clue for suspecting COVID-19 in asymptomatic/paucisymptomatic patients.

The authors wish to thank the following collaborators for their help in data collection and patient treatment: Marica Annunziata, Cristiana Colonna, Massimo Ghislanzoni, Raffaele Gianotti, Chiara Moltrasio, Gianluca Nazario, Emanuela Passoni, Marina Picca, Gaetano Rizzitelli, and Diego Tosi.

Angelo Valerio Marzano, MD,^{a,b} Giovanni Genovese, MD,^{a,b} Gabriella Fabbrocini, MD,^c Paolo Pigatto, MD,^d Giuseppe Monfrecola, MD,^c Bianca Maria Piraccini, MD,^e Stefano Veraldi, MD,^{a,b} Pietro Rubegni, MD,^f Marco Cusini, MD,^a Valentina Caputo, MD,^g Franco Rongioletti, MD,^b Emilio Berti, MD,^{a,b} and Piergiacomo Calzavara-Pinton, MDⁱ

From the Dermatology Unit, Fondazione IRCCS Ca' Granda Ospedale Maggiore Policlinico, Milan, Italy^a; Department of Pathophysiology and Transplantation, Università degli Studi di Milano, Italy^b; Section of Dermatology, Department of Clinical Medicine and Surgery, University of Naples Federico II, Italy^c; Clinical Dermatology, IRCCS Istituto Ortopedico Galeazzi, Milan, Italy^d; Department of Dermatology, University of Bologna, Italy^e; Dermatology Unit, Department of Medical, Surgical and Neurosciences, University of Siena, Italy^f; Unit of Pathology, Grande Ospedale Metropolitano Niguarda, Milan, Italy^g; Unit of Dermatology, Department of Medical Sciences and Public Health, Cagliari, Italy^h; and Department of Dermatology, University of Brescia, Italy.ⁱ

Funding sources: None.

Conflicts of interest: None disclosed.

IRB approval status: Because of the retrospective nature of the study, only a notification to the ethical committee of the principal investigator center (Fondazione IRCCS Ca' Granda Ospedale Maggiore Policlinico, Milan, Italy) was requested. All patients gave written informed consent for publishing the clinical images.

Reprint requests: Angelo Valerio Marzano, MD, Dermatology Unit, Fondazione IRCCS Ca' Granda Ospedale Maggiore Policlinico, Via Pace, 9, 20122, Milano, Italia

E-mail: angelo.marzano@unimi.it

REFERENCES

1. Zhu N, Zhang D, Wang W, et al. China novel coronavirus investigating and research team. A novel coronavirus from patients with pneumonia in China, 2019. *N Engl J Med*. 2020; 382(8):727-733.
2. Livingston E, Bucher K. Coronavirus disease 2019 (COVID-19) in Italy [Epub ahead of print]. *JAMA*. 2020. <https://doi.org/10.1001/jama.2020.4344>.
3. Dipartimento della Protezione Civile. Comunicato stampa: Coronavirus: la situazione dei contagi in Italia, Available at: <http://www.protezionecivile.gov.it/media-comunicazione/comunicati-stampa/-/content-view/view/1265583>. Accessed April 27, 2020.
4. Joob B, Wiwanitkit V. COVID-19 can present with a rash and be mistaken for Dengue. *J Am Acad Dermatol*. 2020;82:e177.
5. Recalcati S. Cutaneous manifestations in COVID-19: a first perspective [Epub ahead of print]. *J Eur Acad Dermatol Venereol*. 2020. <https://doi.org/10.1111/jdv.16387>. Accessed April 27, 2020.

<https://doi.org/10.1016/j.jaad.2020.04.044>

Risk of hospitalization and death from COVID-19 infection in patients with chronic plaque psoriasis receiving a biologic treatment and renal transplant recipients in maintenance immunosuppressive treatment



To the Editor: There is uncertainty concerning the outcome of COVID-19 infection in patients receiving systemic therapies such as biologics and immunosuppressive drugs.¹ Whether biologics for psoriasis should be interrupted for preventing severe complications of COVID-19 infection is debated.^{2,3}

We performed a retrospective observational study to determine whether patients with chronic plaque psoriasis on biologic or other immunosuppressive therapy and patients who had received a renal transplant had a higher risk of hospitalization or death from COVID-19 infection compared with the general population of Verona during the observation period from February 20 to April 10, 2020. Inclusion criteria for patients with psoriasis and transplant were being regularly monitored at the Division of Dermatology and Nephrology of the Azienda Ospedaliera Universitaria Integrata Verona, respectively, being treated with a biologic or immunosuppressive medication, and being a resident in Verona. Data were obtained by consulting the electronic