

Prospective randomized comparison of laparoscopic versus open adrenalectomy for sporadic pheochromocytoma

Guido A. M. Tiberio · Gian Luca Baiocchi · Luca Arru · Claudia Agabiti Rosei ·
Simona De Ponti · Albert Matheis · Damiano Rizzoni · Stefano M. Giulini

Received: 21 November 2007 / Accepted: 4 March 2008 / Published online: 9 April 2008
© Springer Science+Business Media, LLC 2008

Abstract

Background Laparoscopic adrenalectomy for pheochromocytoma remains subject of debate, owing to the systemic consequences of pneumoperitoneum in patients with catecholamine-secreting tumors.

Methods A prospective randomized study was conducted (2000–2006), evaluating cardiovascular instability during open ($n = 9$, group A) or laparoscopic ($n = 13$, group B) adrenalectomy for pheochromocytoma. Haemodynamic parameters were recorded by invasive monitoring.

Results Haemodynamic instability was observed in 3/9 (group A) and 6/13 patients (group B), with a mean of 1.8 and 2.2 hypertensive peaks per patient ($p = \text{n.s.}$). Blood loss (164 ± 94 cc versus 48 ± 36 cc, $p < 0.05$) and operative time (180 ± 40 versus 158 ± 45 min, $p = \text{n.s.}$) favored laparoscopic procedures. Postoperative morbidity and mortality were nil. Hospital stay was shorter in group B ($p < 0.05$). Long-term follow-up was always normal.

Conclusions Laparoscopic approach for pheochromocytoma can be as safe as open surgery; intraoperative haemodynamic instability, although usually controlled with success, remains a source of concern.

Keywords Pheochromocytoma · Adrenalectomy · Laparoscopy · Open surgery

Laparoscopic adrenalectomy is the current gold standard for the surgical management of a broad spectrum of adrenal diseases [11, 18]. During laparoscopic surgery for pheochromocytoma, intraoperative haemodynamic instability remains a major concern and, even in experienced hands, the procedure may be associated with longer operative time, increased complication rates, and prolonged hospitalization, despite appropriate preoperative medical treatments, minimal invasiveness, and reduced manipulation of tumor. Since the first report by Gagner [4], some studies investigated the endocrine and cardiovascular effects of laparoscopic surgery for pheochromocytoma and demonstrated the safety and feasibility of laparoscopy [1, 3, 6, 9, 10, 13–15, 19], belying the theoretical concerns about the effects of carbon dioxide pneumoperitoneum on the haemodynamics of patients with catecholamine-secreting tumors [7, 17]. Considering that in these series the laparoscopic group of patients was compared to an historical one, we performed a prospective randomized comparison between laparoscopic and open surgery in patients affected by sporadic pheochromocytoma, in order to effectively compare the intraoperative haemodynamic consequences of the two surgical techniques, avoiding the bias linked to the evolution of medical and anaesthesiological protocols.

G. A. M. Tiberio · G. L. Baiocchi · L. Arru · S. De Ponti ·
S. M. Giulini
Surgical Clinic, Department of Medical and Surgical Sciences,
University of Brescia, 25100 Brescia, Italy

G. A. M. Tiberio
Campus Bio-Medico University, Rome, Italy

G. A. M. Tiberio (✉)
P.tta San Giorgio, 5, 25100 Brescia, Italy
e-mail: guido.tiberio@libero.it

C. Agabiti Rosei · D. Rizzoni
Internal Medicine, Department of Medical and Surgical
Sciences, University of Brescia, Brescia, Italy

A. Matheis
Department of Anaesthesia and Resuscitation, University of
Brescia, Brescia, Italy

Patients and methods

Between January 2000 and December 2006, all patients bearing sporadic pheochromocytoma were offered to enter in a prospective randomized comparison between open and laparoscopic surgery. Patients presenting a bilateral or recurrent disease or a preoperative suspicion of malignant pheochromocytoma were not considered. Previous abdominal surgery was not considered a contraindication for laparoscopic surgery. The patients received full information concerning the effects of CO₂ pneumoperitoneum, the data from the literature, and the results of our own series of patients submitted to laparoscopic and open adrenalectomy for pheochromocytoma. All patients were operated by the most experienced surgeon, respectively, in open and laparoscopic surgery. The proposed trial was accepted by all but one Jehovah's Witness, who asked for an open approach. Twenty-two patients, 14 males and 8 females, ranging in age from 27 to 66 years, were randomized between open (group A, 9 patients) and laparoscopic (group B, 13 patients) surgery. We used a simple randomization: each patient had equal possibilities to receive each of the treatments. The clinical presentation was typical in all but one dopamine-producing case, sustained hypertension and transitory hypertensive crises controlled by medical therapy being the most frequent symptom. The diagnosis was based upon biochemical evidence of increased catecholamines and cromogranin A release, computed tomography (CT) and/or magnetic resonance (MR) imaging and metaiodobenzylguanidine (MIBG) scintigraphy.

In all cases the preoperative pharmacological preparation started at least 10 days before surgery and obtained the standards indicated by Kebebew and Duh [8]. The medical treatment was selected considering the type of catecholamine secretion [16]; it included alpha- (doxazosine) and beta-blockers (atenolol), alone or in association, and calcium-channel blockers if needed. During the surgical procedure labetalol was infused in all cases, while hypertensive crisis was managed by sodium nitroprusside.

Laparotomic surgery was conducted through a subcostal incision while laparoscopy was performed through a lateral decubitus transperitoneal approach as described [5, 12], maintaining the intra-abdominal pressure between 8 and 10 mmHg. Once an adequate exposition of the surgical field was obtained, the first technical step was in both groups represented by the ligation of the main adrenal vein using a no-touch technique on the adrenal gland; a gentle dissection with coagulation or suture of blood vessels completed the procedure.

Haemodynamic data were collected from the anaesthesiology records. The variables were considered at the following time points: basal preoperative condition,

induction of general anaesthesia, pneumoperitoneum insufflation, initial dissection, adrenal vein ligation, gland dissection, and extubation. The arterial pressure was monitored by means of a radial artery line in all the cases. To evaluate intraoperative cardiovascular instability, an increase in systolic pressure of more than 25% was considered hypertensive peak, a heart rate of more than 100 per minute was defined as a tachycardic episode while a systolic blood pressure < 80 mmHg defined an hypotensive crises. Estimated blood loss and need for blood transfusions were also considered.

All patients received a similar follow-up schedule with clinical and biochemical evaluations 30 days and 6 months after surgery, to be repeated 18 months after surgery, along with a CT or MIBG scan. During follow-up consultations the haemodynamic variables, the need of anti-hypertensive treatment, catecholamines, and cromogranine A secretion and the imaging evidence of recurrent disease were recorded.

Data are expressed as mean \pm standard deviation (SD); statistical analysis was performed the by nonparametric Mann–Whitney test for quantitative data and by Fisher's exact test for qualitative data; $p < 0.05$ was rated as significant.

The sample size of about ten patients in each treatment group allows to demonstrate an effect size of about 1.3 (1.3 times the variability of the phenomenon under investigation such as blood loss, operative time, and haemodynamic variables) by means of a Mann–Whitney test at a significance level of 0.05 with a power of about 0.80.

Results

The epidemiological, clinical, biochemical, and pathological variables were comparable in the two groups of patients, as shown in Table 1.

Table 1 Epidemiological, clinical, and pathological variables in the studied population

	Group A	Group B	
Number of patients	9	13	n.s.
Gender M/F	7/2	7/6	n.s.
Mean age, years	51 (34–61)	51 (37–74)	n.s.
Hormonal secretion:			
Norepinephrine	6	8	n.s.
Epinephrine	1	1	n.s.
Norepinephr.+ epinephr.	2	3	n.s.
Dopamine		1	n.s.
Mean tumor Ø, mm	41 (25–60)	40 (22–60)	n.s.
Tumor location (right/left)	5/4	8/5	n.s.

Hypertensive peaks were observed in 3/9 and 6/13 patients in group A and B, respectively ($p = 0.674$), with a mean of 1.8 and 2.2 peaks per patient in the different groups (Table 2); in all cases the increases of the mean arterial pressure were corrected by adjustments of the infusion rate of labetalol and sodium nitroprusside. The intraoperative haemodynamic course of the patients developing haemodynamic instability is depicted in Fig. 1. Arterial blood pressure and heart rate were stable during anaesthesia induction, instauration of CO₂ pneumoperitoneum and initial dissection; during adrenergic crises the arterial pressure reached higher levels in group B ($240 \pm 82/115 \pm 67$ mmHg) than in group A ($188 \pm 58/100 \pm 49$ mmHg); this difference was not significant ($p = 0.12$) and was mainly ascribed to one patient who had multiple intraoperative hypertensive crises, the most important measured at 320/180 mmHg. After the ligation of the main adrenal vein, the haemodynamic course was regular in group A, while in group B the above mentioned patient still had crises before the complete dissection of the gland. In group B, two patients developed a postoperative hypotension, which was corrected by intravenous volume loading.

The mean operative time was 180 ± 40 min and 158 ± 45 min for open and laparoscopic procedures, respectively (n.s.). No patient required blood transfusions but blood loss was higher in group A (164 ± 94 cc) than group B (48 ± 36 cc) ($p < 0.05$).

The pathologist, besides confirming the diagnosis, signaled the effraction of four tumors, two in each group.

All the patients had an uneventful postoperative course and the mean hospital stay was 8 and 5 days in group A and B, respectively ($p < 0.05$). At the first postoperative control all patients showed normal haemodynamics and biochemistry; anti-hypertensive treatments were interrupted in all but 2 group B patients, in whom the number and dosage of drugs were however reduced; these findings were confirmed at the second postoperative control. At the 18th month follow-up we always observed normal biochemistry and imaging, but 2 more patients (1 in each group) needed anti-hypertensive treatment for primary

Table 2 Haemodynamic and surgical variables in the studied population

	Group A	Group B	
Pts with hypertensive peaks	3/9	6/13	n.s.
Hypertensive peaks/pts	1.8	2.2	n.s.
Blood loss, cc	164 ± 94	48 ± 36	<0.05
Mean operative time, min (range)	180 (120–230)	158 (70–270)	n.s.
Mean hospital stay, days	8	5	<0.05

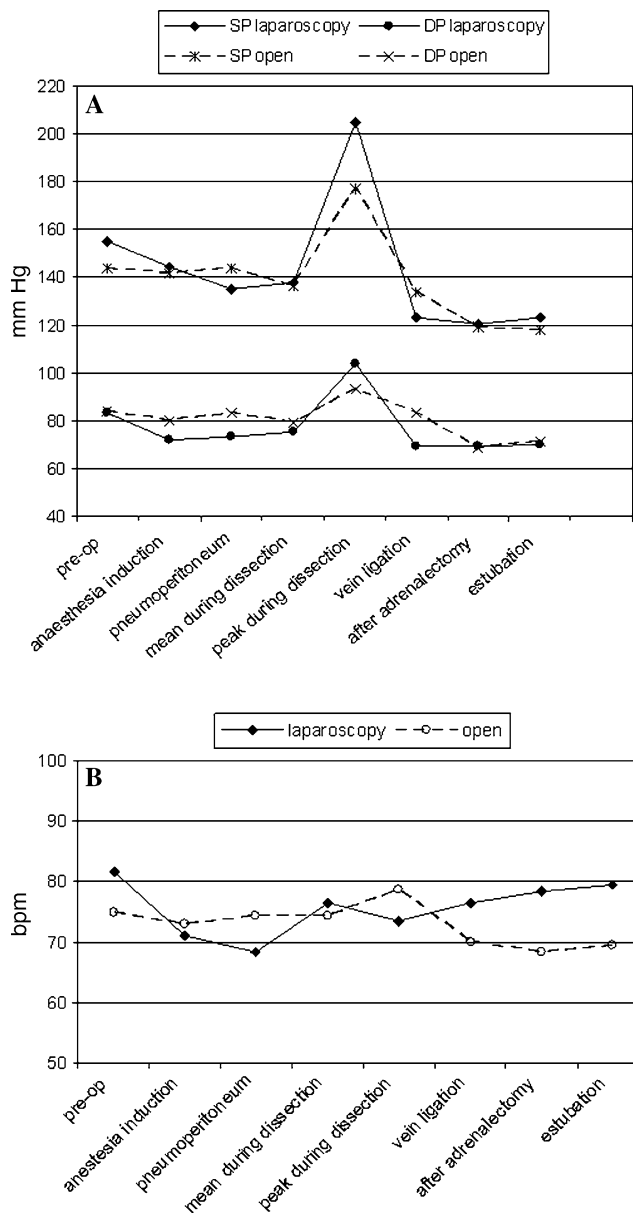


Fig. 1 Systolic (SP) and diastolic (DP) blood pressure (A) and heart rate (B) during open and laparoscopic adrenalectomy in patients showing cardiovascular instability

hypertension. The patients in whom a tumor effraction was detected showed a normal MIBG scan 3 years after surgery.

Discussion

The pathophysiological consequences of CO₂ pneumoperitoneum may aggravate the challenging haemodynamic instability of pheochromocytoma. Several studies demonstrated reduction of cardiac venous inflow, increase of vascular resistances, decreased cardiac index with elevated

myocardial O₂ consumption, and increased mean arterial pressure after instauration of pneumoperitoneum [7]; furthermore, increased carboxyemia due to gas diffusion through the tissues may be related to hypercapnia, increased ventilation, and respiratory acidosis [17]: these conditions may facilitate the impairment of cardiac function in these critical patients.

In the past few years some series were published focusing on the difference in endocrinal and cardiovascular changes during laparoscopic and open adrenalectomy for pheochromocytoma. Some studies retrospectively compared groups of well-matched patients approached with these different modalities, concluding in favor of the laparoscopic approach [1, 3, 6, 9, 10, 13–15, 19]. In fact, if Inabnet et al. signaled the hypertensive crises to be more severe or to occur more frequently in the laparoscopic group, Fernandez Cruz and collaborators demonstrated a reduced increase of plasma catecholamine levels with significant benefit in terms of drug control of hypertensive peaks during laparoscopic surgery; this was ascribed to the less traumatic laparoscopic dissection, causing a reduced increment of catecholamines, as measured by intraoperative multiple blood collections. It remains unclear if the better results obtained with the laparoscopic approach should be ascribed to a good surgical technique — well depicted by the principle of *dissecting the patient from the gland* — or to the helium pneumoperitoneum employed by the authors, which could have eliminated the negative effects of CO₂ insufflation.

Beside the use of unconventional gases, the gasless laparoscopy has also been proposed for this particular application [2]; these technical changes, however, do not encounter large diffusion in the surgical community.

The aim of the present study was to enter the debate producing some data obtained through a controlled clinical study on different surgical techniques in a homogeneous clinical setting, in order to exclude biases that might influence the haemodynamic parameters during the operation. Particular attention was paid to the pre- and intraoperative management: all the patients received the same preoperative treatment and anaesthesiological assistance, managed by the same medical staff through protocols that did not change during the study period. The preoperative assessment excluded in all cases cardiac impairment and showed effective control of haemodynamic status, confirming the efficacy of preoperative medical preparation. Furthermore, each group of patients was managed by the most experienced surgeon in the corresponding technique.

Considering the small number of patients enrolled in this study owing to the low prevalence of the investigated pathology, our results cannot be considered as conclusive. However, we are confident in supporting that the

laparoscopic approach is safe also in these challenging cases and that open surgery does not offer any amelioration of the perioperative haemodynamic course. In fact, incidence of adrenergic crises was similar in the two experimental groups, confirming that the minimally invasive technique, although performed with the foremost attention, does not protect the patient from intraoperative adrenergic crises.

During our first laparoscopic procedures on the adrenal gland we observed that an amelioration of anaesthesiological course was obtained by reducing the abdominal pressure from the standard 14 mmHg we use in general surgery to the 8–10 mmHg value we used also in this study. At this pressure regimen, the anaesthesiologist reports an amelioration of the pulmonary compliance and, probably, a reduction of the undesired side effects of CO₂ insufflation.

According to the literature, the laparoscopic approach proved to be superior to open surgery when other operative variables were considered. It reduced intraoperative blood loss and also shortened operative time. This latter difference increased progressively with the experience in the treatment of these particular cases, reaching a minimum operative time of 70 min. As far as the postoperative course is considered, our work confirms the previously reported advantages of the laparoscopic approach.

At a mean follow-up of 35 months (range 18–84 months) no patient had clinical, biochemical or instrumental signs of recurrence, including those in whom a tumor effraction was demonstrated by the pathologist.

In conclusion, our work demonstrates that the laparoscopic approach to pheochromocytoma does not increase the surgical risk correlated to the haemodynamic instability; however, our data do not confirm previously reported data of better intraoperative haemodynamic performances in patients submitted to laparoscopic removal of the adrenal gland.

Acknowledgements The authors are very grateful to Prof. Bruno Mario Cesana of the Department of Biomedical Sciences and Biotechnology, Section of Medical Statistic, Brescia University for his valuable help in reviewing the statistical analysis of the paper.

References

1. Fernandez-Cruz L, Taura P, Saenz A et al (1996) Laparoscopic approach to pheochromocytoma: hemodynamic changes and catecholamine secretion. *World J Surg* 20:762–768
2. Fernandez-Cruz L, Saenz A, Taura P et al (1998) Helium and carbon dioxide pneumoperitoneum in patients with pheochromocytoma undergoing laparoscopic adrenalectomy. *World J Surg* 22:1250–1255
3. Flavio Rocha M, Faramarzi-Roques R, Tauzin-Fin P et al (2004) Laparoscopic surgery for pheochromocytoma. *Eur Urol* 45:226–232

4. Gagner M, Lacroix A, Bolte E (1992) Laparoscopic adrenalectomy in Cushing's syndrome and pheochromocytoma. *NEJM* 327:1033
5. Gagner M (1996) Laparoscopic adrenalectomy. *Surg Clin North Am* 76:523–537
6. Hazzan D, Shiloni E, Golijanin D, Jurim O, Gross D, Reissman P (2001) Laparoscopic adrenalectomy for benign adrenal neoplasm. A comparative study. *Surg Endosc* 15:1356–1358
7. Inabnet WB, Pitre J, Bernard D et al (2000) Comparison of the hemodynamic parameters of open and laparoscopic adrenalectomy for pheochromocytoma. *World J Surg* 24:574–578
8. Kebebew E, Duh QJ (1998) Benign and malignant pheochromocytoma. Diagnosis, treatment and follow-up. *Surg Oncol Clin North Am* 7:765–789
9. Kercher KW, Park A, Matthews BD et al (2002) Laparoscopic adrenalectomy for pheochromocytoma. *Surg Endosc* 16:100–102
10. Kercher KW, Novitsky YW, Park A, Matthews BD, Litwin DE, Heniford BT (2005) Laparoscopic curative resection of pheochromocytomas. *Ann Surg* 241:919–926
11. Lezoche E, Guerrieri M, Crosta F, Paganini A, D'Ambrosio G, Lezoche G, Campagnacci R (2008) Perioperative results of 214 laparoscopic adrenalectomies by anterior transperitoneal approach. *Surg Endosc* 22:522–526
12. Marescaux J, Mutter D, Wheeler MH (1996) Laparoscopic right and left adrenalectomies: surgical procedures. *Surg Endosc* 10:912–915
13. Miccoli P, Bendinelli C, Materazzi G, Iacconi P, Buccianti P (1997) Traditional versus laparoscopic surgery in the treatment of pheochromocytoma: a preliminary study. *J Laparoendosc Surg* 3:167–171
14. Mobius E, Nies C, Rothmund M (1999) Surgical treatment of pheochromocytomas: laparoscopic or conventional? *Surg Endosc* 13:35–39
15. Prinz RA (1995) A comparison of laparoscopic and open adrenalectomies. *Arch Surg* 130:489–492
16. Proye C, Thevenin D, Cecat P, Petillot P, Carnaille B, Wemeau JL, Huglo D, Ernst O, Proye CA (1989). Exclusive use of calcium channels blockers in preoperative and intra-operative control of pheochromocytomas: hemodynamics and free catecholamines assays in ten consecutive patients. *Surgery* 106:1149–1154
17. Sprung J, O'Hara JF, Gill IS, Abdelmalak B, Sarnaik A, Bravo EL (2000) Anesthetic aspects of laparoscopic and open adrenalectomy for pheochromocytoma. *Urology* 55:339–343
18. Tiberio GA, Piardi T, Cerea K, Ronconi M, Bertoloni G, Frassi E, Portolani N, Giulini SM (2005) Laparoscopic adrenalectomy: an initial experience. *Chir Ital* 57:273–278
19. Toniato A, Boschini I, Bernante P, Opocher G, Guolo AM, Pelizzo MR, Mantero F (2007) Laparoscopic adrenalectomy for pheochromocytoma: is it really more difficult? *Surg Endosc* 21:1323–1326